

ERRATUM

Şentürk A, Kılıç H, Hezer H, Karaduman Yalınç F, Hasanoğlu FC. Endobronchial ultrasound-guided transbronchial needle biopsy for the diagnosis of mediastinal lymphadenopathy in patients with extrathoracic malignancies. *Turk J Med Sci* (2014) 44(6): 989–995.

On p. 990, in the Materials and methods section, Figure 2 was incorrectly inserted twice. The correct Figure 1 appears below. In addition, the caption for Figure 3 was incorrect. The correct caption appears below. These errors only appear in the printed version of the article. The online version has already been corrected.

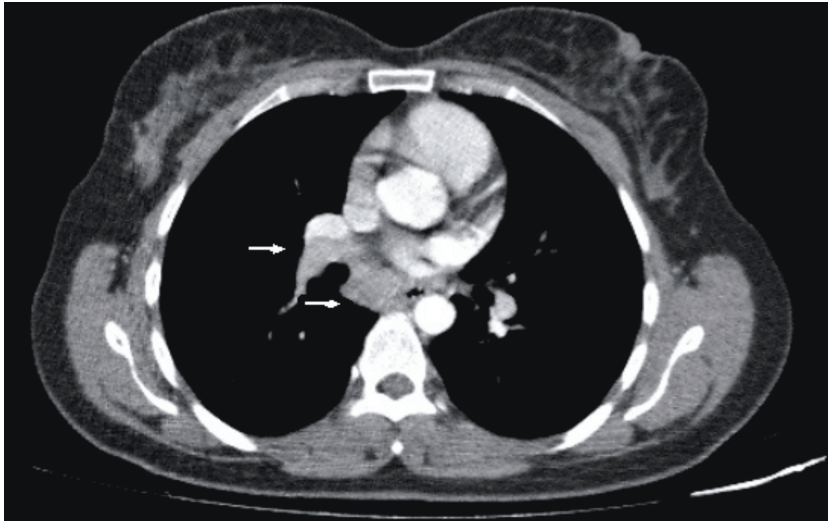


Figure 1. Thorax CT showing right hilar (11R) and subcarinal (7) lymph node of the patient, performed by EBUS-TBNA.

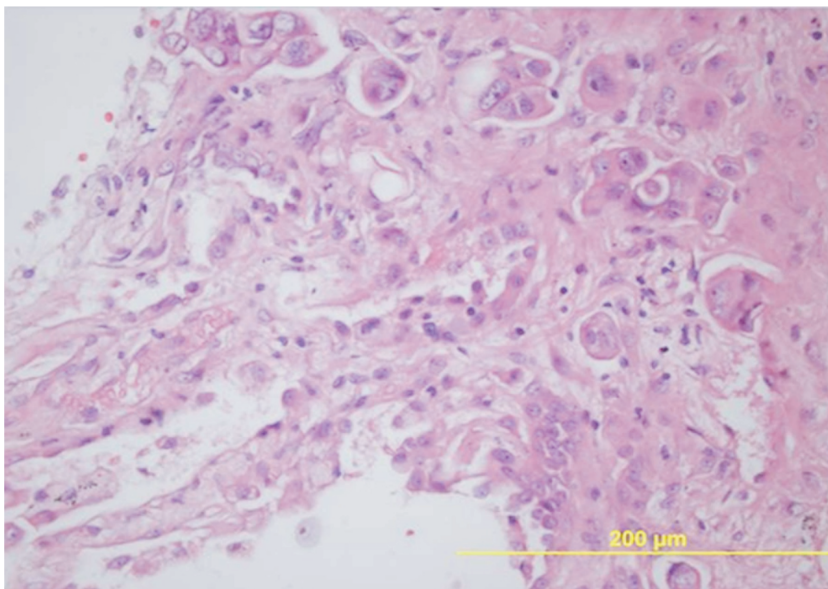


Figure 3. Histopathological section of cell-block obtained by EBUS-TBNA demonstrating breast cancer.