

Aysun YILMAZLAR  
Berin ÖZCAN  
Nuray KAPLAN  
Oya KUTLAY

## Adult Respiratory Distress Syndrome Caused by Psittacosis

Department of Anaesthesiology, Intensive Care  
Faculty of Medicine, Uludağ University, Bursa-  
Turkey

Received: September 14, 1999

Psittacosis is an avian infection caused by *C. psittaci*. Humans become infected through exposure to discharges of infected avian species. The human infection may be either a respiratory or a systemic disease (1). Psittacosis is an uncommon illness, but it is an important occupational hazard (2).

This case report concerns a 48-year-old man with recent psittacosis pneumonia complicated by adult respiratory distress syndrome.

### Case Report

Three weeks prior to admission, a 48-year-old previously healthy man complained of headaches, fever and dyspnea. There was a history of direct exposure to two sick parrots.

His family physician prescribed betalactam drugs for a suspected upper respiratory tract infection. He was referred to the Department of Pulmonary Diseases of our hospital because of acute respiratory insufficiency. Their treatment consisted of cefaperazone-sulbactam, flucanazole and ornidazole. But the lung abnormalities progressed. So the patient was transferred to Intensive Care because of the necessity for mechanical ventilation. On examination we saw a temperature 40°C, and rales on auscultation of the lungs. The chest x-ray revealed bilateral infiltrates in all lobes (Figure 1). The arterial blood gases were: PH: 7.21, PCO<sub>2</sub>: 40, PO<sub>2</sub>:46, BE: -11.5, HCO<sub>3</sub>: 15.9, SaO<sub>2</sub>: 67%. 8cmH<sub>2</sub>O PEEP was applied with controlled mechanical ventilation. Lung injury score was "10" (CHEST X-RAY: No infiltrate: 0, one quadrant: 1, two quadrant: 2, three quadrant: 3, four quadrant: 4. HYPOXEMIA: PaO<sub>2</sub>/FIO<sub>2</sub>: >300: 0, 225-

229: 1, 175-224: 2, 100-174: 3, <100: 4, PEEP: <5: 0, 6-8: 1, 9-11: 2, 12-14: 3, >15: 4. COMPLIANCE: >80: 0, 60-79: 1, 40-59: 2, 20-39: 3, <19: 4. The lung injury score is obtained by the number of components used; ARDS is defined as LIS>2.5) (3).

Sputum, blood and urine cultures were sterile.

Hepatic, renal and haematologic profiles were normal. Direct complement fixation tests were 1/2 positive, 1/80 positive in the active period of disease, 1/320 positive in the recovery period of disease. The patient received a 10-day course erythromycin (2 g/day)-tetracycline (2 g/day) medication for psittacosis and mechanical ventilation for respiratory insufficiency. Within five days all laboratory and radiological findings were normal (Figure 2). Ten days later the patient was discharged.

### Discussion

Approximately 300 chlamydial infections are reported every year at the Cambridge Public Health Laboratory, England(4). Psittacosis pneumonia can be associated with a spectrum of complications: respiratory (5,6), renal (7), hepatic (5), haematologic (8,9) and neurological (10) manifestations. We found two cases of Psittacosis pneumonia that required mechanical ventilation in the literature (3,4). An unusual feature of our patient with psittacosis was respiratory insufficiency as the presenting symptom.

Although *C. psittaci* is sensitive to tetracycline and to a lesser degree to chlaramphenicol and erythromycin. It has been difficult to measure the true efficacy of antibiotic therapy. This patient presented with the clinical signs of primary atypical pneumonia, caused by

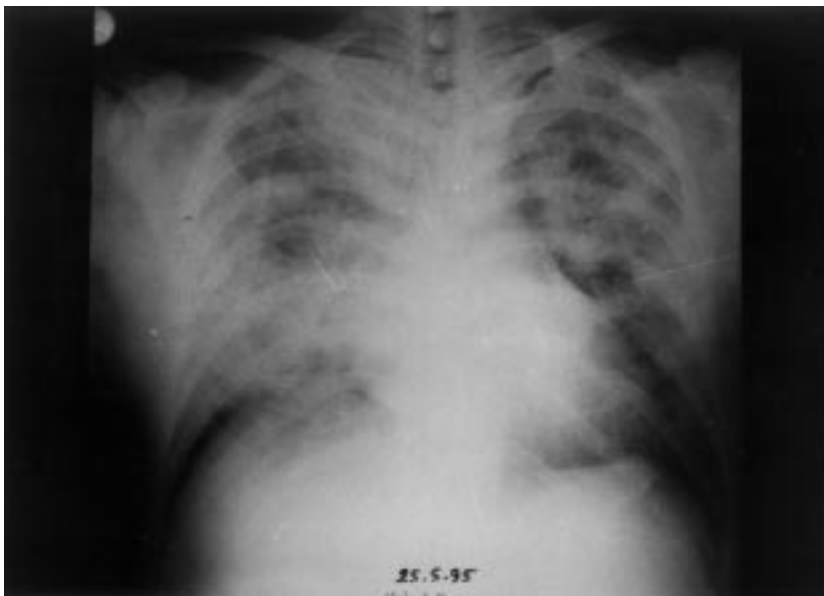


Fig. 1. Bilateral infiltrates in the chest x-ray.

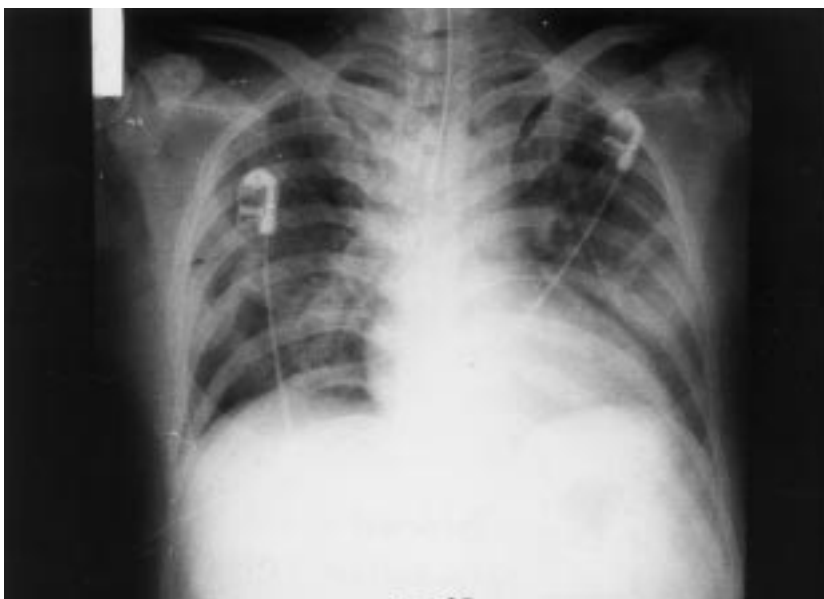

Fig. 2. Radiological findings were normal at the end of therapy.

psittacosis and the well documented phenomenon of adult respiratory distress syndrome. The infection responded well to erythromycin and tetracycline, which are also effective against psittacosis.

### Conclusion

Psittacosis should always be borne in mind as a possible cause of severe pneumonia with adult respiratory

distress syndrome. It is an important conclusion that erythromycin-tetracycline medication and respiratory support therapy seem to cure psittacosis pneumonia.

*Correspondence author:*

*Aysun YILMAZLAR*

*Department of Anaesthesiology,*

*Uludağ University School of Medicine*

*Görükle 16059, Bursa*

## References

1. Grayston, JM: Chlamydia pneumoniae. Strain TWAR (review). Chest, 95 (3). 665-9. 1989.
2. Berkel MV, Dik H, Dermeer JWM and Versteeg J: Acute respiratory
3. Rippe JM, Irwin RS, Alpert JS and Fink MP: Intensive Care Medicine, in Rinaldo JE, ed: Adult Respiratory Distress Syndrome, Boston, Toronto, London: Little, Brown and Comp, 1991: 476-481.
4. Wreghitt T: Chlamydial infection of the respiratory tract. Commun Dis Rep, 3(9): R1 19-24, 1993.
5. Kirchner JT, Bayarsky SA: Chlamydia psittaci. An uncommon cause of community acquired pneumonia. Arch Fam Med, 2(9): 997-1001, 1993.
6. Viciano P, Bonada JM, Martin-Sanz V, Martinez Marcos F, Martin A, Pachon J: Psittacosis of avian origin as etiology of community-acquired pneumonia with a severe onset. Rev Clin Esp, 192(1): 28-30, 1993.
7. Mason AB, Jenkins P: Acute renal failure in fulminant psittacosis. Respir Med, 88(3): 239-240, 1994.
8. Dayc J, Fawcett IW: Psittacosis and acute thrombocytopenic purpura. J R Soc Med, 85(6): 360-1, 1992.
9. Timmerman R, Bießer R: ) Haemolytic anaemia due to cold agglutinins caused by psittacosis. Netherlands Journal of Medicine, 34, 306-9, 1989.
10. Prevett M, Harding AE: Intracranial hypertension following psittacosis. J Neurol Neursurg Psychiatry, 56(4): 425-6, 1993.