

Mehmet Dumlu AYDIN<sup>1</sup>  
Nazan AYDIN<sup>2</sup>

## A Cerebral Hydatid Cyst Case First Presenting with Gerstmann's Syndrome: A Case Report and Literature Review

Departments of Neurosurgery<sup>1</sup> and Psychiatry<sup>2</sup>, Faculty of Medicine, Atatürk University, Erzurum - Turkey

Received: October 01, 2002

**Key Words:** Hydatid cyst, Angular gyrus, Gerstmann's syndrome

Gerstmann's syndrome in patients with hydatid cyst has not been reported frequently, although many cerebral hydatid diseases have been detailed. Tsukamoto et al. (1) reported such a case in a patient who had a cysticercosis in his left angular gyrus. MRI showed a focal lesion situated subcortically in the left angular gyrus and reaching the superior posterior parietal lobe in a patient with Gerstmann's syndrome. Four symptoms of Gerstmann's syndrome are seen in left angular gyrus lesions in right-handed persons (2). Brain involvement is seen in 1 to 2% of all echinococcus granulosus infestations and the primary form is very rare (3,4). The diagnosis is established with serologic and imaging techniques (3). A round, cystic lesion is detected on the CT in cerebral hydatid disease (5-7). Cerebral hydatid cysts should be removed without rupture (4). However, only half of these cysts are removed unruptured (8). For this reason, all patients have to receive mebendazole therapy (3). Cases with a hydatid cyst first representing Gerstmann's syndrome have rarely been reported. We are reporting this case due to its rarity.

### CASE REPORT

A 7-year-old boy was admitted to the psychiatry department with a history of headache, behavioral disturbances, mental regression, inability to perform skilful movement, counting and calculation disorders, and unawareness of his right side. Cranial computerized

tomography revealed a large round cystic mass in his left cerebral hemisphere, and he was then admitted to the neurosurgical unit. On examination he was fully conscious, but showed typical indications of Gerstmann's syndrome plus right hemiparesia, right hemihypoesthesia and right homonymous hemihypoplasia. He neglected his right side. Further investigation was required and a large round cystic mass (7 x 8 cm) in the left temporoparietal lobe was observed in his cranial MRI (Fig. 1). Other cystic masses were not found in systemic radiologic observations and serological tests related to hydatid disease were positive. Primary hydatid cyst of the brain was diagnosed preoperatively.

A large left temporoparietal craniotomy was performed. After dural opening, a sulcal dissection was made and the cyst was exposed by uncapping the overlying brain cortex. The cortex was opened and the cyst was encountered just under the brain cortex. Saline was injected into the cyst-brain interface, the cyst was delivered intact (Fig. 2) and the cavity washed continuously with saline solution. Pathological examination revealed a hydatid cyst. After the operation, transient left-sided hemiparesia was observed for 1 week. Therefore, we had to give him mebendazole (50 [mg/kg]/day) for 3 months. His symptoms disappeared within 4 months. A check-up MRI performed 1 year later revealed that the cavity of the cyst had disappeared. Minimal infarction was observed in the left temporoparietal area (Fig. 3).

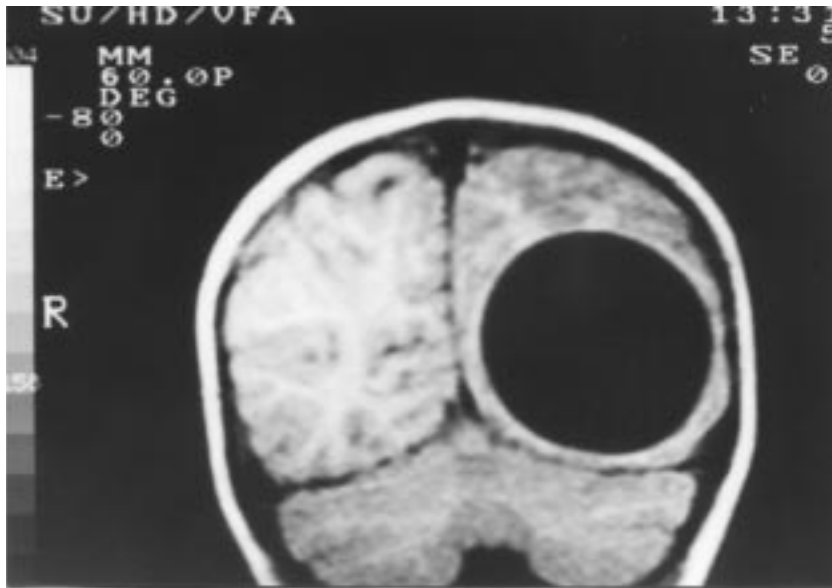


Figure 1. T1-weighted coronary cranial MRI reveals a giant round hypointense cystic lesion localised in the left angular area, 7 x 8 cm in diameter.




Figure 2. The removed cyst is seen after the operation (7 x 8 cm).

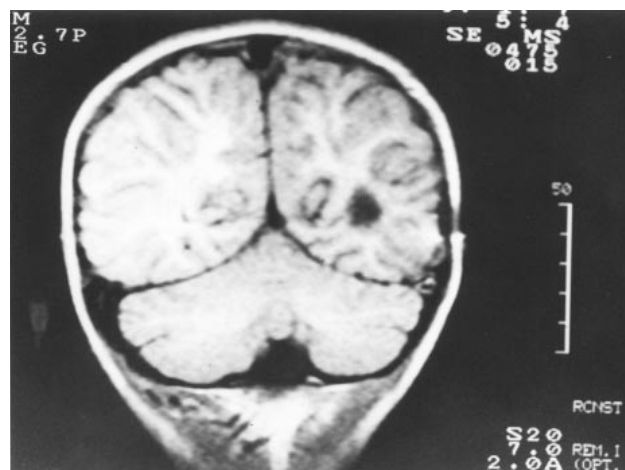


Figure 3. T1-weighted coronary cranial MRI taken 1 year after the operation. Cerebral tissue filled the cyst cavity and brain appearance is normal.

Gerstmann's syndrome was seen in a patient with various focal lesions situated subcortically in the left angular gyrus. Functional MRI studies showed that any lesion localized to the left superior parietal lobe and the dorsal aspects of the inferior parietal cortex causes Gerstmann's syndrome (9). Four symptoms of Gerstmann's syndrome, such as finger agnosia, agraphia, right-left disorientation and dyscalculia, are the major findings in dominant angular gyrus lesions (2). It was reported that a left subcortical network contributes to the storage and retrieval of rote verbal arithmetic facts,

while a bilateral inferior parietal network is dedicated to the mental manipulation of numerical quantities (10). Although Gerstmann's syndrome has been well documented since it was characterized in the latter half of the 20th century, there has been little literature on it in the last few years (11). It is expected that Gerstmann's syndrome should be more frequently seen than patients reported with echinococcal disease. However, not all hydatid diseases cause this syndrome even if they localize in angular region. Tsukamoto et al. (1) reported a case in a patient with Gerstmann's syndrome who had a

cysticercosis in the left angular gyrus. Gerstmann's syndrome occurs in many diseases affecting the left angular gyrus such as parietal ischemic stroke (12), thalamic hematoma (13), metastasis to angular gyrus (14), herpes encephalitis (15), multiple sclerosis (16), pachymeningitis (17), chronic subdural hematoma (18), traumatic damage of the angular gyrus (19), infectious diseases (20), and Creutzfeldt-Jakob disease (21). MRI shows a focal lesion, situated subcortically in the inferior part of the left angular gyrus and reaching the superior posterior region or left parietal region in patients with Gerstmann's syndrome (2,22). We think that Gerstmann's syndrome has not been studied adequately in cerebral hydatid disease.

A long surgical incision on the cerebral cortex may be required for the cyst's delivery without rupture. In our case, despite a significant compression of the angular gyrus and a large (7 cm) surgical incision of the brain cortex, the patient's symptoms disappeared four months after the operation. It is well known that the mass of hydatid cysts do not affect brain functions nor cause cerebral herniation (6,8) because the compressive effect of hydatid cysts gradually develops and the cerebral tissues are pushed laterally without damage. Eventually, no cerebral tissues may be present over the the cystic mass, as happened in our case. For this reason, a cortical incision was made at the thinnest region of the cerebral cortex and no complications were observed related to the cortical incision procedure.

Echinococcus granulosus infestation of the central nervous system may be primary or secondary and has been estimated to be very low (2%). The cysts are almost always found in the cerebral hemisphere. They favor the

region supplied by the middle cerebral artery, especially the parietal lobe (23,24). Most cerebral hydatid cysts are associated with hepatic cysts (25). There was only one cerebral cyst in our patient. Sharply demarcated, spherical and intraparenchymal cysts may reach a large size causing neurological symptoms. Hydatid cysts of the brain usually occur alone and may reach a diameter of several centimeters (7). It is generally accepted that patients with this disease rarely exhibit focal neurological deficit unless herniation occurs (26). There was a case in the literature where the large size of a cyst (7.1 cm) significantly raised intracranial pressure (ICP) leading to headache (27). The slow compression of the surrounding tissue without invasion may explain why some space-occupying lesions are tolerated for long periods. Fortunately, our patient had no symptoms of ICP but revealed only Gerstmann's syndrome, despite the large size of his cyst.

Although mebendazole is effective in hydatid disease (4), hydatid cysts should be removed without rupture and patients should receive mebendazole pre- and postoperatively for 1 to 8 weeks (3,8). In our case, the cyst was removed unruptured and the patient was treated with mebendazole (50 [mg/kg]/day) postoperatively for 3 months. Luckily, without any complication, the cyst was successfully removed from our patient.

**Correspondence author:**

*Nazan AYDIN*

*Department of Psychiatry,*

*Faculty of Medicine Atatürk University,*

*Erzurum - TURKEY*

**References**

1. Tsukamoto Y, Muraoka I, Yoshimasu N, et al. A case of brain cysticercosis. *No Shinkei Geka* 4: 811-815, 1976.
2. Mayer E, Martory MD, Pegna AJ, et al. A pure case of Gerstmann's syndrome with a subangular lesion. *Brain* 122: 1107-20, 1999.
3. al-Bassam A, Hassab H, al-Olayet Y, et al. Hydatid disease of the liver in children. *Ann Trop Paediatr* 19: 191-196, 1999.
4. Ersahin Y, Mutluer S, Guzelbag E. Intracranial hydatid cysts in children. *Neurosurgery* 33: 219-224, 1993.
5. Baysefer A, Erdogan E, Gonul E, et al. Primary multiple cerebral hydatid cysts: case report with CT and MRI study. *Minim Invasive Neurosurg* 41: 35-37, 1998.
6. Tunçalp, Ö. Aykut, E, Vural, B, et al. The use of computerized tomography in the diagnosis of cerebral hydatid cysts. *J Neurosurg* 50: 339-342, 1979.
7. Ramsey PG, Plorde JJ. Cestode infections, in Braunwald E (ed): *Harrison's Principles of Internal Medicine*. New York, McGraw Hill, 1987, ed 11, pp 825-829.
8. Sharma SC, Ray RC. Primary hydatid cyst of the brain in an adult: report of a case. *Neurosurgery* 23: 374-376, 1988.

9. Menon V, Desmond J. Left superior parietal cortex involvement in writing: integrating fMRI with lesion evidence. *Brain Res Cogn Brain Res* 12: 337-340, 2001.
10. Dehaene S, Cohen L. Cerebral pathways for calculation: double dissociation between rote verbal and quantitative knowledge of arithmetic. *Cortex* 33: 219-250, 1997.
11. Sukumar S, Ferguson GC. Gerstmann's syndrome. *Postgrad Med J* 72: 314, 1996.
12. Calvo-Romero JM, Bureo-Dacal JC, Ramos-Salado JL. Gerstmann syndrome caused by right parietal ischemic stroke. *Rev Neurol* 16-29; 30: 398-399, 2000.
13. Casado JL, Jarrin S, Madrid A, et al. Increased level of Gerstmann's syndrome secondary to thalamic hematoma. *Rev Neurol* 23: 1051-1052, 1995.
14. Clatterbuck RE, Sampath P, Olivi A. Transitional cell carcinoma presenting as a solitary brain lesion: a case report and review of the world literature. *J Neurooncol* 39: 91-94, 1998.
15. Ilchevsky S, Boev I, Kazakova T. Gerstmann's syndrome following an acute herpes simplex encephalitis. *Folia Med* 40: 52-55, 1998.
16. Day JT, Fisher AG, Mastaglia FL. Alexia with agraphia in multiple sclerosis. *J Neurol Sci* 78:343-348, 1987.
17. Kitano A, Shimomura T, Okada A, et al. Multifocal fibrosclerosis with intracranial pachymeningitis. *Intern Med* 34:267-271, 1995.
18. Maeshima S, Okumura Y, Nakai K, et al. Gerstmann's syndrome associated with chronic subdural haematoma: a case report. *Brain Inj* 12:697-701, 1998.
19. Mazzoni M, Pardossi L, Cantini R, et al. Gerstmann syndrome: a case report. *Cortex* 26:459-467, 1990.
20. Saito H, Sakai H, Fujihara K, et al. Progressive multifocal leukoencephalopathy in a patient with acquired immunodeficiency syndrome (AIDS) manifesting Gerstmann's syndrome. *Tohoku J Exp Med* 186:169-179, 1998.
21. Usui T, Yamane K, Shirata A, et al. Case of Creutzfeldt-Jakob disease with the development of Gerstmann syndrome at its onset. *Nippon Naika Gakkai Zasshi* 84:630-631, 1995.
22. Roeltgen DP, Sevush S, Heilmann KM. Pure Gerstmann's syndrome from a focal lesion. *Arch Neurol* 40:46-47, 1983.
23. Hattingen J, Uerlings A, Jaussi R. Alveolar echinococcosis of the liver with lymphogenous, pulmonary and cerebral metastasis. Cerebral alveolar hydatidosis: case report. *Surg Neurol* 45:575-581, 1996.
24. Taratuto AL, Venturiello SM. Echinococcosis. *Brain Pathol* 7: 673-679, 1997.
25. Vatanserver M, Biliciler B, Aladag MA, et al. A huge cerebral hydatid cyst associated with small liver cyst: a comparison of growth rates and sizes. *Neurosurg Rev* 19:123-126, 1996.
26. Carcassonne M, Aubrespy P, Dor V. Hydatid cysts in childhood. *Prog Pediatr Surg* 5:1-35, 1973.
27. Saidi P, Nazarian I. Surgical treatment of hydatid cyst. *N Engl J Med* 284: 1346-1348, 1983.