

Kaan ERLER¹
Mahmut KÖMÜRCÜ¹
M.Taner ÖZDEMİR¹
U. Barış ÖZKAL¹
Mustafa BAŞBOZKURT¹
Ömer GÜNHAN²

Echinococcus Infestation of Quadriceps Femoris Muscle Misdiagnosed as a Soft Tissue Tumor (A Case Report)

Departments of ¹Orthopedics and Traumatology, ²Pathology Gülhane Military Medical Academy, Etlik, Ankara - TURKEY

Received: December 13, 2002

Key Words: Echinococcosis, muscle involvement

Case Report

A 41-year-old man who had a soft tissue mass in the right thigh was admitted to our hospital because of the enlargement of the mass over a 2-year period. Physical examination revealed a non-tender, palpable soft tissue mass placed in the region of the quadriceps femoris muscle. No fluctuance, erythema, ecchymosis, increased warmth or lymphadenopathy was determined. Conventional radiography showed a soft tissue mass without calcification. On T1-weighted MRI images, a slightly heterogeneous, well distinguished bordered 10 x 5 x 3.5 cm sized mass in relation to the vastus medialis, vastus intermedius, rectus femoris and sartorius muscles was determined. Obvious capsule formation and no invasion to adjacent tissues were seen. **On T2-weighted images the mass was seen to have isointensity with subcutaneous fat.** (Figure 1A-B: Axial T1- and Coronal T2-weighted MRI scans of the lesion.) In accordance with clinical behavior and **MRI interpretation by our orthopedic oncology staff**, an incisional biopsy was sought since the differential diagnosis included a soft tissue tumor.

Closed biopsy with a high speed biopsy needle was performed but the results of the biopsy were inconclusive. After informed consent was obtained, we decided to resect the mass en-bloc and make an intraoperative frozen section. A wide resection was performed including previous biopsy tract. The mass was submitted for frozen section and histological evaluation. The cross section of the pathological specimen showed a yellow and orange, encapsulated cystic structure full of clear liquid. Pathological diagnosis was reported as E.

Granulosus infestation of the quadriceps femoris muscle (Figure 2: Histological appearance of hydatid cyst).

We reviewed all clinical and radiological data to avoid repeat misdiagnosis in such cases. Gastrointestinal, hepatobiliary system and lung evaluations were performed in order to find the primary focus, but no pathological findings were obtained. Thereafter, we believed that this case presented a primary intramuscular hydatosis of the quadriceps femoris muscle. Antiechinococcal Ig G was measured shortly after the operation and its levels were found to be high 2.84 Mg/ml (>1 Mg/ml). Two consecutive measurements were within normal limits after a 6-month period. There was no evidence of local recurrence or systemic spreading after 2 years.

Hydatid disease of the muscle is very rare, occurring in approximately 0.5-5% of all patients with hydatosis (3-5). In the literature, the primary localization of intramuscular echinococcosis is quite rare and few cases have been reported (1,2,4,6). The preoperative recognition of this rare clinical entity is very difficult. Echinococcus infestation must be considered in patients admitted with a soft tissue tumor, especially those who live in endemic areas (2,6).

The diagnostic modalities widely used include ultrasound, computed tomography and magnetic resonance imaging (MRI) (7,8). The imaging of intramuscular hydatosis demonstrates the multilocular cystic structure and sometimes the scolices within (4,7,9). Typically, MRI has a low signal intensity on T1-weighted images and a high signal intensity on T2-weighted images (5,7,8). However, these findings have

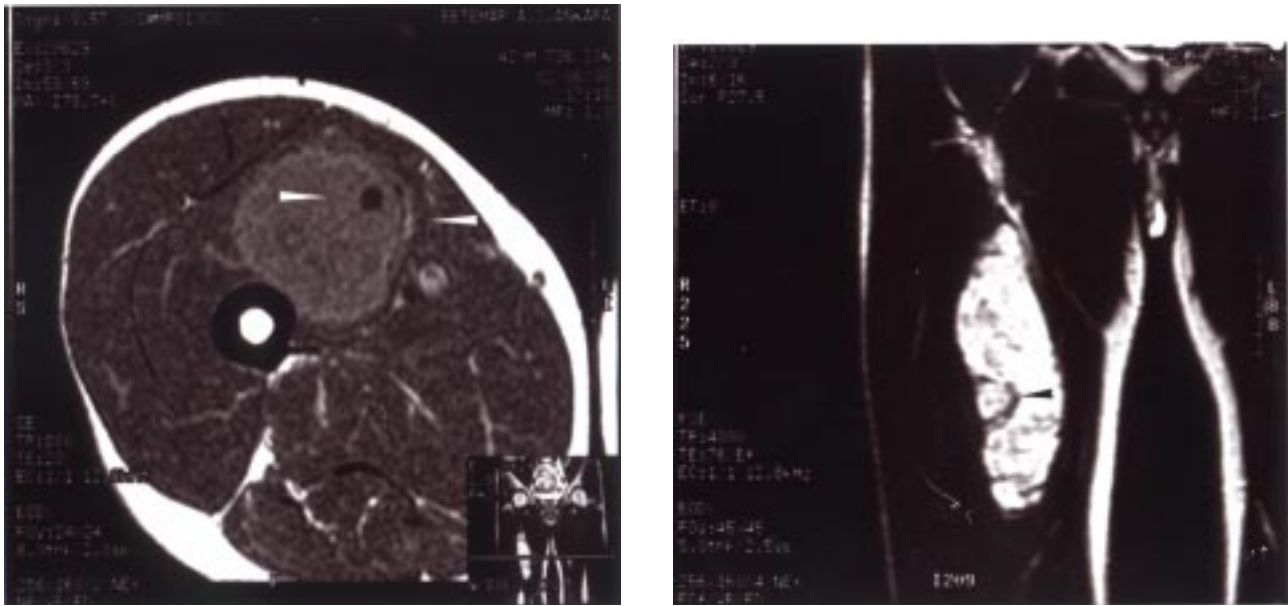


Figure 1. A-B: Axial T1 and coronal T2 weighted MRI scans of the lesion.

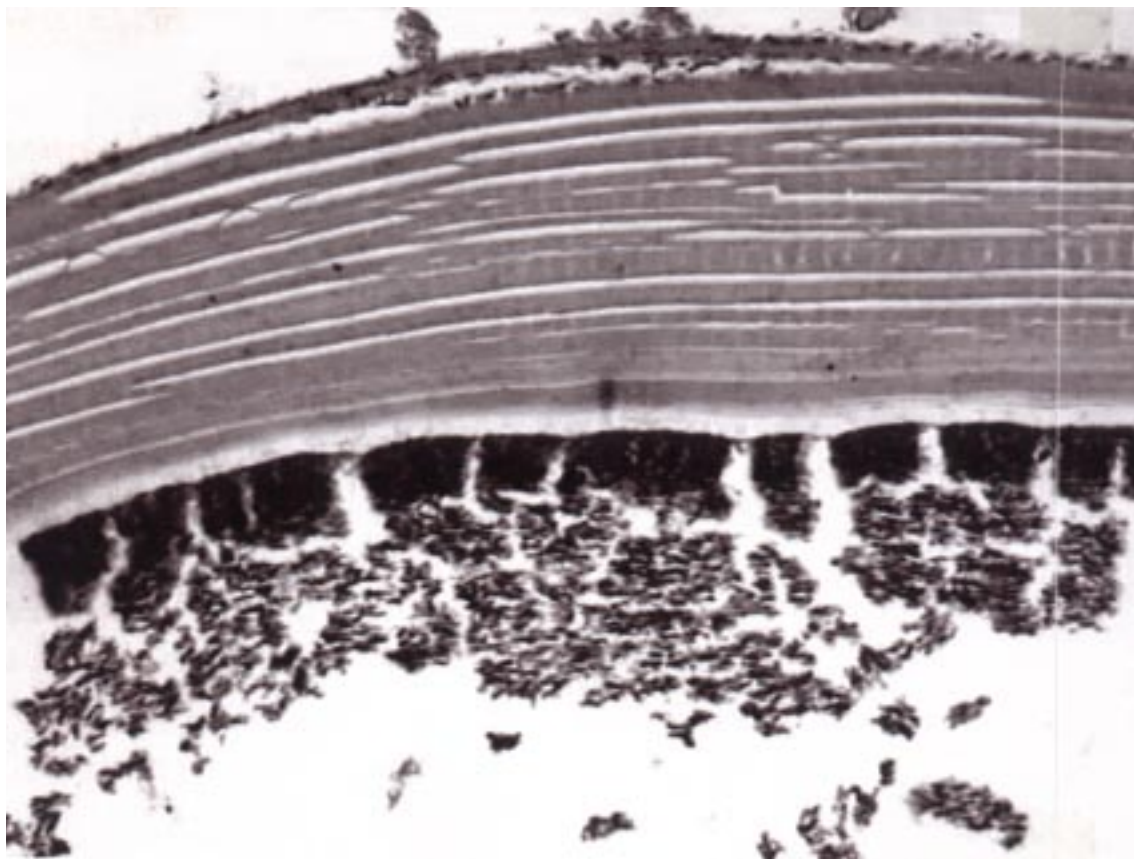


Figure 2. Histological appearance of hydatid cyst. Characteristic germinal layer which is productive layer of the lesion is the exact histopathological interpretation. Stain H&E: X 40.

also been obtained from soft tissue tumors. After contrast enhancement, cystic structures show a significant peripheral rim; these findings also occur in some soft tissue tumors. However, in our case no multicystic appearance was reported, though on T1-weighted images in the lesion some small hypointense appearances were seen.

Fine needle aspiration biopsy of the hydatid cyst is a contemporary diagnostic procedure and may be used for percutaneous aspiration and drainage (10). The complications of this procedure (simple allergic reactions to anaphylaxis) usually occur with non-intentional attempts at a rate of 19%. Von Sinner reported that only in seven of 31 patients was the specimen diagnostic upon initial interpretation and this result was mostly related to non-representative material or inadequate examination technique.

As reported in the literature, the best treatment for the lesion is the complete excision of the intact cyst (2,3,6). Perioperative medical therapy may be added to surgical treatment, including chemotherapy with albendazole or mebendazole, or intracystic injection of ethanol or hypertonic saline solution (2,6). These procedures may help to prevent complications and recurrence as well as the risk of it spreading to distant organs. Thus, the excision of an intact cyst is usually curative, whereas cyst rupture may be fatal. Inadvertent cyst rupture during surgery may cause the dissemination of the scoleces to distant organs or anaphylactic shock. The propensity for recurrence and dissemination mortality is about 70%. If inadequate surgery has been performed anthelmintic therapy should be given to

patient until Ig G antibody titers return to normal limits. This measurement is a secure way to test for the need for further treatment or the recurrence of disease.

This report presents a very unusual case of primary intramuscular infestation of echinococcus granulosus misdiagnosed as a soft tissue tumor preliminarily, and treated successfully by en bloc resection. The main reasons for the misdiagnosis of this case were rapid progression of the mass and inconclusive previous pathological reports. It is important to identify or suspect the presence of hydatid cyst prior to surgery. Adequate biopsy technique and the effective usage of histopathological applications may assist early diagnosis and improve the treatment of hydatid disease. We think that preoperative planning and surgical technique play major roles in preventing any recurrence of the condition. The patient should be evaluated in order to determine whether there is another focus of dissemination, especially hepatic and pulmonary involvement. We propose that medical practitioners consider echinococcus infestation in the differential diagnosis of any soft tissue tumor and high light the importance of different MRI sequences.

This study received no financial support. The authors have received nothing of value for their work.

Correspondence author:

Kaan ERLER

Department of Ortopedics and Travmatology,

Gülhane Military Medical Academy,

Etilik, 06018 Ankara – TURKEY

E-mail: kaanerler@hotmail.com

References

1. Keskin D, Ezirmik N, Karsan O, et al. Primary hydatidosis of the gracilis muscle in a girl. *J Int Med Res* 30(4): 449-451, 2002.
2. Cannon CP, Nelson SD, Panosian CB, et al. *Clin Orthop* 385: 186-191, 2001.
3. Yıldız Y, Bayrakçı K, Altay M, et al. The use of polymethylmethacrylate in the management of hydatid disease of bone. *J Bone Joint Surg [Br]* 83-B: 1005-1008, 2001.
4. Tatari H, Baran Ö, Şanlıdağ T, et al. Primary intramuscular hydatosis of supraspinatus muscle. *Arch Orthop Trauma Surg*, 121: 93-94, 2001.
5. Manisalı M, Özaksoy D, Kovanlıkaya I. The role of imaging in cardiac echinococcosis. *Am J Roentgenol* 168: 282-283, 1997.
6. Tokmak M, Bekler H, Alioğlu Y, et al. Primary muscular hydatid cyst disease. *Acta Orthop Traumatol Turc* 29(2): 167-169, 1995.
7. Memiş A, Arkun R, Bilgen I, et al. Primary soft tissue hydatid disease: report of two cases with MRI characteristics. *Eur Radiol*, 9(6): 1101-1103, 1996.

8. Tarhan NC, Tuncay IC, Barutçu O, et al. Unusual presentation of an infected primary hydatid cyst of biceps femoris muscle. *Skeletal Radiol* 31(10): 608-11, 2002.
9. Merkle EM, Schulte M, Vogel J, et al. Musculoskeletal involvement in cystic echinococcosis: Report of eight cases and review of the literature. *Am J Roentgenol*, 168: 1531-1534, 1997.
10. Von Sinner WN, Nyman R, Linjawi T, et al. Fine needle aspiration biopsy of hydatid disease. *Acta Radiologica* 36(2): 168-172, 1995.