

Mehmet Dumlu AYDIN

Repair of Myeloschisis Defect with Tutoplast

Department of Neurosurgery, Faculty of
Medicine, Atatürk University, Erzurum -
Turkey

Received: February 25, 2003

Key Words: Myeloschisis, Tutoplast, Repair

Myeloschisis is defined as an open neural tube defect involving malformation of the vertebral arches, absence of meninges and structural or functional spinal cord abnormalities. Neural placode is located ventrally and is often opposed to the underlying spinal canal (1). Myeloschisis defects are difficult to repair due to soft tissue agenesis in the defective region, fragility of the dura in such areas, a deep narrow field and cerebrospinal fluid (CSF) leakage (2). Many substances have been used for repair, but a satisfactory solution has not been found. Dural graft causes neomembrane formation and wound healing, without immunologic problems (3-5). Tutoplast dura has favorable implantation characteristics (6).

In this report, a 3-day-old girl with a large myeloschisis defect (5 x 6 cm) located in the thoracolumbar region is presented. The defect was closed with Tutoplast and her wound completely healed in 3 months without complication. I recommend the use of a Tutoplast graft for the closure of large Myeloschisis defects in the absence of adequate muscular and fascial tissue.

Case Report

The 3-day-old girl concerned was the product of an uncomplicated pregnancy and normal birth. During birth, the patient was noted to have a huge defective area on the thoraco-lumbar region concomitantly leaking fluid. Physical examination disclosed a myeloschisis with a 5 x 6cm in diameter ellipsoid defective area. There was no duramater or arachnoid membrane over the spinal cord but there was hemorrhagic CSF-like material leakage (Fig. 1). Other systemic observations were almost normal. Lumbar MRI revealed agenesis of the posterior elements of the Th₁₁-L₂ vertebrae and myelo-dysgenesis

of the terminal cord. Grade II hydrocephalus was detected on cranial MRI. The patient underwent surgery for myeloschisis repair. After successful anesthesia and intubation, the patient was placed in a prone position. The lesion was measured and other border atresic tissue was debrided. Normal tissue was determined, and placode was preferably separated from the dysplastic tissues by the use of sharp dissection. With the successful circumferential mobilization of dysgenetic neural placode, its ventral descent dysplastic meningeal remnants and cutaneous layers were removed to avoid long-term problems. Neural placode was mobilized with the excision of dysplastic tissues, and identification of the underlying layers, and reconstitution of the neural tube was performed. Then a tutoplast dural graft was perforated with a needle in multiple areas in order to provide vascularization and soft tissue augmentation; it was inserted as a fascia and deep muscular layer (Fig. 2). After reconstruction, the large skin defect was closed completely by "Y" plasty (Fig. 3). CSF leakage was interrupted and the patient was discharged on the 6th postoperative day. The myeloschisis defect closed completely 3 months after the operation (Fig. 4). Control MRI disclosed grade III hydrocephalus, with 52 cm head circumference after 8 months. A ventriculo-peritoneal shunt was inserted into the patient for hydrocephalus. The wound was not presenting a problem and her head circumference was normal at a 1 year follow-up. T₁-W spinal MRI performed after 30 months revealed an atresic medullary conus, a hydromyelic cavity in the upper thoracic cord, a large lumbar spinal canal and dysgenetic lipid tissue in the caudal region (Fig. 5).

There is frequently a need for dural grafts to cover defects resulting from congenital pathologies, traumas and neurosurgical procedures (3). The usual location of

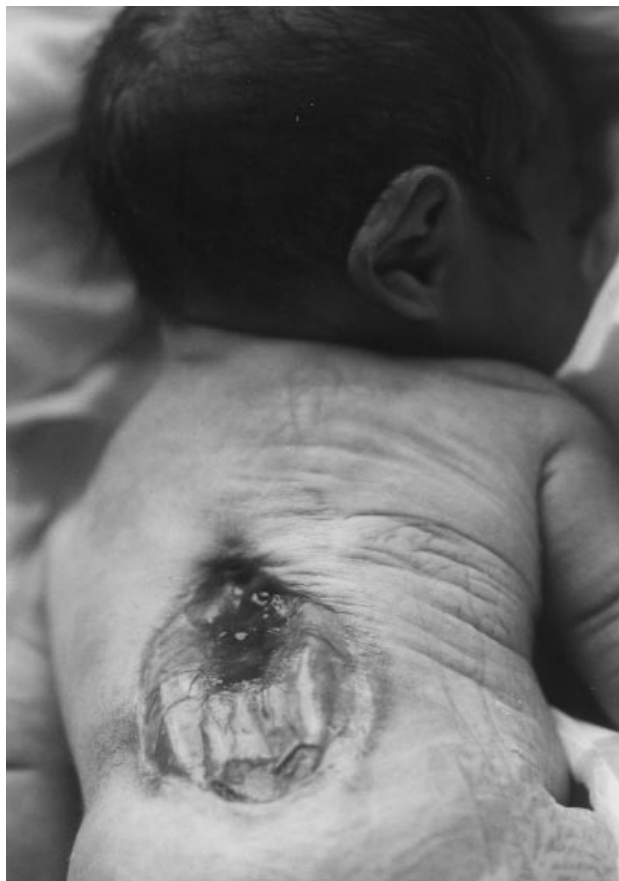

Figure 1. The patient is seen with a large myeloschisis defect.

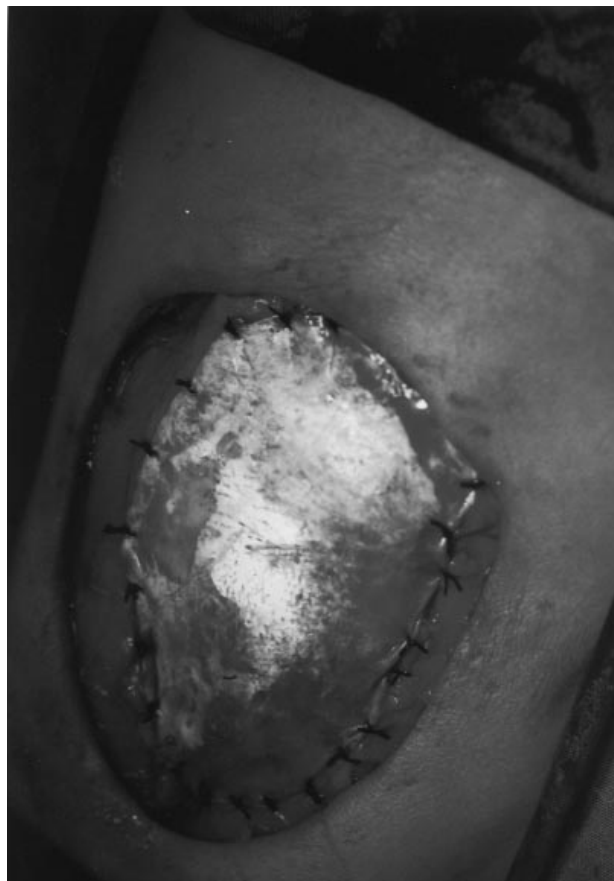


Figure 2. Implanted Tutoplast is seen on the defective area.

human neural tube defects at the rostral or caudal end of the primary neural tube suggests that they are caused by the failure of closure of the neural tube. Spinal dural tears are difficult to repair due to the difficulties in gaining appropriate access and the fragility of the dura in such areas. The important problems are deep narrow field and soft tissue agenesis at the defective area in myeloschisis and CSF leakage (2). Different tissues and materials have been evaluated for use in dural repair. However, an entirely satisfactory solution remains to be found (5).

Several groups have begun to explore the feasibility and utility of intrauterine closure of myelomeningocele by using bipedicular flaps to close these lesions (2). Lyophilized bovine pericardium, fascia, biosynthetic Sellulose (7), Tutoplast dura and Zenoderm Corium implants (2) have been used for dural grafting. Irradiated human dura mater is well tolerated, and it seems to be useful for soft-tissue augmentation, and may provide good results clinically. Duraplasties are performed with

sutures alone or are additionally fixed with fibrin glue (7). Tutoplast dura has favorable implantation characteristics; it is thin, flexible and easily suturable. It does not cause erythema, purulence, hematoma or seroma formation, wound dehiscence, graft extrusion or flap necrosis (4,7). Graft encapsulation, neomembrane formation, delayed hemorrhage, infection, cellular and humoral response and CSF fistulae, adhesion, space occupying-compressive mass and foreign body reactions have not been reported in Tutoplast employment (1,3,5,8,9). It was stated that Tutoplast dura is characterized by its remarkably better surgical utility in comparison to Zenoderm-Corium implants. Additional mechanical reinforcement with polyester net is not necessary (6). Irradiated human dura mater is very useful in soft-tissue augmentation at 3-6 months. It is well tolerated and may provide good results clinically (4,10).

In summary, it is advocated that duraplasties may be performed with sutures alone or additionally fixed with

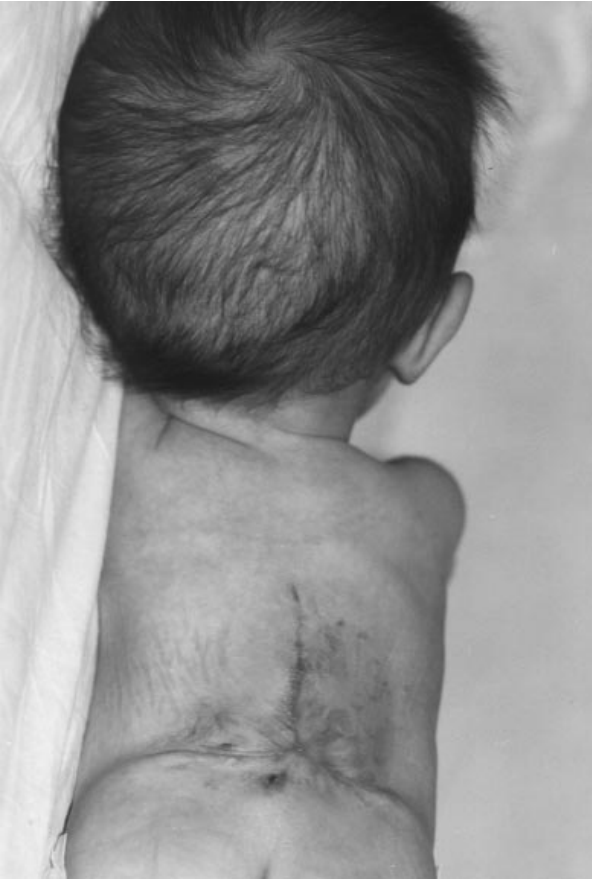

Figure 3. The patient is seen after the reconstruction and closure of the defect completely by "Y" plasty on day 2 of surgery.

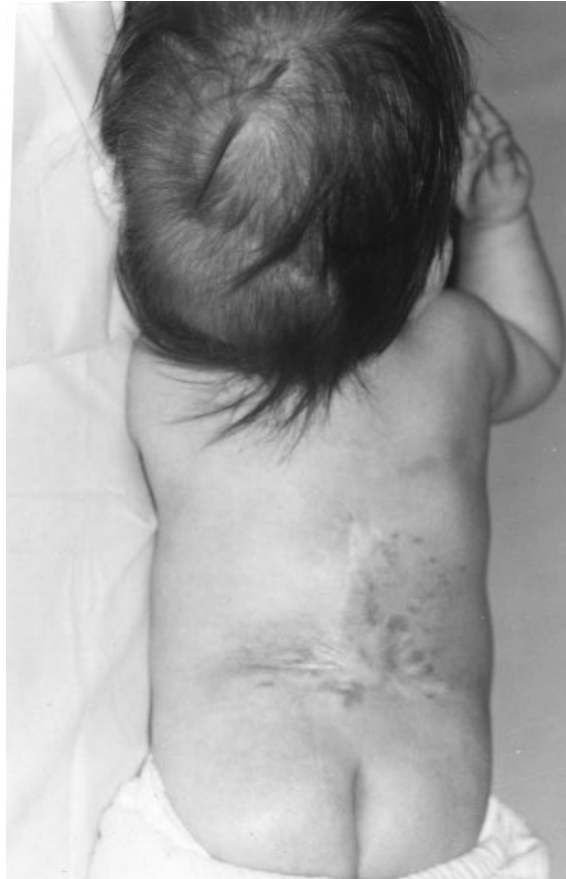

Figure 4. The myeloschisis defect closed completely by the epithelization of cutaneous tissues over the Tutoplast dura 3 months after the operation.

fibrin glue. The tightness values for neuropatch fixed only with sutures are similar to those for the best heterologous substitutes implanted with additional fibrin glue. Lyodura, Tutoplast dura and Neuropatch ought to demonstrate favorable implantation characteristics; they must consist of thin, flexible and easily suturable nature. Because neither adhesions to the nervous tissue nor space-occupying scars have been noted, these results confirm the excellent suitability of Lyodura and Neuropatch for dural substitution (11). Since tethering of the spinal cord is a well-recognized problem, to avoid retethering a wide Tutoplast duraplasty is recommended (12).

In conclusion, I advocate the use of Tutoplast to cover myeloschisis defects for primary closure in the absence of adequate dural, fascial and muscular layers. Tutoplast implantation can prevent postoperative CSF leakage, adhesion of the neural-nonneural compartments and vertebrospinal circulatory disorders related to surgical intervention.

Correspondence author:

Mehmet Dumlu AYDIN

Terminal Mah. Otel Oral karsisi,

Kamer Apt. Kat. 5, No-17 Erzurum - TURKEY

E-mail: naydin@atauni.edu.tr or nmda21@hotmail.com

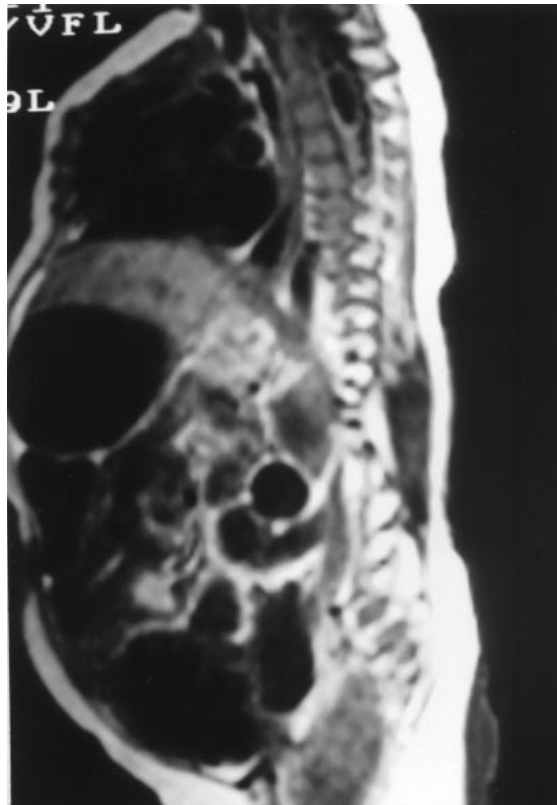


Figure 5. T₁-W spinal MRI performed after 30 months, shows an atresic medullary conus, a hydromyelic cavity in the upper thoracic cord, and large lumbar spinal canal and dysgenetic lipid tissue in the caudal region.

References

1. Hagele D, Fruhwirth O, Kriesche H, et al. Results of sling surgery using Tutoplast dura. *Geburtshilfe Frauenheilkd* 43: 762-765, 1983.
2. Mangels KJ, Tulipan N, Bruner JP, et al. Use of bipedicular advancement flaps for intrauterine closure of myeloschisis. *Pediatr Neurosurg* 32: 52-56, 2000.
3. Baglaj SM, Wytrychowski K, Staniszevska-Kus J. Tutoplast-Dura and Zenoderm-Corium implant—materials for tissue replacement. *Experimental studies. Polim Med* 22: 13-25, 1992.
4. Campbell LR, Sohal GS. The pattern of neural tube defects created by secondary reopening of the neural tube. *J Child Neurol* 5: 336-340, 1990.
5. Perry VL, Albright AL, Adelson PD. Operative nuances of myelomeningocele closure. *Neurosurgery* 51: 719-724, 2002.
6. Mello LR, Feltrin LT, Fontes Neto PT, et al. Duraplasty with biosynthetic cellulose: an experimental study. *J Neurosurg* 86: 143-150, 2000.
7. Nordstrom MR, Wang TD, Neel HB. Dura mater for soft-tissue augmentation. Evaluation in a rabbit model. *Arch Otolaryngol Head Neck Surg* 119: 208-214, 1993.
8. Keller JT, Ongkiko CM Jr, Saunders MC, et al. Repair of spinal dural defects. An experimental study. *J Neurosurg* 60: 1022-1028, 1984.
9. Vanaclocha V, Saiz N, Panta F. Repair of dural defects in awkward areas—technical note. *Acta Neurochir* 140: 615-618, 1998.
10. Laun A, Tonn JC, Jerusalem C. Comparative study of lyophilized human dura mater and lyophilized bovine pericardium as dural substitutes in neurosurgery. *Acta Neurochir* 107: 16-21, 1990.
11. Filippi R, Derdilopoulos A, Heimann A, et al. Tightness of duraplasty in rabbits: a comparative study. *Neurosurgery* 46: 1470-1476, 2000.
12. Smith KA and ReKate HL. Delayed postoperative tethering of the cervical spinal cord. *J Neurosurg* 81: 196-201, 1994.