

CLINICAL INVESTIGATIONS

Expression of the Tumour Suppressor Gene p53 in Odontogenic Cysts

Ayla ÖZVEREN¹, Can TUSKAN³, Mehmet YALTIRIK³, Belir ATALAY³, Gülçin ERSEVEN²

¹Department of Oncological Cytology, Faculty of Dentistry, İstanbul University, İstanbul - Turkey

²Department of Tumour Pathology, Faculty of Dentistry, İstanbul University, İstanbul - Turkey

³Department of Oral Surgery, Faculty of Dentistry, İstanbul University, İstanbul - Turkey

Received: September 09, 2002

Abstract: The protein p53 seems to be related to the suppression of cell proliferation. Positive tissues appear to have a higher proliferative activity than negative tissues.

Mutation of the p53 tumour suppressor gene has been demonstrated in a large proportion of human head and neck tumours, although no formal evidence of functional aberration has been shown p53 may have importance during the early stage of malignancy.

The aim of this study was to evaluate the role of the p53 tumour suppressor gene in the pathogenesis of odontogenic cysts. Expression of abnormal p53 protein is a widely recognised marker of malignancy.

Expression of p53 was evaluated immunohistochemically in a retrospective study of formalin-fixed, paraffin-embedded tissue. Forty cases of odontogenic cysts were examined for expression of p53 protein by a immunohistochemical technique and positive results of the p53 protein were demonstrated by nuclear staining.

Twenty-seven of 40 odontogenic cyst cases were positive for p53 protein. The differences between the groups were statistically significant (P = 0.02).

The incidence of p53 protein nuclear accumulation detected by immunohistochemistry is high in odontogenic lesions. The present data indicate that p53 inactivation plays a role both in the initiation and in the progression of odontogenic cysts.

Key Words: Odontogenic cysts, p53 protein, immunohistochemistry.

Introduction

Two types of gene have been implicated in the development of the malignant phenotype. The first type is proto-oncogenes, which become activated in response to various mitogenic signals (1-4).

When mutated they become oncogenes (or cancer-causing genes) and give rise to proteins which lead to abnormal cell growth. Altered expression of single oncogenes is generally insufficient to induce full transformation and in most cases activation of several oncogenes contributes to the tumorigenic process. The

second type of genes implicated in the pathogenesis of the malignant phenotype is the tumour suppressor genes, encoding proteins which have the ability to suppress cell division (1-5).

During tumour development, tumour suppressor genes often become mutated or deleted and lose their normal function, which is to negatively regulate cell growth. These genes may play a more important role in the development of neoplasia than oncogenes (1-5).

The p53 gene on chromosome 17 is a tumour suppressor gene and mutation is common to a wide range

of human tumours and a frequent step in neoplastic transformation (1-4).

The p53 protein is present in extremely low concentrations in normal cells, owing to its very short half-life and it is virtually undetectable by immunohistochemical techniques. Hence, the ability to detect the protein in tumours is probably synonymous with the presence of a mutation since mutation has been shown to be a stable protein that accumulates in cells, allowing it to be detected immunohistochemically (1-6).

Numerous studies have reported the presence of p53 protein in human tumours by immunostaining histological sections and this has been considered to reflect the presence of a p53 mutation (3,4,6-8).

Furthermore, a more recent study of preneoplastic and neoplastic lesions of the oral mucosa has shown that p53 overexpression is related to increasing dysplasia and loss of differentiation during the development of oral malignancy (2-4,6).

The aim of the present study was to immunohistochemically evaluate the expression of p53 protein in different types of odontogenic cysts.

We have now immunostained a larger series of odontogenic cysts with the mouse monoclonal antibody D07 to determine whether p53 expression correlates with histological features.

Materials and Methods

Surgical specimens from 40 cases of odontogenic cysts were fixed in 10% formalin and embedded in paraffin according to standard procedures. Sections were stained with haematoxylin and eosin and examined histopathologically.

The lesions which were histopathologically examined consisted of 11 keratocysts, nine radicular cysts and 20 dentigerous cysts. A total of 40 individuals, 19 male and 21 female aged between 12 and 62 with a total of 40 odontogenic cysts (20 localised in the maxilla and 20 in the mandible) were investigated. The diameter of the cysts varied between 0.8 cm and 6.0 cm. Then representative sections were immunostained for p53 protein.

Descriptive statistical analysis was performed for each group of lesions and a chi-square test was used to show statistically significant differences between the groups.

Immunohistochemistry

All samples were formalin-fixed, paraffin-embedded tissue blocks. Each tissue block was sectioned serially into 5-mm-thick pieces and these were put on to poly-L-lysine coated slides. Sections were deparaffinized and rehydrated with distilled water. For the microwave antigen retrieval method, sections were immersed in 75 ml of citrate buffer and irradiated in a domestic microwave oven at full power (750 W) for 2 x 5 min. Microwaved sections were incubated for a further 20 min in the hot buffer and put into phosphate buffered saline (PBS; pH 7.6).

In the immunohistochemical analysis, anti-p53 monoclonal prediluted antibody (p53 D07, Dako), HRP labelled streptavidin-biotin (LSAB HRP, Dako) system and AEC chromogen (3% 3-amino-9-ethylcarbazole) were used.

The primary antibody was applied for 30 min at room temperature. Chromatogens were stained with haematoxylin and examined under a light microscope.

A positive control specimen, which was an oral squamous cell carcinoma before being determined as p53 positive, was used to standardise the procedure between batches. For negative control tests, nonimmunised mouse sera were used and the primary antibody was omitted.

The staining of all sections was evaluated by two independent observers and the intensity of nuclear staining was graded as (-) negative, (+) weak staining, (++) moderate staining or (+++) strong staining.

Results

In our research, p53 immunostaining results of odontogenic cysts were compared: in 13 (-) staining was detected, and in 27 (+). Positive staining for p53 protein was noted in 10/11 keratocysts (99%), 4/9 radicular cysts (45%) and 13/20 dentigerous cysts (65%) (Table 1).

p53-positive cells in radicular cysts and odontogenic keratocysts were diffuse in the parabasal layers (Figs. 1-2).

In dentigerous cysts the p53 positivity was mainly located in the basal layers as generally focal and odontogenic epithelial islands (Figs. 3-4).

The differences between the groups were statistically significant ($P = 0.02$).

Table 1. Immunostaining results of odontogenic cyst with antibody to p53.

LESIONS	NUMBER OF CASES	IMMUNOSTAINING WITH ANTIBODY TO P53				RANGE
		(-)	(+)	(++)	(+++)	
ODONTOGENIC KERATOCYSTS	11	1	1	6	3	10 / 11
RADICULAR CYSTS	9	5	1	1	2	4 / 9
DENTIGEROUSCYSTS	20	7	6	4	3	13 / 20
TOTAL	40	13	27			

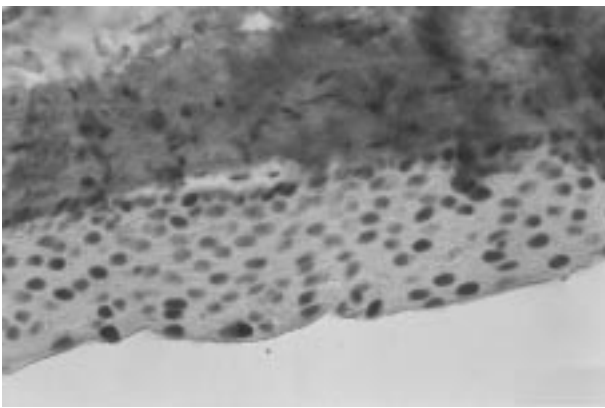


Figure 1. Diffuse positive p53 nuclear staining in the parabasal layers of the epithelial lining of an odontogenic keratocyst (D07, LSAB; x250).

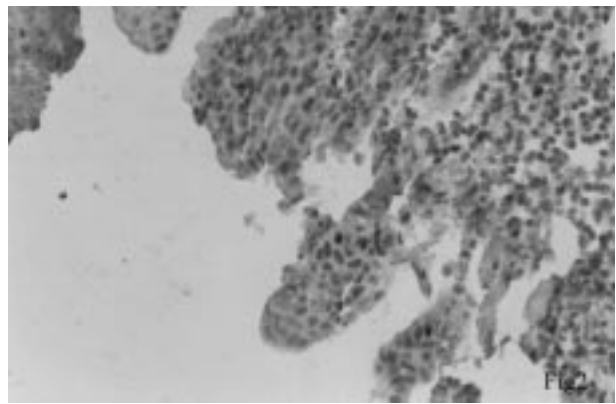


Figure 2. Diffuse positive p53 nuclear staining in the parabasal layers of the epithelial lining of a radicular cyst (D07, LSAB; x250).

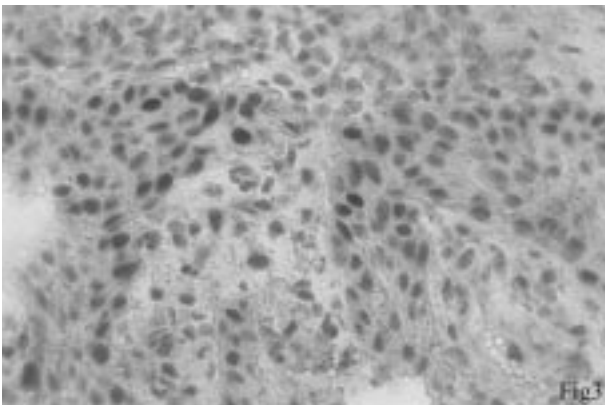


Figure 3. Focal positive p53 nuclear staining in the odontogenic epithelium of a dentigerous cyst (D07, LSAB; x400).

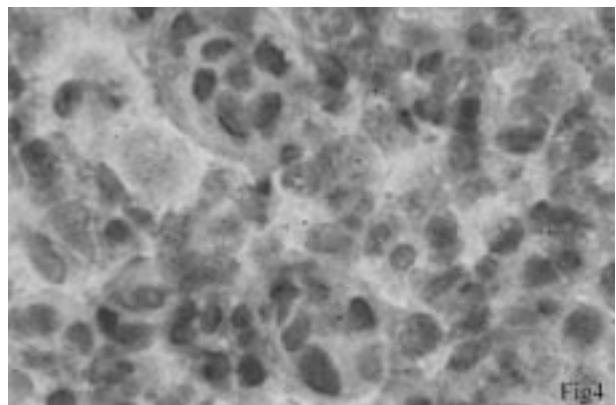


Figure 4. Focal positive p53 nuclear staining in the odontogenic epithelium of an odontogenic cyst. (D07, LSAB; x1000).

The nuclei of the positive control cells were positive and the negative controls were non-reactive.

Discussion

An increase in cell proliferation probably plays a role in the development of odontogenic cysts and tumours (9-13). p53 protein probably has a role in the regulation of the transcription of genes that suppress cell proliferation (9-12). Wild-type p53 protein acting as a tumour suppressor down-regulated cell growth, but mutation in p53 can inactivate its tumour suppressor activity, allowing the dominant oncogenic factor to cause malignant transformation (6-8,9-14).

The p53 protein is normally expressed at low levels in non-transformed cells; however, elevated expression was found in many tumour and cells lines (3,4).

It was previously considered that immunohistochemical detection of p53 protein is possible only when the protein is overexpressed or accumulates in cells as a result of mutation. Therefore, p53 immunostaining has been used as a marker of neoplasia, malignancy and tumour progression (1-6).

Many studies have shown that mutations of the p53 tumour suppressor gene are frequently detected genetic alterations in human cancers (3-4,6-8).

Alterations in the p53 gene have been proposed as one of the major factors responsible for both the initiation and progression of oral cancer. Both loss of heterozygosity and point mutations of the p53 gene have been reported to occur in oral cancer. A moderate to high prevalence of p53 overexpression in upper aerodigestive tract squamous cell carcinomas has been found (3-6,8).

Thus, mutation of the p53 gene may be considered a prevalent finding in malignancies in the oral mucosa and the head and neck region (1-3,5-6). p53-positive tissue seems to have a higher proliferative activity than p53-negative epithelia (1,7,8).

Odontogenic keratocysts appear to have an epithelial lining with an intrinsic growth potential and have a marked tendency to recur. This suggests an increased epithelial atypia (8,11-14).

Due to its sometimes aggressive, persistent behaviour, some authors believe that odontogenic keratocysts can be considered benign cystic tumors (12).

Moreover, in some cases of odontogenic keratocyst, epithelial dysplasia is present and it seems that keratinising cysts have a greater tendency for malignant transformation (11,12).

The biological features of the cyst epithelium may be related to recurrences: the mitotic index of odontogenic keratocysts lining epithelial cells is greater than in other types of odontogenic cysts (11-14).

Slootweg (13) and Li et al. (9) believe that differences in the proliferative activity in odontogenic keratocysts suggest an alteration in the cell's cycle control with an increase in cell proliferation that could explain the biological behaviour of odontogenic keratocysts.

We detected the expression of p53 in 27 cases out of 40 using the monoclonal antibody which demonstrates the accumulation of both wild-type and mutated p53 protein and produces a strong staining. In the present study p53 was overexpressed more frequently in odontogenic keratocysts than in other cysts.

Li et al. (9) found that the index of proliferation of suprabasal cells of odontogenic keratocysts was significantly higher (94.4± 22.7) in proliferating cell nuclear antigen positive (PCNA) cells/mm than in radicular cysts (11.0 ±4.1 PCNA + cell/mm) and was similar to that of oral mucosal epithelium (80.8 ± 20.6 PCNA + cell/mm).

Toller (10) used radioactive labelling of cyst lining explants to estimate mitotic activities, and found mean labelling indices of 13% for keratocysts, 1.7% for non-keratotic jaw cysts and 7% for human oral mucous membrane.

The expression of p53 in many reactive lesions is unlikely to be a consequence of gene mutation. Wild-type p53 can accumulate and be determined immunocytochemically in physiological processes such as maturation of haemopoietic cells, DNA repair in fibroblasts and rapidly proliferating lymphocytes (3,4).

Increased cellular proliferation has been shown to result from the expression of defective p53 protein with a subsequent greater risk of the perpetuation of mutation and malignant transformation (5,7).

Slootweg (13) hypothesised that densely staining p53-positive cells in odontogenic lesions are related to increased proliferation.

Higher p53 positivity in radicular and dentigerous

cysts can be explained by regenerative and degenerative changes in the epithelial lining, which are related to inflammations in these cysts.

In conclusion, the incidence of p53 protein nuclear accumulation detected by immunohistochemistry is high in odontogenic lesions. Additional research is needed to highlight the relationship between p53 nuclear accumulation and structural alterations as there seems to be a possible discordance between the results of immunohistochemistry and molecular genetic analyses.

Our results show a higher occurrence of p53 in odontogenic keratocysts than in other jaw cysts. This occurrence is strongly associated with the presence of

epithelial dysplasia in the cyst lining of odontogenic keratocysts.

This needs further investigation because it could have relevance to malignant transformation of the epithelial lining in odontogenic keratocysts.

Corresponding author:

Mehmet YALTIRIK

İstanbul Üniversitesi Dişhekimliği Fakültesi

34390, Çapa, İstanbul - Turkey

E-mail:myaltrk@yahoo.com

References

1. Gopalakrishnan R, Weghorst CM, Lehman TA, et al. Mutated and wild-type p53 expression and HPV integration in proliferative verrucous leukoplakia and oral squamous cell carcinoma. *Oral Surg Oral Med O* 53: 471-477, 1997.
2. Langdon JD, Partridge M. Expression of the tumour p53 in oral cancer. *Brit J Oral Max Surg* , 30: 214-220, 1992.
3. Nigro JM, Baker SJ, Preisinger AC, et al. Mutations in the p53 gene occur in diverse human tumor types. *Nature* 342: 705-708, 1989.
4. Stratton MR. The p53 gene in human cancer. *Eur J Cancer* 28: 293-295, 1992.
5. Wedenberg C, Jönsson A, Hirsch JM. Assessment of p53 and Ki-67 expression in snuff-induced lesions. *Brit J Oral Max Surg* 34: 409-413, 1996.
6. Leung KW, Pedlar J, High AS. Decreasing p53 overexpression in sequential, recurrent, oral squamous cell carcinomas. *Brit J Oral Max Surg* 34: 225-229, 1996.
7. Li TJ, Browne RM, Prime SS, et al. p53 expression in odontogenic keratocyst epithelium. *J Oral Pathol Med* 25: 249-255, 1996.
8. Lombardi T, Odell WE, Morgan PR. p53 immunohistochemistry of odontogenic keratocysts in relation to recurrence, basal-cell budding and basal-cell naevus syndrome. *Archs Oral Biol* 40: 1081-1084, 1995.
9. Li TJ, Browne RM, Matthews JB. Quantification of PCNA + cells within odontogenic jaw cyst epithelium. *J Oral Pathol Med* 23: 184-189, 1994.
10. Toller PA. Autoradiography of explants from odontogenic cysts. *Br Dent J*, 131: 57-61, 1971.
11. Ogden GR, Chisholm DM, Kiddie RA, Lane DP. p53 protein in odontogenic cysts: increased expression in some odontogenic keratocysts. *J Clin Pathol* 45: 1007-10, 1992.
12. Van der Waal. *Diseases of the jaws. Diagnosis and treatment.* Copenhagen: Munksgaard 96-103, 1991.
13. Slootweg PJ. p53 Protein and Ki-67 reactivity in epithelial odontogenic lesions. An immunohistochemical study. *J. Oral Pathol Med* 24: 393-397, 1995.
14. Pattelli A, Fioroni M, Santinelli A et al. p53 Protein expression in odontogenic cysts. *J O Endodon* 27: 459-61, 2001.