

## SHORT REPORT

# Thyroid Hemiagenesis in A Patient With Hypothyroidism\*

Murat ACAR, Aylin YÜCEL, Bumin DEĞİRMENÇİ, Ramazan ALBAYRAK  
Department of Radiology, Faculty of Medicine, Afyon Kocatepe University, Afyon - Turkey

Received: October 09, 2003

**Key Words:** Hemiagenesis of the thyroid, hypothyroidism, ultrasound, computed tomography

Thyroid hemiagenesis is a failure of the embryologic development of a lobe of the thyroid gland. It is a rare congenital anomaly. Thyroid agenesis may be complete, unilateral or isthmic. Congenital hemiagenesis is thought to be the rarest developmental anomaly of the thyroid gland, although, the actual incidence is unknown (1). This condition may be revealed by the co-occurrence of hyperthyroidism, hypothyroidism, colloid goiter or thyroid carcinoma (2). Unlike in our case, in the literature the most common pathology involved in thyroid hemiagenesis is hyperthyroidism (3). The presence of hypothyroidism in a patient with hemiagenesis is extremely rare and very few cases are reported in the literature. In this report we present a patient with left thyroid lobe agenesis and hypothyroidism.

### Case report

A 24-year-old woman was referred for ultrasound examination of the thyroid gland. She had a history of weakness and constipation, but was otherwise asymptomatic. There was no history of surgery or medication. On physical examination the thyroid gland was nonpalpable on the left side. Serum thyroid hormones were mild-moderately low; serum free T<sub>3</sub> was 1.9 pg/ml (normal range: 2.3-4.2 pg/ml) and free T<sub>4</sub> was 0.65 ng/ml (normal range: 0.89-1.8 ng/ml).

Antithyroglobulin and anti - thyroperoxidase autoantibodies were negative. Ultrasound examination showed no thyroid tissue on the left side (Figure 1). The absence of the left lobe was confirmed by computed tomography (CT) scan (Figure 2). The size and echo of right lobe and isthmus were normal at ultrasound examination. The right lobe measured 19 x 10 x 28 mm and the thickness of the isthmus was 7 mm. There was no abnormality of vascularization on color Doppler examination.

The congenital absence of one lobe of the thyroid gland is a rare condition and its etiology is unknown. It has been postulated to occur as a result of a failure of the thyroid anlage to become bilobed followed by unilateral migration (1,4). A review of the available literature shows that patients with thyroid hemiagenesis are predominantly female (3: 1). In addition, the left lobe of the thyroid is absent far more frequently than is the right lobe, at a ratio of 4: 1 (3). Our case report confirms these predominances.

The actual incidence of thyroid hemiagenesis is unknown, since most diagnoses are made in patients admitted for a thyroid scan or thyroid surgery because of a suspicion of other thyroid abnormalities. This could explain the high frequency of the association of hemiagenesis with other thyroid abnormalities, including

\* This paper was presented at TURKRAD 2003, 24. Ulusal Radyoloji Kongresi (8-11 October 2003) in Ankara.

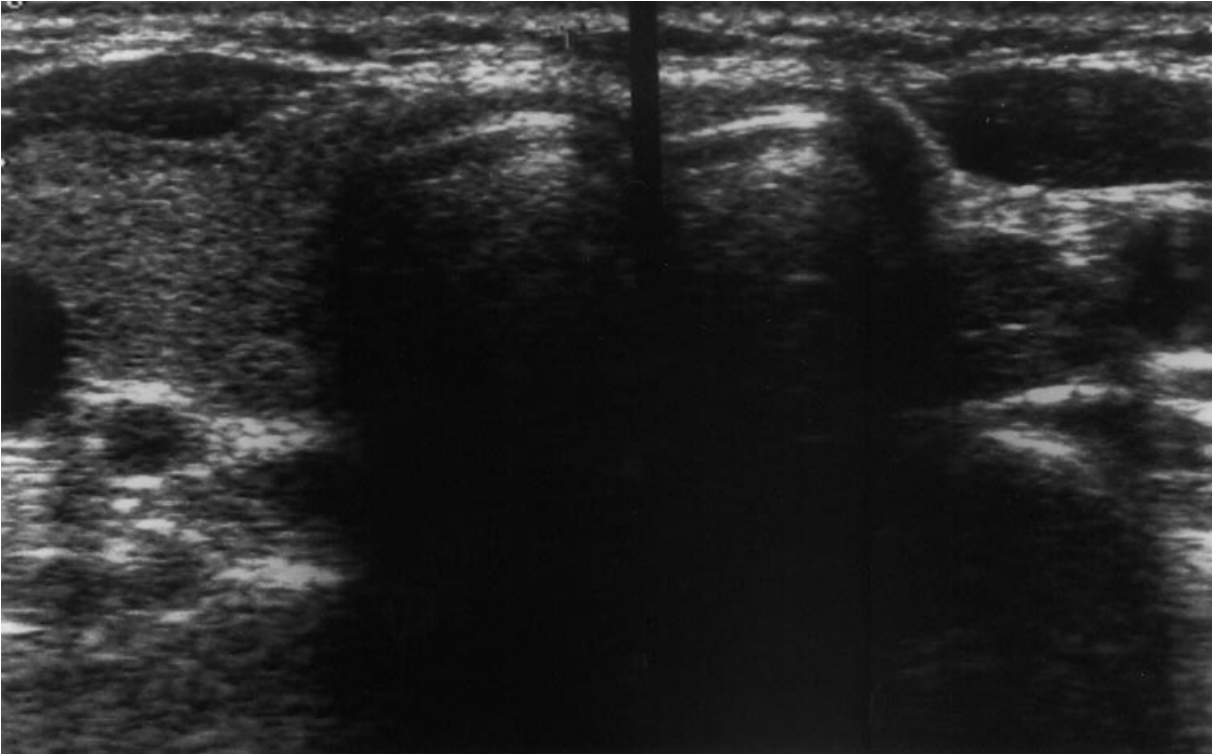


Figure 1. There is normal thyroid tissue on the right, but no thyroid tissue on the left .

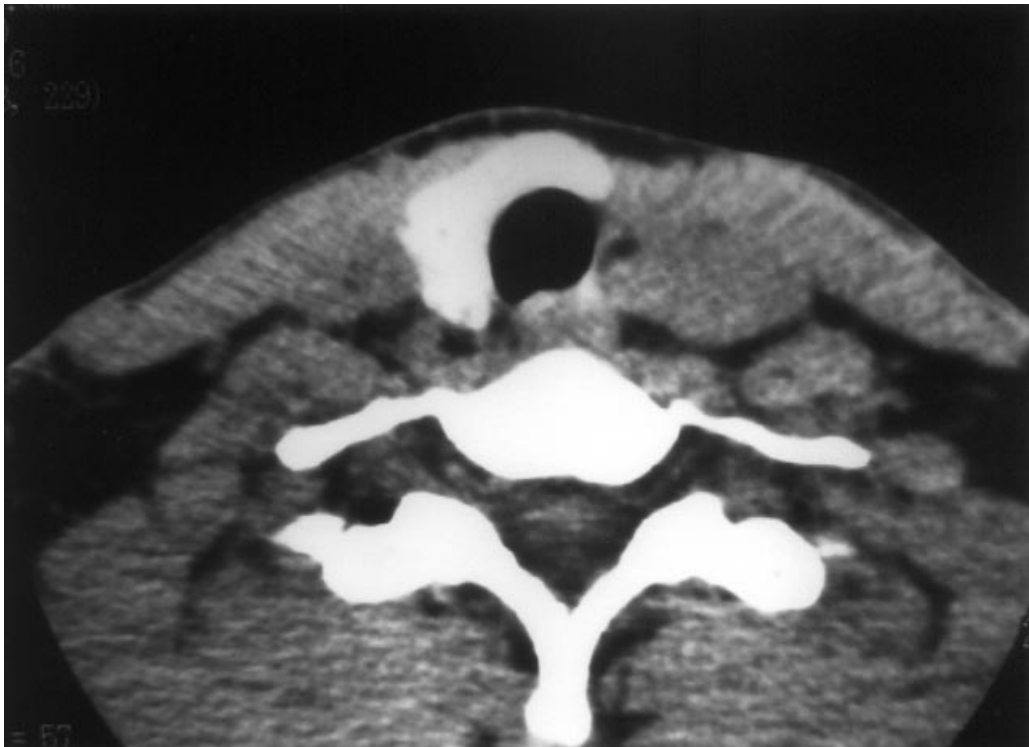


Figure 2. CT shows right lobe and isthmus.

benign adenoma, multinodular goiter, hyper- and hypothyroidism, chronic thyroiditis and carcinoma (3-6).

Thyroid hemigenesis should be suspected in any patient without palpable thyroid tissue on one side of the neck. In addition, in our patient the thyroid gland was nonpalpable on the left side. Radiologically, a definitive diagnosis of thyroid hemigenesis can be made by ultrasound or CT demonstration of the unilateral absence of thyroid tissue. Several thyroid diseases may involve the existing thyroid lobe, which is characterized by diffuse rather than focal involvement. That usually results in a generalized enlargement of the gland, without palpable nodules. Specific conditions that commonly produce such diffuse enlargement include Hashimoto's thyroiditis, colloid or adenomatous goiter, and Graves' disease. The typical sonographic appearance of Hashimoto's thyroiditis is diffuse enlargement with a homogeneous but coarsened parenchymal echo texture, and generally more hypoechoic than a normal thyroid. Although the appearance of diffuse parenchymal inhomogeneity is quite typical of Hashimoto's thyroiditis, it is not specific. Any of the other diffuse thyroid diseases may have an identical sonographic appearance. However, a markedly increased vascularity in the thyroid glands of patients with Graves' disease was described using color Doppler imaging (7). Our patient had negative thyroid

autoantibodies and on ultrasound examination the parenchymal echo texture of the right lobe and isthmus was homogeneous. The vascularity was not increased on color Doppler examination.

Although our patient had mild hypofunction of the thyroid gland, the most common disease of the remaining lobe is hyperthyroidism in thyroid hemigenesis. Hypothyroidism may be an unusual complication of thyroid hemigenesis. The etiology of hypothyroidism is not certain (3,8,9). Thyroid hormone deficiency is associated with peripheral and central nervous system dysfunctions and so early diagnosis of hypothyroidism is very important (5,10). We conclude that thyroid hemigenesis can be demonstrated by CT or ultrasound. Diffuse or focal thyroid diseases in the existing thyroid lobe can be determined with ultrasound or Doppler examination.

*Corresponding author:*

*Murat ACAR  
Afyon Kocatepe University,  
Faculty of Medicine,  
Department of Radiology  
03200, Afyon - Turkey  
e-mail: drmacar@hotmail.com*

## References

1. McHenry CR, Walfish PG, Rosen IB et al. Congenital thyroid hemigenesis. *Am Surg* 61: 634-638. 1995.
2. Burman KD, Adler RA, Wartofsky L. Hemiagenesis of the thyroid gland. *Am J Med* 58: 143-146. 1975.
3. Shaha AR, Gujarati R. Thyroid hemigenesis. *J Surg Oncol* 65: 137-140. 1997.
4. Greening WP, Sarker SK, Osborne MP. Hemiagenesis of the thyroid gland. *Br J Surg* 67: 446-448. 1980.
5. Yıldız M, Bozkurt MK. Thyroid hemigenesis. *J Adolescent Health* 33: 291-292. 2003.
6. Karabay N, Comlekci A, Canda MS et al. Thyroid hemigenesis with multinodular goiter: A case report and review of the literature. *Endocrine Journal* 50: 409-413. 2003.
7. James EM, Charboneau JW, Hay ID: The thyroid. In: Rumack CM, Wilson SR, Charboneau JW.: *Diagnostic Ultrasound*, vol 1. St. Louis: Mosby Year Book 1991, p. 520-522.
8. Konno N, Kanaya A. Thyroid hemigenesis associated with the right aortic arch. *J Endocrinol Invest* 11: 685-687. 1988.
9. Melnick JC, Stemkowski PE. Thyroid hemigenesis (hockey stick sign): A review of the world literature and a report of four cases. *J Clin Endocrinol Metab* 52: 247-251. 1981.
10. Özata M, Özkardeş A, Gündoğan MA. Effects of acute hypothyroidism on brainstem auditory evoked potentials (BAEPs). *Tr J of Medical Sciences* 28: 133-137. 1998.