

SHORT REPORT

Follicular Thyroid Carcinoma in a Patient with Graves' Disease

Mehmet ÖZDOĞAN¹, Ahmet GÜRER¹, Bekir ÇAKIR², Sibel ORHUN³,
İsmail GÖMCELİ¹, Selma GÖÇKUŞ¹, Raci AYDIN¹

¹Departments of General Surgery, Atatürk Educational and Research Hospital, Ankara - Turkey

²Departments of Endocrinology, Atatürk Educational and Research Hospital, Ankara - Turkey

³Departments of Pathology, Atatürk Educational and Research Hospital, Ankara - Turkey

Received: June 07, 2005

Key Words: Follicular cancer, Graves' disease

Thyroid cancer is detected in a small proportion of patients surgically treated for hyperthyroidism. Graves' disease has the least incidence of co-existing thyroid cancer among the different forms of hyperthyroidism (1) and it is almost always papillary cancer when it occurs. In this paper we describe a rare occurrence of follicular cancer in a patient with Graves' disease.

Case Report

A 47 year-old female patient presented to our hospital with symptoms of thyrotoxicosis. She had no family history of thyroid cancer or of radiation exposure in the neck area. On admission, a very advanced ophthalmopathy was present. The patient stated that she had been given PTU 3x300 mg and beta blocker treatment four months previously. Thyroid function tests revealed Free T3:1.12 pg/ml (Normal Range: 1.71-3.71), Free T4:0.19 ng/dl (Normal Range: 0.7-1.48) and TSH: 0.03 uIU/ml (Normal Range: 0.35-4.94). A thyroid ultrasound detected a diffuse enlargement of thyroid with a heterogenic solid nodule measuring 2.8 cm in the right lobe. Thyroglobulin was 206.7 IU/ml (Normal Range: <28.7 IU/ml), anti-thyroglobulin antibody was 34.25 (<28.7 U/l) and TSH receptor antibody was 35.0 U/l (Normal Range: <10 U/l). Because

of the rapid and progressive worsening of the thyrotoxicosis symptoms and ophthalmopathy, the patient was operated on and a total thyroidectomy was performed. Macroscopic examination of the specimen showed a whitish irregular area measuring 1 cm located very close to the thyroid capsule in the right lobe. Pathological examination revealed an invasive follicular cancer based on a diffuse hyperactive macro-follicular thyroid tissue (Figure 1). A trans-nasal orbital decompression procedure was also performed during the same session.

The incidence of thyroid cancer in hyperthyroid patients has variability in different forms of hyperthyroidism, namely multi-nodular toxic goiter, solitary nodular toxic goiter and Graves' disease. Thyroid cancer has been reported to be found in 2% – 7% of surgically treated hyperthyroid patients (1-3). In a large patient population, Sokal stated that there was an incidence of 0.06% thyroid cancer in Graves' disease, while the figure was 0.75% in toxic uni- or multi-nodular goiter (4). In particular, thyroid cancer in Graves' disease has been reported to have a wide range of incidence in different studies. It ranges from no case in Graves' disease patients (1) to as high as 19% in patients with Graves' disease and a cold nodule (5).

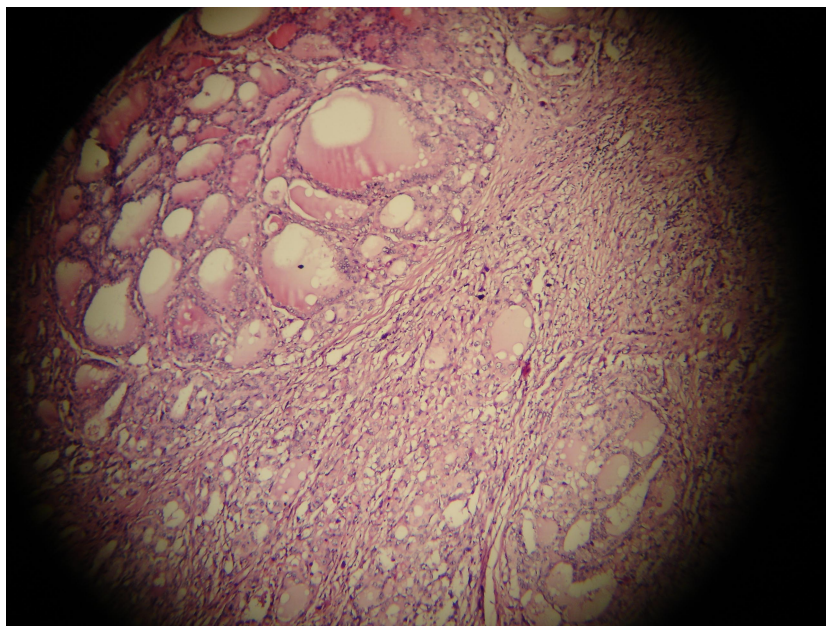


Figure 1. Diffuse infiltrative pattern of follicular cancer and hyperactive thyroid follicles (H&E x100).

Follicular cancer, in particular, has a very low incidence in Graves' disease when compared to papillary thyroid cancer. Some studies have not reported any follicular cancer in patients with Graves' disease (3, 6). Others reported very low occurrence of follicular cancer despite the considerable incidence of papillary cancer in Graves' disease patients (5-7). Radioactive iodine therapy, which has been known to be a risk factor for the development of differentiated thyroid cancer in Graves' disease, has also been reported to lead a very low incidence of follicular cancer (8).

The pathogenic relationship of thyroid cancer with Graves' disease is controversial. Some authors suggest that thyroid stimulating antibodies (TSABs) might have a role in the carcinogenesis in Graves' disease (9, 10). It has also been suggested that TSABs are associated with more

advanced stage and less favorable outcome of differentiated thyroid cancer in Graves' disease patients (10).

We suggest that follicular thyroid cancer as well as papillary cancer should be kept in mind when a Graves' disease patient with nodules is to be operated on, and that the operation of choice should be total thyroidectomy.

Corresponding author:

Mehmet ÖZDOĞAN

Mertler Sok. 41/7 Beştepe

06510 Ankara - Turkey

E-mail: mehmetozdogan01@superonline.com

References

1. Gabriele R, Letizia C, Borghese M et al. A Thyroid cancer in patients with hyperthyroidism. *Horm Res* 60:79-83, 2003.
2. Chou FF, Shee-Chen SM, Chen YS et al. Hyperthyroidism and concurrent thyroid cancer. *Int Surg* 8:343-6, 1993.
3. Kasuga Y, Sugeno A, Kobayashi S et al. The outcome of patients with thyroid carcinoma and Graves' disease. *Surg Today* 23:9-12, 1993.
4. Sokal JE. Incidence of malignancy in toxic and non-toxic nodular goiter. *JAMA* 154:1321-5, 1954.
5. Kraimps JL, Bovin-Pineau MH, Mathonnet M et al. Multicentric study of thyroid nodules in patients with Graves' disease. *Br J Surg* 87:1111-3, 2000.
6. Terzioglu T, Tezelmen S, Onaran Y et al. Concurrent hyperthyroidism and thyroid carcinoma. *Br J Surg* 80:1301-2, 1993.

7. Ozaki O, Ito K, Kobayashi K et al. Thyroid carcinoma in Graves' disease. *World J Surg* 14:437-40, 1990.
8. Ozaki O, Ito K, Mimura T et al. Thyroid carcinoma after radioactive iodine therapy for Graves' disease. *World J Surg* 18:518-21, 1994.
9. Farbota LM, Calandra DM, Lawrence AM et al. Thyroid carcinoma in Graves' disease. *Surgery* 98:1148-53, 1985.
10. Pellegriti G, Belfiore A, Guiffrida D et al. Outcome of differentiated thyroid cancer in Graves' patients. *J Clin Endocrinol Met* 83:2805-9, 1998.