

## Treatment of Periapical Dental Implant Pathology with Guided Bone Regeneration

Tolga Fikret TÖZÜM<sup>1</sup>

Cenk ERDAL<sup>2</sup>

Işıl SAYGUN<sup>2</sup>

**Abstract:** Peri-implantitis is the inflammatory process that takes place around alveolar bone surrounding the dental implant. Unless treated, it may result with the loss of the implant. Another cause of the loss of implant is the periapical implant pathology (PIP). Resective surgical procedures are used in the treatment of PIP, however; this case report will provide information about regenerative applications performed on a dental implant. After the referral of the patient, the surgical debridement followed by bone graft and a resorbable membrane application were performed to complete the surgery. Six months follow-up of the patient who received regenerative treatment, resulted with no symptoms of infection, pain or any discomfort. Regenerative treatment may be an alternative to resective surgical procedures in the treatment of PIP.

**Key Words:** dental implant, peri-implantitis, therapy, apical inflammation

### Yönlendirilmiş Kemik Rejenerasyonu ile Periapikal Dental İmplant Patolojisinin Tedavisi

**Özet:** Peri-implantitis dental implantı çevreleyen alveolar kemiğin marjinal bölgesinde gelişen inflamatuvar bir hastalıktır. Tedavi edilmediği zaman implantın kaybı ile sonuçlanabilmektedir. Dental implantın kaybı ile sonuçlanabilecek diğer bir durum ise periapikal implant patolojisi (PIP). Rezektif cerrahiler PIP tedavisinde kullanılmaktadır, ancak bu vaka raporunda rejeneratif cerrahi işlemler kullanılarak tedavisi gerçekleştirilen dental implant hakkında bilgi verilecektir. PIP teşhisi ile başvuran hastanın dental implantının tedavisi için bölgenin cerrahi debridmanını takiben kemik grefti ve rezorbe olabilen bariyer membran ile cerrahi işlem tamamlanmıştır. Altı aylık takip sonucunda hastada rejeneratif işlem kullanılarak gerçekleştirilen tedavi sonucunda dental implantta herhangi bir enfeksiyon, ağrı yada hasta tarafından belirtilen rahatsızlık olmadığı gözlenmiştir. Rejeneratif cerrahi işlemler PIP tedavisinde rezektif cerrahi tedaviler yerine bir alternatif olabilmektedir.

**Anahtar Sözcükler:** Dental implant, peri-implantit, tedavi, apikal inflamasyon

<sup>1</sup> Department of Periodontology,  
Faculty of Dentistry, Hacettepe  
University, Ankara - TURKEY

<sup>2</sup> Department of Periodontology,  
Gülhane Military Medical Academy,  
Center for Dental Sciences,  
Ankara - TURKEY

### Introduction

A dental implant was successfully integrated when there was direct contact between the alveolar bone and the titanium surface of the implant without a fibrous tissue interface (1-4). Based on this criterion, peri-implantitis is defined as an inflammatory process affecting the tissues around an osseointegrated dental implant that results in the loss of supporting alveolar bone (1-3). In peri-implantitis a crater-shaped bone defect arises in the marginal portion of the dental implant site, and may cause implant failure (1,2). The apical portion of the dental implant may become infected if the marginal infection continues to spread through the apical area of the implant, which causes the loss of osseointegration (1,2,4). As well as peri-implantitis, some other factors also contribute to the loss of a dental implant (2,5,6). Overloading and excessive tightening of the dental implant, fenestration of the vestibular alveolar bone, bone overheating during the surgical procedure, contamination of the dental implant surface, presence of pre-existing bone pathology, pre-existing microbial pathology, and poor alveolar bone quality can result in periapical implant pathology (PIP) (1,7-9). There are a few reports published about PIP, and most of them demonstrated resective surgery. The present case report describes the treatment of PIP with regenerative surgery.

Received: October 25, 2005

Accepted: January 25, 2006

#### Correspondence

Tolga Fikret TÖZÜM  
Department of Periodontology,  
Faculty of Dentistry,  
Hacettepe University, Sıhhiye  
06100 Ankara - TURKEY

ttozum@hacettepe.edu.tr

## Case report

### Patient evaluation

A healthy, 19-year-old Caucasian female patient presented with persistent pain in her left anterior maxillary area that tended to increase in severity. Her dental history revealed that her maxillary lateral incisors were congenitally missing. She had had 2 dental titanium implants replaced 6 months before to treat the sites where the teeth were missing. She had had no problems for 6 months until she had a dull pain located in her left maxillary implant. Clinical evaluation of the right and left implants did not reveal any peri-implant gingival pocketing. However, a slight gingival swelling at the vestibular site was diagnosed during the intra-oral evaluation (Figure 1). The adjacent teeth had no caries or periodontal problems, and they were diagnosed as vital. A radiological evaluation was performed, and a slight radiolucency was found around the apical part of the implant (Figure 2).

### Surgical therapy and follow-up visits

The patient was diagnosed with a periapical dental implant lesion. The possibly of excessive tightening during surgical insertion or the contamination of the apical

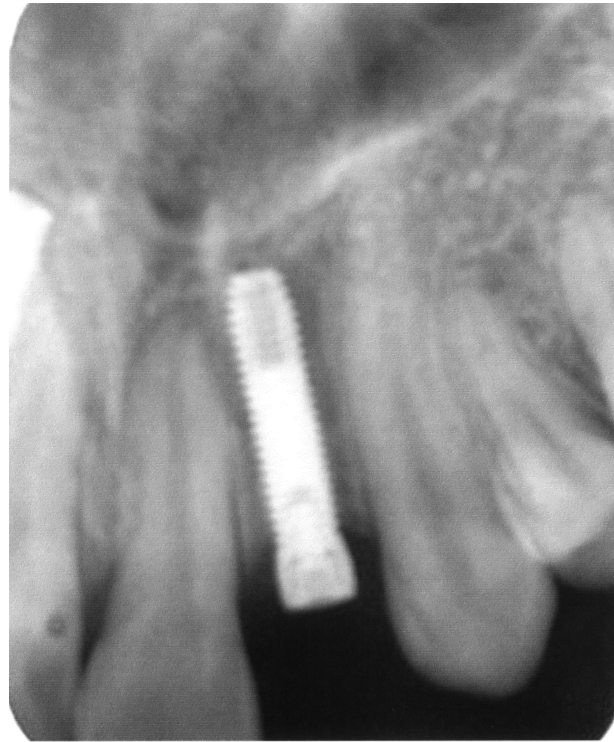

Figure 2. Periapical radiolucency was observed in the apical region of the dental implant.

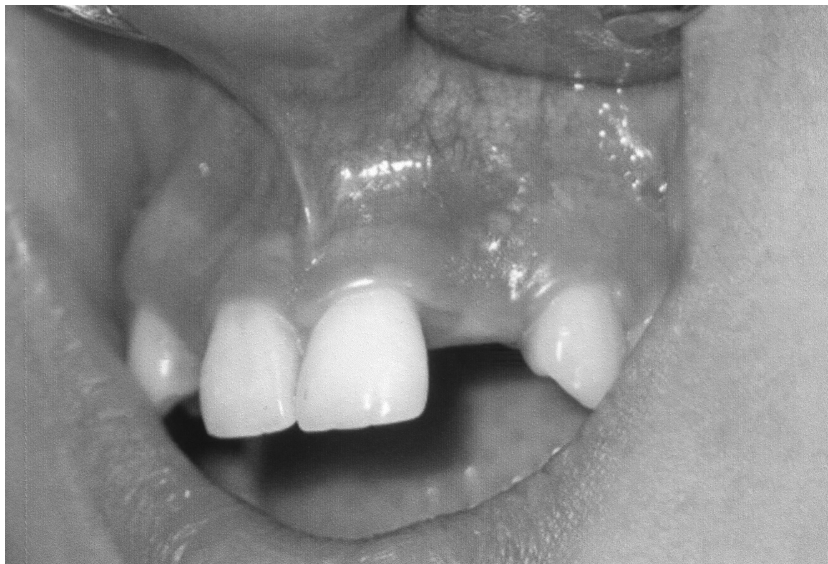

Figure 1. Slight gingival swelling was diagnosed during the intra-oral evaluation.

region of the dental implant was determined as the etiology of PIP. She was given detailed information about the infection and the planned surgical procedure. A full thickness flap was reflected by a sulcular incision followed by vertical releasing incisions. As well as the apical part of the dental implant, the body of the dental implant was also contaminated with infected tissues. All infected fibrous tissues were removed surgically. Interestingly, the dental implant was not mobile (Figure 3). Following debridement, a synthetic resorbable allograft, calcium sulfate (Fortoss Vital, synthetic tri-calcium phosphate in a hydroxyl sulfate matrix, Biocomposites, Wilmington, NC, USA), was packed into the bony defect (Figure 4). A resorbable collagen membrane was placed over the bone substitute (Biomend 15X20, resorbable collagen membrane, Zimmer Dental, Carlsbad, CA, USA) (Figure 5), and wound closure was obtained with 4-0 silk sutures. Following surgery, the patient was given a cold compress extra-orally to minimize swelling and bleeding. She was prescribed 0.2% chlorhexidine gluconate and instructed to rinse gently for 3 weeks. She was also prescribed antibiotics (amoxicillin, 500 mg, 4 times daily) for 10 days. During this time, tooth brushing was

discontinued. Ten days after surgery, the sutures were removed and an uneventful healing was observed. The patient was seen at the 2<sup>nd</sup>, 6<sup>th</sup> and 12<sup>th</sup> weeks, and the 6<sup>th</sup> month. These recall visits included routine intra-oral examinations and professional plaque control. Six months after the surgical procedure, no symptoms of pain, inflammation, or discomfort in the grafted area were noted (Figure 6). Due to significant alveolar bone loss in the apical region of the dental implant and extensive surgical bone augmentation, a final porcelain crown was considered at the end of 12 months of follow-up to achieve successful bone regeneration.

Several factors for PIP have been reported including contamination of the implant, bone overheating during the surgical procedure, excessive tightening of the dental implant, presence of existing microbial pathology, fenestration of the vestibular alveolar bone, and overloading of the dental implant (1,2,8,10,11). For the present case, the possibility of excessive tightening during surgical insertion or contamination of the apical region of the dental implant should be carefully evaluated (7,10).

Sussman reported that PIPs occurred due to the infection of adjacent natural teeth that contaminated the

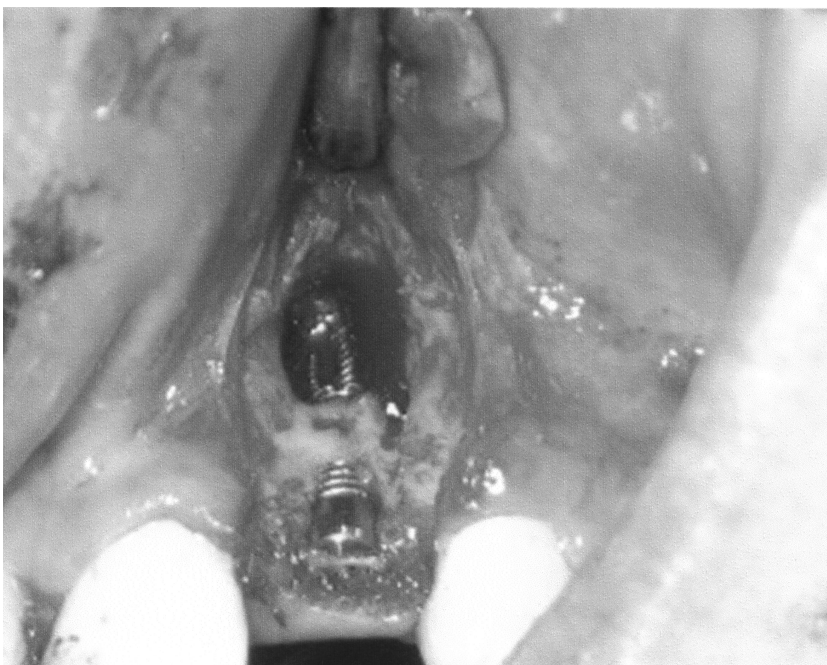

Figure 3. Complete loss of a vestibular alveolar cortical plate with a large periapical defect was noted during surgical debridement.

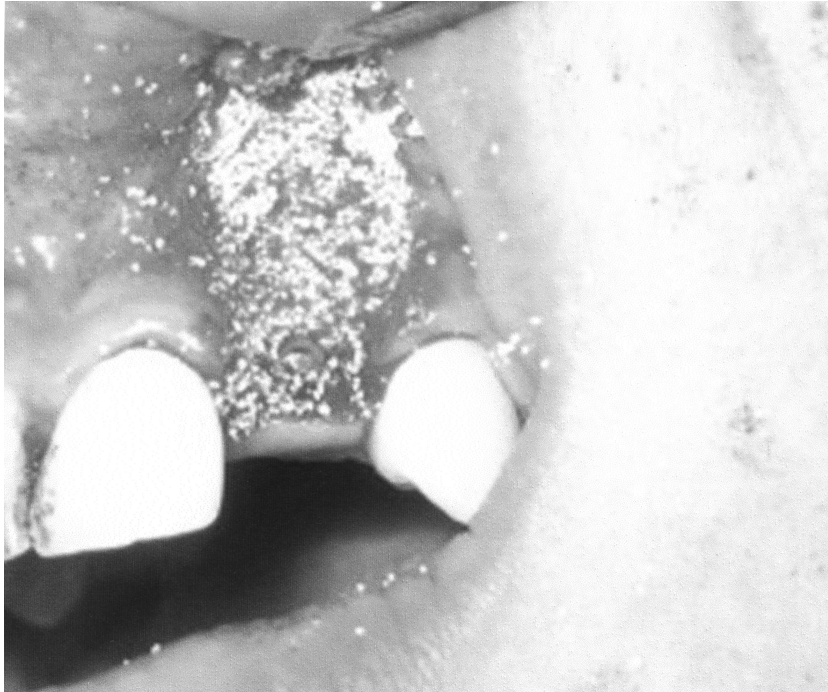

Figure 4. An allograft was applied after the debridement of the bony defect.

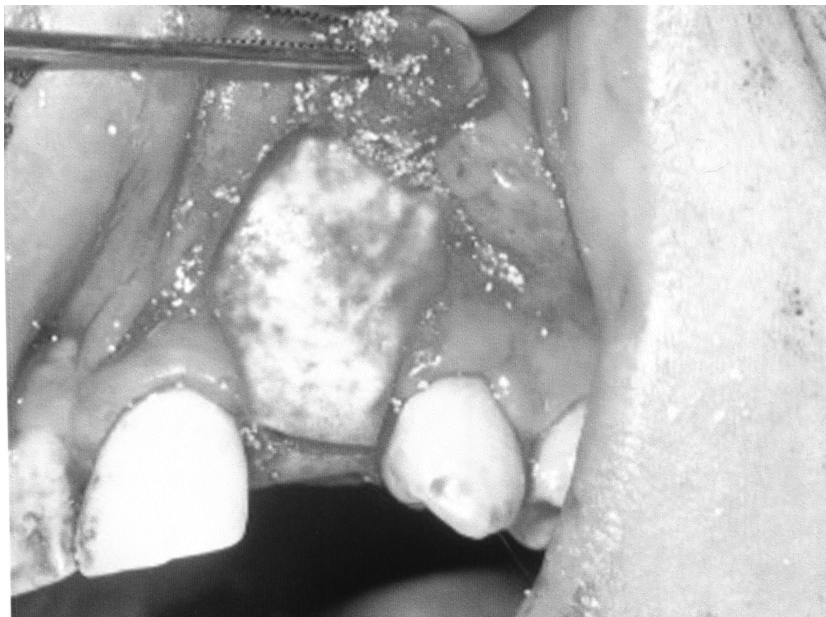


Figure 5. A resorbable collagen membrane was placed over the bone substitute to cover the graft material.

apical part of the dental implant, and although the adjacent natural teeth were endodontically treated, the dental implants were removed (10). Scarano et al. demonstrated that PIP was evaluated at a screw-shaped

mandibular dental implant without any fistula formation, which was diagnosed with computed tomography; however, they could not specifically report the etiologic factor for the formation of PIP (8). As a result, the dental

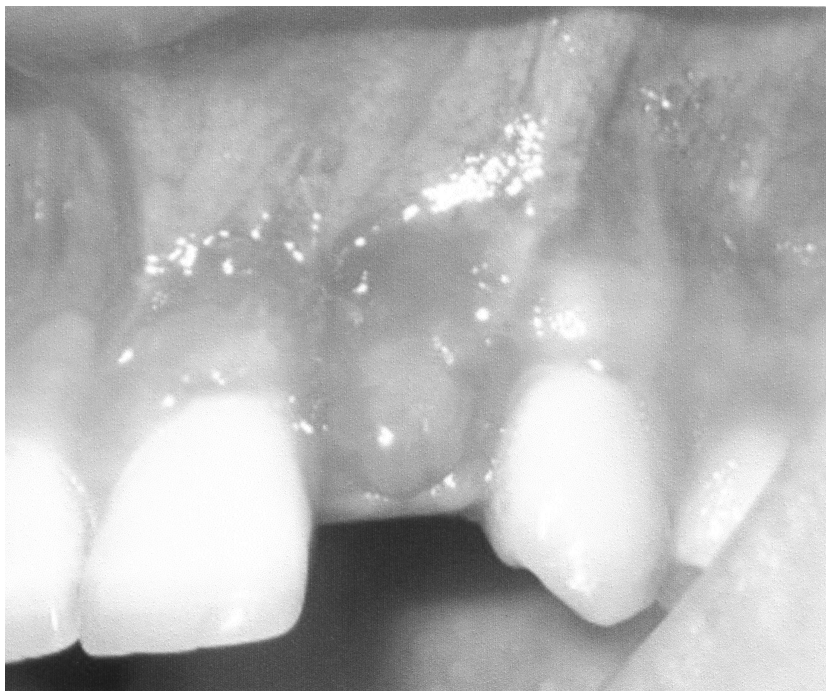

Figure 6. Clinical evaluation demonstrated successful healing 6 months after surgery. The patient reported a successful outcome.

treatment concluded with the surgical removal of the implant (8). Ayangco and Sheridan stated that retrograde peri-implantitis may occur due to implants replacing teeth with histories of failed endodontic and/or dental apicoectomy procedures (12). Oh et al. reported that an implant was lost due to a periapical implant lesion, which formed 3 months after surgery, and the authors reported that the furcation involvement at the adjacent natural tooth was the possible etiology (11). It was also suggested that surgical procedures including the removal or the resection of the infective dental implant should be performed to avoid osteomyelitis (13), and surgical

removal of the dental implants should be performed whether the implants were mobile or not (10,11). However, based on current knowledge, the surgical removal or the resection of the apical portion of the implant should be avoided.

In conclusion, 6 months post-surgery uneventful healing was observed without the removal or the loss of the dental implant, and the patient reported a highly successful outcome. Clinical and radiological evaluations demonstrated successful healing. This report underlines the importance of regenerative surgery instead of resective/removal surgery.

## References

1. Ross-Jansaker A-M, Renvert S, Egelberg J. Treatment of peri-implant infections: A literature review. *J Clin Periodontol* 2003; 30: 467-485.
2. Klinge B, Gustafsson A, Berglundh T. A systematic review of the effect of anti-infective therapy in the treatment of peri-implantitis. *J Clin Periodontol* 2002; 29 (Suppl 3): 213-225.
3. Coulthard P, Esposito M, Slater M et al. Prevention. Part 5: Preventive strategies for patients requiring osseointegrated oral implant treatment. *Brit Dent J* 2003; 195: 187-194.
4. Ashley ET, Covington LL, Bishop BG et al. Ailing and failing endosseous dental implants: A literature review. *J Contemp Dent Pract* 2003; 4: 35-50.
5. Jaffin RA, Berman CL. The excessive loss of Branemark fixtures in type IV bone. *J Periodontol* 1991; 62: 4.
6. Esposito M, Hirsh J, Lekholm U et al. Differential diagnosis and treatment strategies for biologic complication and failing oral implants. *Int J Oral Maxillofac Implants* 1999; 14: 473-490.

7. Sussman HI. Implant pathology associated with loss of periapical seal of adjacent tooth: Clinical report. *Implant Dent* 1997; 6: 33-37.
8. Scarano A, Domizio PD, Petrone G et al. Implant periapical lesion: A clinical and histological case report. *J Oral Implantol* 2000; 26: 109-113.
9. Flanagan D. Apical (Retrograde) peri-implantitis: A case report of an active lesion. *J Oral Implantol* 2002; 28: 92-96.
10. Sussman HI. Periapical implant pathology. *J Oral Implantol* 1998; 24: 133-138.
11. Oh TJ, Yoon J, Wang HL. Management of the implant periapical lesion: A case report. *Implant Dent* 2003; 12: 41-46.
12. Ayangco L, Sheridan PJ. Development and treatment of retrograde peri-implantitis involving a site with a history of failed endodontic and apicoectomy procedures: a series of reports. *Int J Oral Maxillofac Implants* 2001; 16: 412-417.
13. Reiser GM, Nevins M. The periapical lesion: Etiology, prevention and treatment. *Compendium* 1995; 16: 768-777.