

Gastrointestinal Basidiobolomycosis as a Rare Etiology of Bowel Obstruction

Alireza FAHIMZAD¹

Abdollah KARIMI²

Sedigheh Rafiee TABATABAEI³

Mahbubeh Gerami ZADEH⁴

Abstract: Basidiobolomycosis is an unusual fungal infection that manifests in the skin and rarely involves the gastrointestinal tract. Gastrointestinal Basidiobolomycosis is rarely reported in the medical literature. We report a 1.5-year-old boy from the south of Iran with bowel obstruction which was diagnosed as gastrointestinal Basidiobolomycosis.

Key Words: Basidiobolomycosis, bowel obstruction, fungal infection, children

Barsak Tıkanmasının Nadir Bir Nedeni: Gastrointestinal Basidiobolomycosis

Özet: Basidiobolomycosis deride çok nadir görülen bir mantar enfeksiyonudur ve nadiren sindirim sistemini de tutabilir. Gastrointestinal Basidiobolomycosis tıbbi literatürde de nadiren bildirilmiştir. İran'ın güneyinde barsak tıkanıklığı ile başvuran ve gastrointestinal Basidiobolomycosis olan 1,5 yaşındaki bir hastayı rapor ediyoruz.

Anahtar Sözcükler: Basidiobolomycosis, barsak tıkanması, mantar enfeksiyonu, çocuk

¹ Assistant Professor of Pediatric Infectious Diseases, Faculty of Medicine, Shaheed Beheshti University of Medical Sciences, Tehran, IRAN

² Professor of Pediatric Infectious Diseases, Faculty of Medicine, Shaheed Beheshti University of Medical Sciences, Tehran, IRAN

³ Assistant Professor of Pediatrics, Pediatric Infectious Research Center, Shaheed Beheshti University of Medical Sciences, Tehran, IRAN

⁴ Associate Professor of Pathology, Faculty of Medicine, Shiraz University of Medical Sciences, Shiraz, IRAN

Introduction

Basidiobolomycosis is a rare fungal infection caused by *Basidiobolus ranarum*, an environmental saprophyte found worldwide (1). *B. ranarum* is a member of the order *Entomophthorales* of the class *Zygomycetes* (2).

Basidiobolomycosis is usually a subcutaneous infection that affects mostly young males, and it is transmitted through traumatic inoculation. Most cases have been reported from tropical and subtropical regions (1,3). While the diagnosis of subcutaneous disease is easy, the diagnosis of gastrointestinal basidiobolomycosis is more difficult and its clinical presentation is nonspecific with no identifiable risk factors (4).

A 1.5-year-old boy from the south of Iran (Kerman province) who had no remarkable medical history presented with abdominal pain, fever, diarrhea and hematochezia, and was referred to our hospital with bowel obstruction.

According to the clinical and histopathologic findings of septate hyphal elements, basidiobolomycosis was diagnosed.

Case Report

A previously healthy 1.5-year-old boy from Jiroft city of Kerman province was referred with a two-month history of diarrhea, abdominal pain, tenesmus, and hematochezia, with no response to antibiotic therapy for dysentery. Colonoscopy revealed irregular polypoid lesions with superficial hemorrhage in rectal epithelium, but pathology showed nonspecific inflammatory lesion with granuloma formation. He had spontaneous remission and was discharged with undetermined diagnosis.

Received: April 04, 2006
Accepted: August 10, 2006

Correspondence

Alireza FAHIMZAD
Pediatric Infectious Research
Center,
Mofid Children's Hospital,
Shariati St., Tehran, IRAN

info@pedirc.org
safahimzad@yahoo.com

One month later he was admitted with picture of bowel obstruction and bladder retention to the surgical ward of Namazi Hospital of Shiraz University. Pelvic CT scan showed an annular mass (5 x 5 cm in diameter) with pressure effect on rectum and bladder.

In diagnostic laparotomy, 95% of the mass was resected and proximal colostomy was done. Pathology revealed numerous granulomatous type foreign bodies with prominent eosinophilic infiltration and a few broad septate fungal elements (Figure 1).

Three weeks after relief of symptoms, he was referred to our hospital because of fever with firm and tender swelling on his left buttock, and he was unable to sit. Complete blood count (CBC) showed leukocytosis with eosinophilia and elevated erythrocyte sedimentation rate (ESR) (ESR = 80).

Based on clinical manifestations (relapse of fever and inflammatory rectal mass), laboratory findings (eosinophilia and elevated ESR), and characteristic broad septate fungal elements with granuloma in pathology, gastrointestinal basidiobolomycosis was diagnosed. One week after prescription of amphotericin B, fever and buttock swelling had subsided and he was discharged with oral itraconazole for nine months. In regular follow-up, his condition was perfect with no complication.

Discussion

Basidiobolus ranarum was first isolated in 1955 from decaying plants in the United States and subsequently has been found in soil and vegetations throughout the world (5). *B. ranarum* is sometimes present as a commensal in the intestinal tracts of frogs, toads, turtles, chameleons, horses and dogs (6).

Subcutaneous mycosis was recognized as the first human case in Indonesia in 1956 (7). In 1978, the first culture proving invasive basidiobolomycosis of the maxillary sinus and palate was reported in the United States (8).

There are only 21 case reports of gastrointestinal basidiobolomycosis in the literature: 8 from the United States, 6 from Saudi Arabia, 4 from Brazil, 2 from Nigeria, and 1 from Kuwait (9). All patients had abdominal pain and fever as their main symptoms, as in our case, with no response to conventional therapy.

In the above-mentioned cases, intraabdominal masses were found on imaging studies and during surgical exploration, consistent with either malignancy or inflammation. But histopathologic tests revealed inflammatory changes with many eosinophils (10), and broad pleomorphic, sparsely septated hyphae on silver staining (1,11). On hematoxylin and eosin staining, the

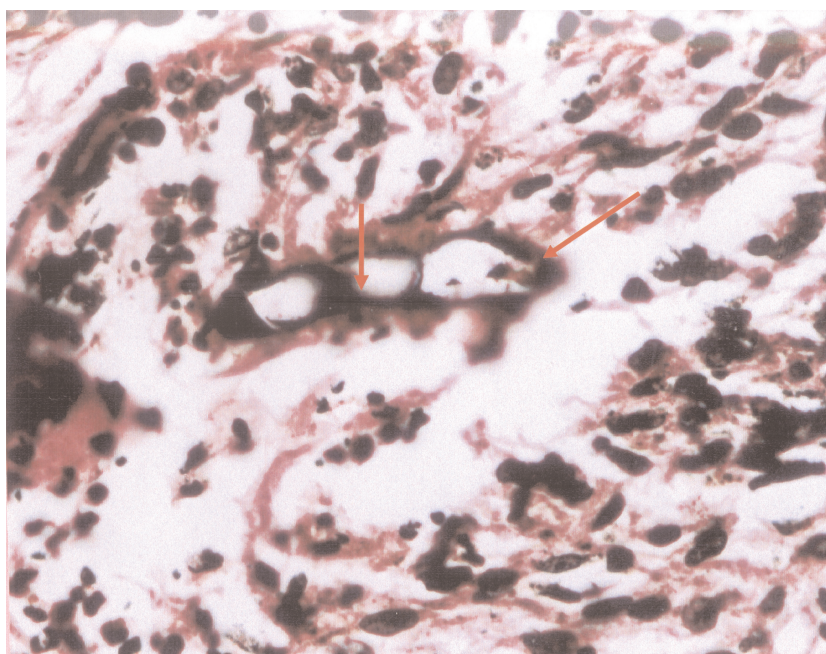


Figure. Broad septate fungal element.

fungal elements often appear as empty spaces surrounded by an intensely staining eosinophilic material (Splendore-Hoeppli phenomenon (1,11). Leukocytosis, marked eosinophilia, and elevated ESR and CRP were found in our case as in the other reported cases (10,12). The main differential diagnosis of gastrointestinal basidiobolomycosis with granuloma are inflammatory bowel disease (IBD) (Crohn disease), intestinal TB, sarcoidosis and amebiasis (13). Because of the nonspecific signs and symptoms of this disease, the diagnosis has been delayed with more morbidity.

It is unclear how the fungus is introduced into the host's gastrointestinal tract, but this probably occurs through ingestion of contaminated soil, animal feces or food.

On the basis of the limited information available from a review of the literature, it appears that optimal treatment of gastrointestinal basidiobolomycosis is combined surgical and prolonged medical treatment. The best choice of antifungal agent is not clear, but itraconazole seems to be reasonable (14). Clinical failure has been described with amphotericin B. Potassium iodide (KI) has been used successfully for treatment of subcutaneous basidiobolomycosis (15).

In conclusion, gastrointestinal basidiobolomycosis is an emerging infection that leads to diagnostic confusion, morbidity and mortality. Diagnosis of this disease requires high index of suspicion, awareness and consideration of its possibility in the differential diagnosis of patients with abdominal masses and eosinophilia.

References

1. Kwon-Chung KJ, Bennett JE. Medical mycology. Philadelphia: Lea & Febiger; 1992.
2. De Leon-Bojorge B, Ruiz-Maldonado R, Lopez-Martinez R. A clinicopathologic and mycology study in a child. *Ped Dermatology* 1988; 5: 33-36.
3. Antonelli M, Vignette P, Dahir M et al. Entomophthoromycosis due to *Basidiobolus* in Somalia. *Trans R Soc Trop Med Hyg* 1987; 81: 186-187.
4. Khan ZU, Khourheed M, Makar R et al. *Basidiobolus ranarum* as an etiologic agent of GI zygomycosis. *J Clin Microbiol* 2001; 39: 2360-2363.
5. Geer DL, Friedman L. Studies on the genus *Basidiobolus* with recalcification on the species pathogenic to man. *Sabouroudia* 1966; 4: 231-241.
6. Zahar P, Hirst RG, Shipton WA, Campbell RS. The origin and pathogenicity of *Basidiobolus* species in Northern Australia. *J Med Vet Mycol* 1990; 28: 461-468.
7. Joe L, Eng NIT, Phan A et al. *Basidiobolus ranarum* as a cause of subcutaneous mycosis in Indonesia. *Arch Dermatol* 1956; 74: 378-383.
8. Dworzack DL, Pollok AS, Hodges GR, Barnes WG, Ajello L. Zygomycosis of the maxillary sinus and palate caused by *Basidiobolus haptosporus*. *Arch Intern Med* 1978; 138: 1274-1276.
9. Al Jarie A, Al-Mohsen I, Al Jumaah S et al. Pediatric gastrointestinal basidiobolomycosis. *Ped Infect Dis J* 2003; 22: 1007-1013.
10. Wardlaw AJ, Kay AB. Eosinopenia and eosinophilia. In: Beutler E, Lichtman MA, Coller BS, Kipps TJ, editors. *Williams Hematology*. New York: McGraw Hill: 1995. pp: 844-852.
11. Yosef AM, Smilack JD, Kerr DM et al. Gastrointestinal basidiobolomycosis. Morphologic finding, in a cluster of six cases. *Am J Clin Path* 1999; 112: 610-616.
12. Lyon GM, Smilack JD, Komatsu KK et al. Gastrointestinal basidiobolomycosis in Arizona: clinical and epidemiological characteristics and review of the literature. *CID* 2001; 32: 1448-1455.
13. Rbes JA, Vanover Sams CL, Boleer DJ. Zygomycetes in human disease. *Clin Microbiol* 2000; 13: 236-301.
14. Drouhet E, Dupont B. Laboratory and clinical assessment of ketoconazole in deep seated mycosis. *Am J Med* 1983; 74: 30-46.
15. Nazir Z, Hassan R, Pervaiz S, Alam M, Moozom F. Invasive retroperitoneal infection due to *Basidiobolus ranarum* and response to potassium iodide - case report and review. *Ann Trop Perior* 1997; 17: 161-164.