

A Selective Ideational Apraxic Agraphia for Consonants

Serpil DEMİRCİ

Department of Neurology, Faculty of
Medicine, Süleyman Demirel
University, Isparta - TURKEY

Aim: The proposed graphemic area in the dominant hemisphere contains letter representations that are responsible for guiding the skilled movements required for writing and for recognition of the physical features of letters. Dysfunction in this system may cause apraxic agraphia. In this study, writing performance of a right-handed, left hemisphere damaged, 12-year old apraxic agraphic patient with a native language of shallow orthography is analysed.

Methods: Writing performance was evaluated with several different word lists, each holding same amount of letters, novel words (non-word), words, functors, and high-imagery and low-imagery words. Non-words were derived from words by changing a single letter.

Results: A selective writing impairment limited to the left hand was observed. Her deficit was graphemic in nature; she made no phonological errors during spontaneous speech and oral naming. Writing was not affected by lexical factors (grammatical class, word length, or abstract quality) or lexicality (word, non-word, functor). In the entire corpus of responses, she wrote 2 of 154 vowel letters (1.3%) and 51 of 232 consonant letters (22.0%) incorrectly.

Conclusions: It is proposed that the corpus callosum carries the interhemispheric control of praxis and writing at different levels, praxis for writing carried separately from praxis in general and within praxis for writing vowels and consonants are handled separately.

Key Words: Agraphia, apraxia, corpus callosum

Ünsüz Harfler İçin Seçici Ideasyonel Apraksik Agraphi

Amaç: Dominant hemisferde olduğu varsayılan grafemik alan yazı yazmak için gereken hareket ve harflerin fiziksel özelliklerini tanımak için gerekli harf imgelerini içerir. Bu sistemdeki bozukluk apraksik agraphiye neden olur. Bu çalışmada, anadili yazım-sesletim benzer dillerden olan 12 yaşındaki sağ el tercihli, sol hemisfer hasarlı, apraksik agraphili bir hastanın yazı yazma performansı incelenmiştir.

Yöntem: Yazı performansı her biri eşit sayıda harf, anlamsız sözcük, sözcük, bağlaç, soyut ve somut sözcük içeren birkaç sözcük listesi ile değerlendirildi. Anlamsız sözcükler, sözcüklerde harf değişikliği yapılarak oluşturuldu.

Bulgular: Hastada sol ele sınırlı selektif yazı bozukluğu vardı. Spontan konuşma ve isimlendirme sırasında yanlışların eşlik etmediği grafemik bozukluk izlendi. Yazım leksikal faktörler (gramatik sınıf, sözcük uzunluğu, soyutluk niteliği) ve leksikalite (sözcük, anlamsız sözcük, sözcük türü) ile ilgili değildi. Yanıtların tümü değerlendirildiğinde 154 ünlü harften ikisini (%1,3) ve 232 ünsüz harften ellibirini (%22,0) yanlış yazmıştı.

Sonuç: Korpus kallozumun praksi ve yazmanın interhemisferik kontrolünü farklı seviyelerde yaptığı, yazı praksisine ait bilginin genel praksiden farklı olarak iletildiği ve yazı becerisi için sesli ve sessiz harflerin ayrı ayrı ele alındığı söylenebilir.

Anahtar Sözcükler: Agraphi, apraksi, korpus kallozum

Received: June 15 2005
Accepted: May 22, 2006

Introduction

It is assumed that the graphemic area in the dominant hemisphere contains letter representations that are responsible for guiding the skilled movements required for writing and for recognition of the physical features of letters (1). Dysfunction in this system may cause apraxic agraphia (2). Liepmann and Maas originally observed and reported apraxia and agraphia of the nondominant hand. They proposed that connections from left to right motor regions via the anterior portion of the callosum are necessary for cortical control of the nondominant hand for the guidance of movements in response to verbal command (3). Agraphia without apraxia has also been observed following lesions in the body of the callosum (4,5).

Correspondence

Serpil DEMİRCİ
Department of Neurology
Faculty of Medicine
Süleyman Demirel University,
32260 Isparta - TURKEY
serpildemirci@hotmail.com
sdemirci@med.sdu.edu.tr

This report describes the spelling performance of an apraxic agraphic patient who displayed errors that almost exclusively involved consonant letters.

Case Report

The patient was a 12-year-old, right-handed girl who suffered from a right hemiparesis after a road traffic accident one year previously. After the accident, she was aphasic but could communicate with gestures, and auditory verbal comprehension was good. Her aphasia resolved, but the hemiparesis interfered with her use of the right hand, and she began to write with her left hand.

Initial neurological examination revealed a right upper motor neuron facial paresis with a severe spastic right hemiparesis. She had no bucco-facial or limb apraxia; and performed all gestural movements, transitive and intransitive, correctly to spoken and written commands. She also had no disturbance of elementary tactile function; she named all the objects placed in the left hand while blindfolded. Cranial magnetic resonance scanning demonstrated a cystic lesion secondary to old hemorrhage at the level of basal ganglia involving caudate and lentiform nuclei and the internal capsule in the left hemisphere (Figure 1a).

Language was assessed with the GATA- Aphasia test (6). Speech was grammatical and fluent without paraphasic errors. Her performance was comparable to that of adults except for writing. She made errors on spontaneous and dictated writing whereas copying written material was flawless. For detailed evaluation of the writing performance, the patient was given several different word lists. Each list held same amount of letters, novel words (non-word), words, functors, and high-imagery and low-imagery words. Non-words were derived from words by changing a single letter. She was asked to spell, write to dictation with left and right hand and copy the given letters and words. She read, repeated and copied the word lists without any mistakes. However, correctly spelled aloud words were written wrongly to dictation. Her errors were remarkable for consonant letters. When she was asked to write again, she made the same errors. When asked to write with her right hand the same words were spelled correctly. She recognized her errors when asked to read what she wrote and tried to correct them. Writing only single letters or digits and drawing from memory was flawless. Naming and selecting letters from an array was perfect.

The patient showed a selective writing impairment limited to the left hand. Her deficit was graphemic in

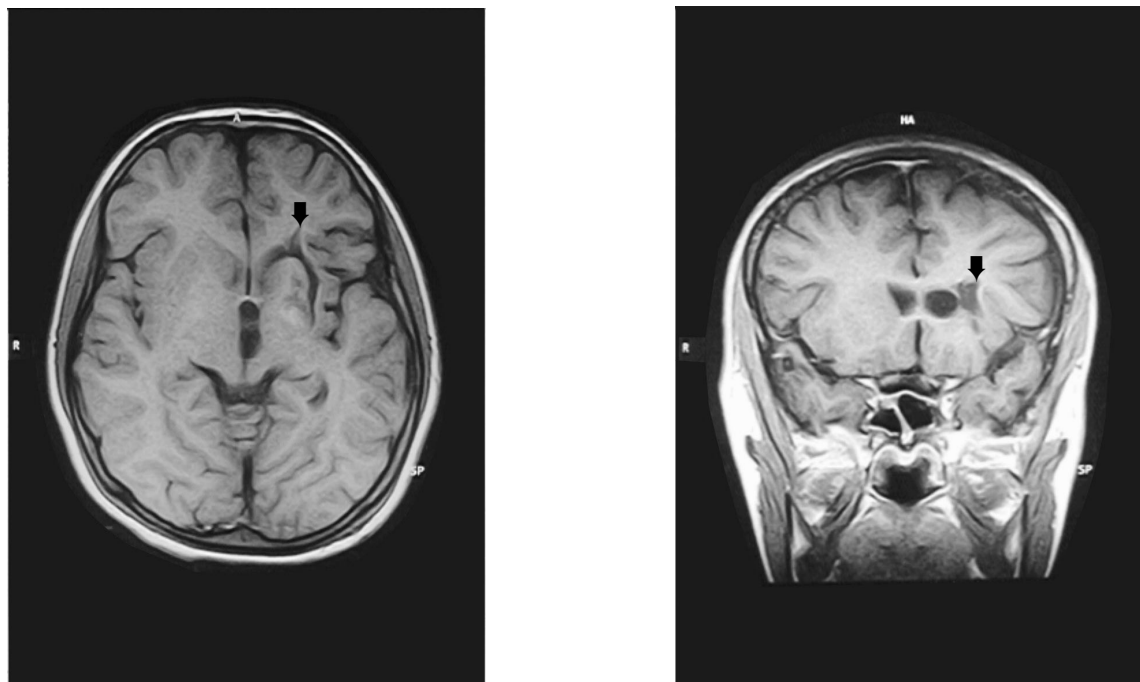


Figure 1a. Axial and coronal T1-weighted MR scans show a cystic lesion involving left internal capsule, caudate and lentiform nuclei (black arrows).

nature; she made no phonological errors during spontaneous speech and oral naming. Writing was not affected by lexical factors (grammatical class, word length, or abstract quality) or lexicality (word, non-word, functor). In the entire corpus of responses, she wrote 2 of 154 vowel letters (1.3%) and 51 of 232 consonant letters (22.0%) incorrectly. Almost all of her errors were letter substitution but she also made transposition and deletion errors (Figure 1b). All her errors involved consonant letters and she substituted consonant letters for consonant letters in every case.

Discussion

Writing requires a series of sequential stages. At first, each word is transformed into abstract letters by phonological and lexical routes. These abstract representations are computed and temporarily stored to be converted in a verbal code by the letter name conversion mechanisms if the word is to be spelled aloud and to a physical letter code by the allographic conversion mechanisms if the word is to be written. During the allographic processing, each grapheme is transformed









	Left Hand	Right Hand
hamur (dough)	gamor	
yalan (lie)	aklan	
maymun (monkey)	paymun May bon	
çengel (hook)	şengel	
böylece (so)	Möylece	
		

Figure 1b. Examples of patient's writing to dictation with the left and right hand, and spontaneous drawings.

into allographic forms according to the context and the position of the letter in the string and then one of the allographic forms are chosen and converted into a motor plan (7,8).

This report described the spelling performance of a patient with a selective deficit in writing consonants in the presence of normal speech, reading and oral spelling ability. The performance of the patient is indicative of a specific deficit of the graphemic buffer and/or allographic store. However, if the lesion were in the graphemic buffer and/or in the allographic store, which are proposed to be located in the dominant parietal lobe; the patient would be expected to produce similar writing errors with the right-hand, since the control of both hands would be affected. However, writing performance with the right hand was completely correct, though affected by the spasticity. This suggests a normal flow of information from the dominant parietal lobe to the dominant motor regions; and an abnormal one for left-hand writing from left dominant parietal area to right motor regions. The remarkable dissociation between the two hands implies a disconnection between the two hemispheres in transporting the normally computed identity of letters. The dissociation between copying and writing to dictation was also remarkable. Thus she was capable of executing the appropriate movement patterns when copying but unable to execute them without a model, especially for consonants. Regarding this peculiarity, the patient can be said to have a very selective ideational apraxic agraphia.

Evaluating the writing ability in both hands of agraphic aphasics with hemiplegia, Leischner (9) observed that performance when writing to dictation was superior with the paralysed arm. He termed this phenomenon graphic disconnection syndrome, supposedly caused by intersection of the path between the graphic region of the dominant hemisphere and the corpus callosum.

The most likely explanation in the presented patient is that the lesion in the left hemisphere severed the commissural fibers between dominant hemisphere's graphic region and the callosum, interfering with the praxic command of the left hand.

It might be thought that a low education level might have caused these errors, however, Turkish is a language with a shallow orthography, where the subword-level routine is sufficient for words to be written. The phonological-to-orthographic conversion rules are simple with a one-to-one correspondence between sound and letter for both vowels and consonants, and it is less likely to produce so many definite errors. Furthermore, the patient was reported not to have made such errors prior to the accident.

Cubelli reported a selective writing deficit for vowels (10). In a similar vein, the patient presented here had a selective deficit for only consonants. These findings suggest that consonant/vowel information of graphemic representations is transferred separately by commissural fibers of corpus callosum. It is concluded that praxis for writing is carried separately from praxis in general and within praxis for writing, vowels and consonants are handled separately.

References

1. Rothi L, Heilman KM. Alexia and agraphia with spared spelling and letter recognition abilities. *Brain Lang* 1981; 12(1): 1-13.
2. Crary MA, Heilman KM. Letter imagery deficits in a case of pure apraxic agraphia. *Brain Lang* 1988; 34(1): 147-156.
3. Liepmann H, Maas O. Fall von linksseitiger: Agraphie und Apraxie bei rechtsseitiger Lahmung. *J Psychol Neurologie* 1907; 10: 214.
4. Gersh F, Damasio AR. Praxis and writing of the left hand may be served by different callosal pathways. *Arch Neurol* 1981; 38(10): 634-636.
5. Sugishita M, Toyokura Y, Yoshioka M, Yamada R. Unilateral agraphia after section of the posterior half of the truncus of the corpus callosum. *Brain Lang* 1980; 9(2) :215-225.
6. Tanrıdağ O. Afazi, 3rd ed. İstanbul: Nobel Tıp Kitabevleri; 1987.
7. Caramazza A, Miceli G, Villa G, Romani C. The role of the graphemic buffer in spelling: evidence from a case of acquired dysgraphia. *Cognition* 1987; 26(1): 59-85.
8. Caramazza A, Miceli G. The structure of graphemic representations. *Cognition* 1990; 37(3): 243-297.
9. Leischner A. Das graphische disconnections-syndrome. *Eur Arch Psychiatr Neurol Sci* 1984; 234(2) :125-136.
10. Cubelli R. A selective deficit for writing vowels in acquired dysgraphia. *Nature* 1991; 353(6341): 258-260.