

Hepatic Failure as a Result of Ovarian Cysts in a Newborn

Aşkın GÜRA¹

Güngör KARAGÜZEL²

Metin ÇUBUK³

Nihal OYGUR¹

Abstract: The ovarian cyst is the most common intra-abdominal cystic lesion in the female neonate. Several authors have reported complications caused by compression of cysts on other viscera. We present a neonate with acute transient hepatic failure due to the compression of ovarian cysts on the liver.

Key Words: Ovarian cyst, newborn, hepatic failure

Yeni Doğanda Over Kistine Bağlı Karaciğer Yetmezliği

Özet: Over kistleri, yenidoğan kız bebeklerde en sık rastlanan intraabdominal kistlerdir. Literatürde bu kistlerin diğer organlara bası yaparak komplikasyonlara neden olduğunu bildiren yayınlar bulunmaktadır. Bu çalışmada over kistinin karaciğere basısı sonucu akut karaciğer yetmezliği tablosu gelişen bir yenidoğan olgu sunulmuştur.

Anahtar Sözcükler: over kisti, yenidoğan, karaciğer yetmezliği

¹ Department of Pediatrics,
Division of Neonatology,
Akdeniz University,
Faculty of Medicine,
Antalya - TURKEY

² Department of Pediatric Surgery,
Akdeniz University,
Faculty of Medicine,
Antalya - TURKEY

³ Department of Radiology,
Akdeniz University,
Faculty of Medicine,
Antalya - TURKEY

Introduction

The ovarian cyst is the most common intra-abdominal cystic lesion in the female neonate (1). The majority of ovarian cysts are asymptomatic. They may present with a palpable mass as an incidental finding, or some neonates may have symptoms of rupture, torsion and hemorrhage, compression on other viscera (bowel obstruction, thorax compression with pulmonary hypoplasia, urinary tract obstruction, incarceration within an inguinal hernia, polyhydramnios) or adhesions (2,3,4). Torsion and hemorrhage are the most frequent complications. We report a neonate with transient hepatic failure resulting from the mass effect of ovarian cysts.

Case Report

The female infant was born to a G1, 23-year-old healthy mother at 34 weeks of gestation by cesarean section with a birth weight of 3095 g. Antenatal sonography at 30 weeks of gestation showed a cystic mass in the abdomen of the fetus. At birth, her Apgar scores were 7 and 8 at 1 and 5 min, respectively. The neonate was transferred to the Neonatal Intensive Care Unit (NICU) because of marked generalized edema and respiratory distress. She was immediately intubated and ventilated. On admission her abdomen was enlarged by a palpable mass and ascites (Figure 1). The spleen was not palpable. There was mild pleural and pericardial effusion on chest X-ray. Although no abnormalities were detected on lung parenchyma, the diaphragm was pushed upwards on both sides due to compression by the large abdominal mass. Results of initial laboratory examination were: leukocyte count $47.3 \times 10^9/L$ (segmented neutrophils 60%, lymphocytes 34%, monocytes 2%, eosinophils 4%), NRBC 80%, hemoglobin 18.1 g/L, platelet count $215 \times 10^9/L$, direct Coombs (-), C-reactive protein (CRP) 0.15 mg/L, aspartate aminotransferase (AST) 434 U/L, alanine aminotransferase (ALT) 105 U/L,

Received: October 04, 2005

Accepted: October 11, 2006

Correspondence

Aşkın GÜRA

Akdeniz University, Faculty of
Medicine, Department of Pedi-
atrics, Division of Neonatology,
07070 Antalya - TURKEY

askin.gura@gmail.com

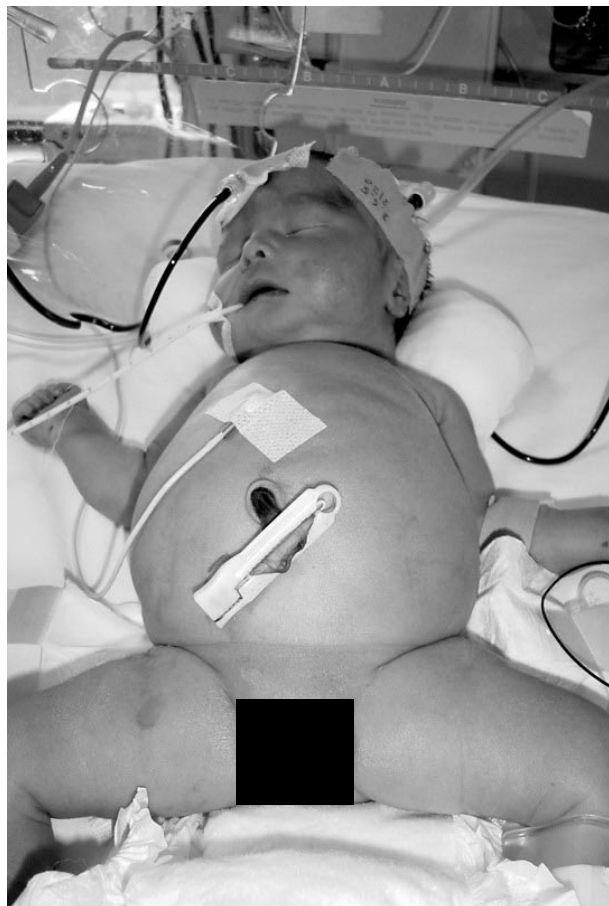

Figure 1. Abdominal distention and generalized edema of patient.

total bilirubin 3.5 mg/dl and direct bilirubin 0.1 mg/dl, gamma glutamyl transferase (GGT) 91 U/L, lactate dehydrogenase 5368 IU/L, alkaline phosphatase 290 IU/L, total protein 3.3 g/L, albumin 2.3 g/L, glucose 15 mmol/L, sodium 132 mmol/L, potassium 4 mmol/L, creatinine phosphokinase 1137 U/L, BUN 34 mg/dl, and creatinine 1.2 mg/dl. Both prothrombin time (PT) and activated partial thromboplastin time (aPTT) were normal; blood gas analysis revealed mixed acidosis. Ultrasound examination of the abdomen revealed ascites and three cystic lesions. Computerized tomography of the abdomen was performed to confirm ultrasonographic findings and showed three cystic lesions measuring 2x3cm, 6x6cm and 5x6cm filling the abdominal and pelvic area with septae and no internal echoes or calcification suggesting mesenteric, omental or ovarian cysts (Figure 2). However, on her 3rd day of life, worsening of hepatic function was observed with the following laboratory values: AST 3185 U/L, ALT 519 U/L, GGT 116 U/L, total protein 3.5 g/L, albumin 1.8 g/L and prolonged PT and aPTT. Infectious, metabolic and toxic causes of neonatal liver failure were excluded. Liver Doppler ultrasonography showed evidence of reduction in hepatic blood flow. Despite aggressive ventilatory support, her respiratory status progressively worsened and paracentesis was performed to improve pulmonary

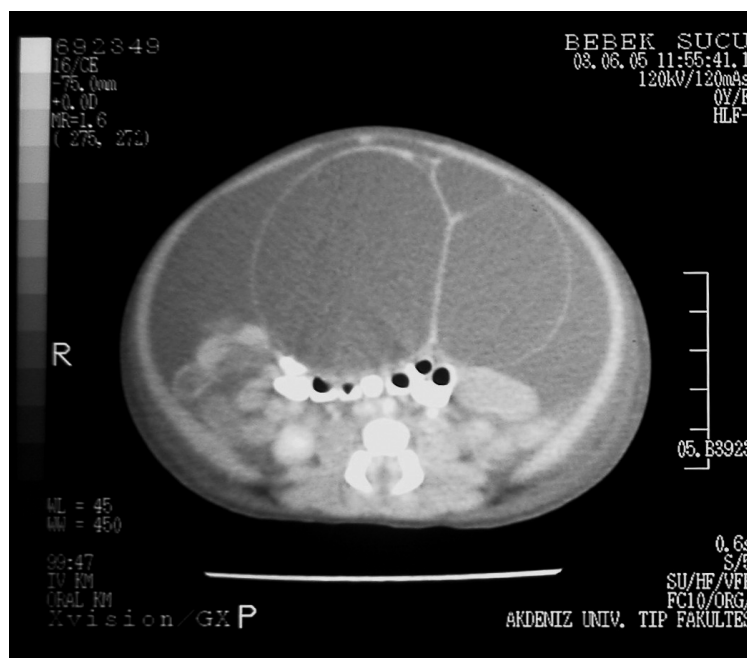

Figure 2. CT scan appearance of ovarian cysts.

function; 80 ml of fluid with the characteristic laboratory findings of transudate was drained. The patient also received albumin infusions for the treatment of edema, oliguria and hypotension. Thereafter, edema recovered dramatically, hepatic enzyme values returned to normal in two days, hemodynamic condition improved rapidly and she was extubated successfully. On the 12th day of hospitalization, laparotomy was performed and a huge cyst arising from the right ovary, lying between the antrum of stomach and pelvic region, was detected. There was no healthy ovarian tissue on the right side but the left ovary was normal (Figure 3). The cyst was completely removed. Pathologic examination was consistent with three follicular ovarian cysts measuring 3x4cm, 7x6cm and 4x5cm. The baby had an uneventful recovery and could be discharged in good clinical condition one week later.

Discussion

Ovarian cyst is a relatively rare fetal condition, but the incidence of neonatal ovarian cysts has markedly increased with the widespread use of ultrasonography during pregnancy. Neonatal ovarian cysts are primarily of follicular origin and probably result from disordered folliculogenesis (5). Evidence suggests that excessive stimulation of the fetal ovary by both placental and maternal hormones may be a significant factor in cyst development (5). According to Nussbaum's classification,

ovarian cysts can be divided into simple or uncomplicated (completely anechoic) and complex or complicated (characterized by fluid-debris level, clot, septa, echogenic wall) cysts suggesting torsion (6). While small cysts are usually confined to the adnexa, larger cysts can be completely intra-abdominal because of the small neonatal pelvis and the presence of long cyst pedicles (6). The majority of ovarian cysts are asymptomatic. Symptoms may arise from complications. Several authors have reported complications caused by compression of cysts on other viscera. To our knowledge, our patient is the first case in the literature presented with acute transient hepatic failure due to the compression by ovarian cysts. The pathology that underlies this patient's hepatic failure is probably the inadequate blood flow in the liver caused by the compression of huge cysts since other possible causes of acute hepatic damage were excluded and hepatic functions recovered rapidly with ascites drainage and albumin infusion. Hepatic failure resulting from perinatal hypoxemia was also excluded in this patient since there was no history of resuscitation or multiorgan dysfunction.

Detection of ovarian cysts is possible with ultrasound but it may be impossible to differentiate an ovarian cyst from a mesenteric or enteric cyst. Computerized tomography of the abdomen was performed to identify the origin of the cysts, but this was not possible until surgery. Most authors have recommended conservative

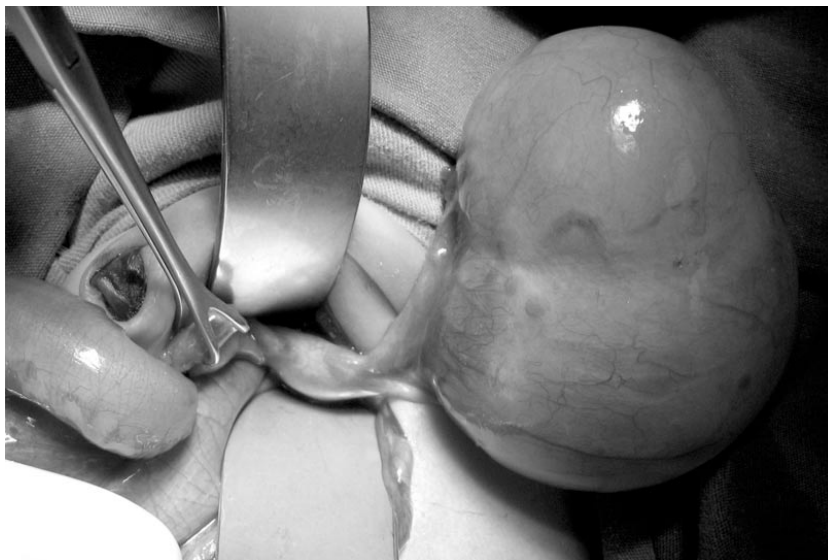


Figure 3. At laparotomy, a huge ovarian cyst was identified and resected.

management even for large ovarian cysts because of spontaneous remission during the neonatal period (7). Decision to perform surgical therapy depends on the clinical symptoms with the aim to avoid complications that may be life-threatening. Thus, surgical intervention is reserved for complex cysts, but this procedure often leads to the removal of normal ovarian tissue (7).

Laparoscopy may be safely performed in neonates and offers the advantages associated with minimally invasive surgery (8). Our patient was also successfully managed by laparotomy.

In conclusion, the case presented in this paper highlights the possibility of transient hepatic failure caused by huge neonatal ovarian cysts.

References

1. Wilson DA. Ultrasound screening for abdominal masses in the neonatal period. *Am J Dis Child* 1982; 136: 147-151.
2. Bagolan P, Giorlandino C, Nahom A, Bilancioni E, Trucchi A, Gatti C et al. The management of fetal ovarian cysts. *J Pediatr Surg* 2002; 37: 25-30.
3. Monson R, Rodgers BM, Nelson RM, Young TK. Ruptured ovarian cyst in a newborn infant. *J Pediatr* 1978; 93: 324-325.
4. Sapin E, Bargy F, Lewin F, Baron JM, Adamsbaum C, Barbet JP et al. Management of ovarian cyst detected by prenatal ultrasound. *Eur J Pediatr Surg* 1994; 4: 137-140.
5. Montag TW, Auletta FW, Gibson M. Neonatal ovarian cyst: prenatal diagnosis and analysis of the cyst fluid. *Obstet Gynecol* 1983; 61: 38-41.
6. Nussbaum AR, Sanders RC, Hartman JS, Dudgeon DL, Parmley TH. Neonatal ovarian cyst: sonographic pathologic correlation. *Radiology* 1988; 168: 817-821.
7. Brandt ML, Lucks FI, Filiatrault D, Garel L, Desjardins JG, Youssef S. Surgical indications in antenatally diagnosed ovarian cysts. *J Pediatr Surg* 1991; 26: 276-282.
8. Esposito C, Garipoli V, Di Matteo G, De Pasquale M. Laparoscopic management of ovarian cysts in newborns. *Surg Endosc* 1998; 12: 1152-1154.