

## How to Manage Triquetrum and Hamate Fractures in Unusual Patterns: A Case Report

Vuslat Sema ÜNAL

Fuad ÖKEN

Özgür YILDIRIM

Murat GÜLCEK

Zafer SOYDAN

Ahmet UÇANER

**Abstract:** The 3-dimensional alignment of the carpal bones should be intact to ensure functional integrity of the hand. The treatment of fractures of the carpal bones is challenging and may differ according to localization. A patient with closed carpal injury and his treatment are presented in this report.

After his wrist was crushed between a smooth hammer and a workbench during an occupational accident, the patient had multiple carpal bone fractures and remarkable swelling. The type of the injury was regarded to be a sort of capitate-hamate diastasis, although it did not correspond to any type that had been previously described. The clinical result was good, and the patient completely recovered.

**Key Words:** Carpal injury, hamate fracture, triquetrum fracture, carpal fractures

### Nasıl Üstesinden Gelinir? Ender Tipte Triquetrum ve Hamatum Kırıkları Olan Bir Olgu Sunumu

Department of Orthopedics and Traumatology, Ankara Numune Education and Research Hospital, Ankara - TURKEY

**Özet:** Elin fonksiyonel bütünlüğü için karpal kemiklerin üç boyutlu diziliminin sağlam olması gerekir. Karpal kemik kırıklarının tedavisi zordur ve lokalizasyona göre farklılıklar gösterebilir. Bu yazıda kapalı karpal yaralanması olan hasta ve tedavisi sunulmaktadır.

El bileğinin, bir iş kazası sırasında örs ile balyoz arasında sıkışması sonucu hastanın el bileğinde çoklu karpal kırıklarla beraber, belirgin şişlik oluşmuştur. Yaralanmanın tipi bir çeşit capito-hamat diastaz olmakla beraber daha önce tanımlanmış sınıflardan birine uymamaktadır. Klinik sonuç iyi olup hasta yaralanmadan önceki hayatına tamamen dönmüştür.

**Anahtar Sözcükler:** Karpal yaralanma, hamatum kırığı, triquetrum kırığı, karpal kırıklar

### Introduction

Severe crushing injuries affecting the carpal bones are rare (1). Reports of the management of multiple carpal bone fractures in the literature are too few (2). An intact ligamento-osseous structure is absolutely crucial for the functional integrity of the wrist (3). Capitate hamate diastasis was described by Garcia-Elias et al. in 1985. They reported that the carpal arch was disrupted through the capitate-hamate articulation distally and the piso-triquetral joint proximally, with slightly different variations (1).

The present report involves a patient that had fractures of the hamate and triquetrum body, and the fourth metacarpal base. Although the capitate-hamate and piso-triquetral joints were intact, the patient had remarkable displacement through the fracture line with rotational deformity of the fourth and fifth fingers as a unit. The injury type resembled a kind of capitate hamate diastasis and there was traumatic longitudinal disruption of the carpus.

### Case report

A 23-year-old, right-handed man was seen in the emergency room with pain, tenderness, swelling, ecchymosis, and a 0.5 x 1-cm dermabrasion on his dominant wrist. While he was working, a heavy hammer impacted on his wrist, which was against the workbench.

Received: October 09, 2006

Accepted: March 22, 2007

#### Correspondence

Vuslat Sema ÜNAL  
Çamlık Sitesi

Kugu Çıkmazı No: 119  
06800 Bilkent - ANKARA

vuslatsema@yahoo.com

The initial X-rays showed fracture lines in the mid portion of the triquetrum and body of the hamate bone, which were passing obliquely to the radial side of the hook (Figure 1). There was also a non-displaced fracture line at the base of the fourth metacarpal bone. Further investigations, using 2D and 3D computerized tomography, (CT) were performed to understand the exact configuration of the fractures. Fractures of both the hamate and triquetrum were displaced and the ulnar fragment of the hamate body was interposed between the fragments of the triquetrum. The fourth and fifth metacarpals, and ulnar fragments of the triquetrum and hamate were displaced ulnarly, together as a unit (Figures 2-4a and b).

Open reduction and internal fixation were performed through a 7-8-cm dorsoulnar incision. The fracture lines were identified and the interposed fragment of the

hamate was lifted distally; following reduction it was fixated with one mini-cortical lag screw (Figure 5a and b). The triquetrum was reduced and held with 2 mini-cortical lag screws. Soft tissues were carefully handled to avoid revascularization of the fragments.

A short arm cast was used for immobilization for 3 weeks and then wrist and carpometacarpal motion was allowed. Protective splinting was used for 3 additional weeks. Solid union was achieved at the third month and the patient had 45° of dorsiflexion and 50° of palmary flexion with no pain 6 months later. There was good restoration in the carpometacarpal and intercarpal joints, and solid union in both the hamate and triquetrum. The patient regained full functioning of his right hand and returned to work the seventh postoperative month. He had no complaints after 4 years of follow-up (Figure 6).

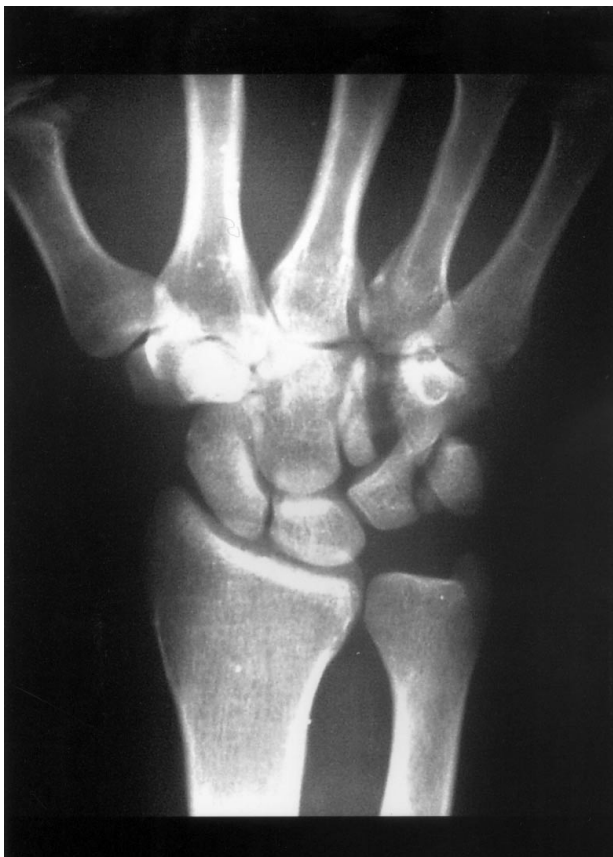

Figure 1. P-A X-ray of the patient's right wrist. Displaced fracture line is present on the body of the triquetrum and hamate. Separation between the third and fourth metacarpals is evident.

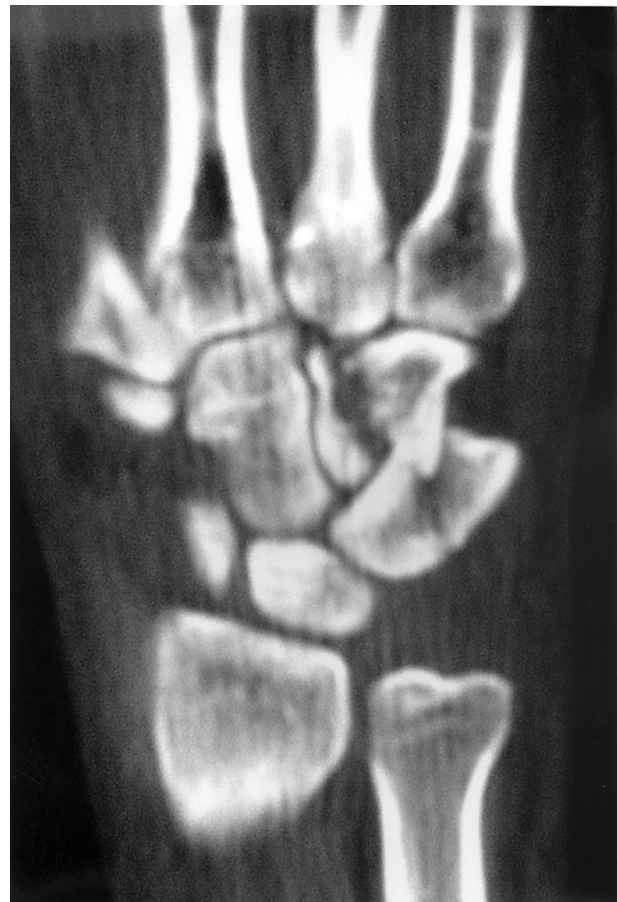

Figure 2. 2D coronary CT section of the patient's injured right wrist. The fragment of the hamate intervenes with the fragments of the triquetrum.

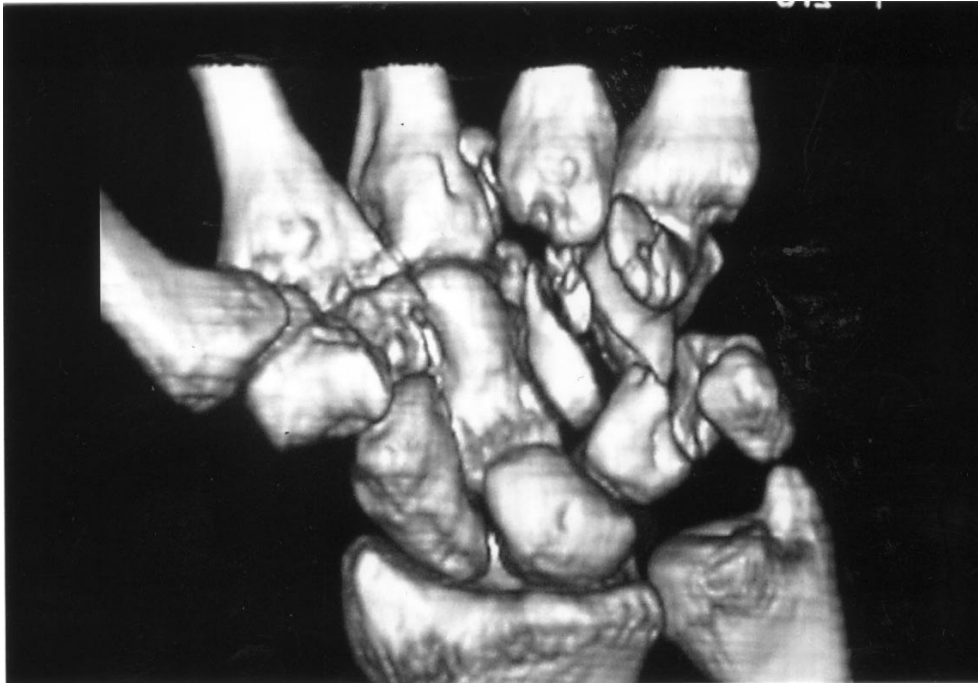
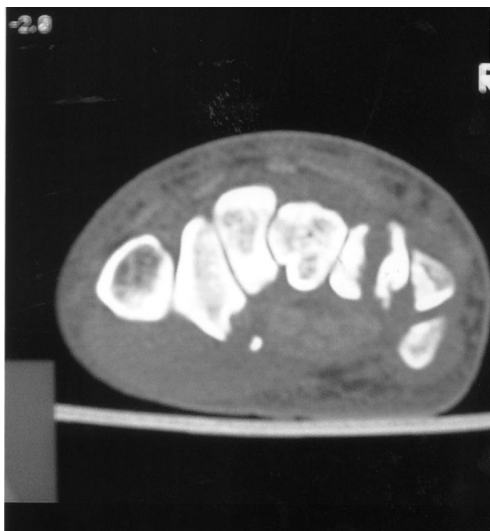
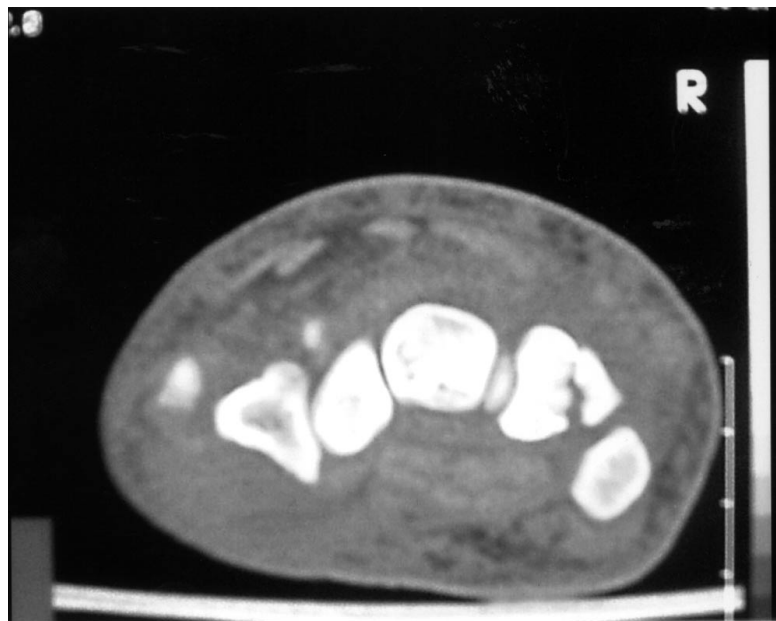

Figure 3. 3D CT image of the right wrist, from the volar view. The fourth and fifth metacarpals, and the ulnar fragments of the hamate and triquetrum are separated, together as a unit.



a



b

Figure 4. 2D transverse CT sections of the right wrist showing the vertical fracture line. a) hamate, b) triquetrum.

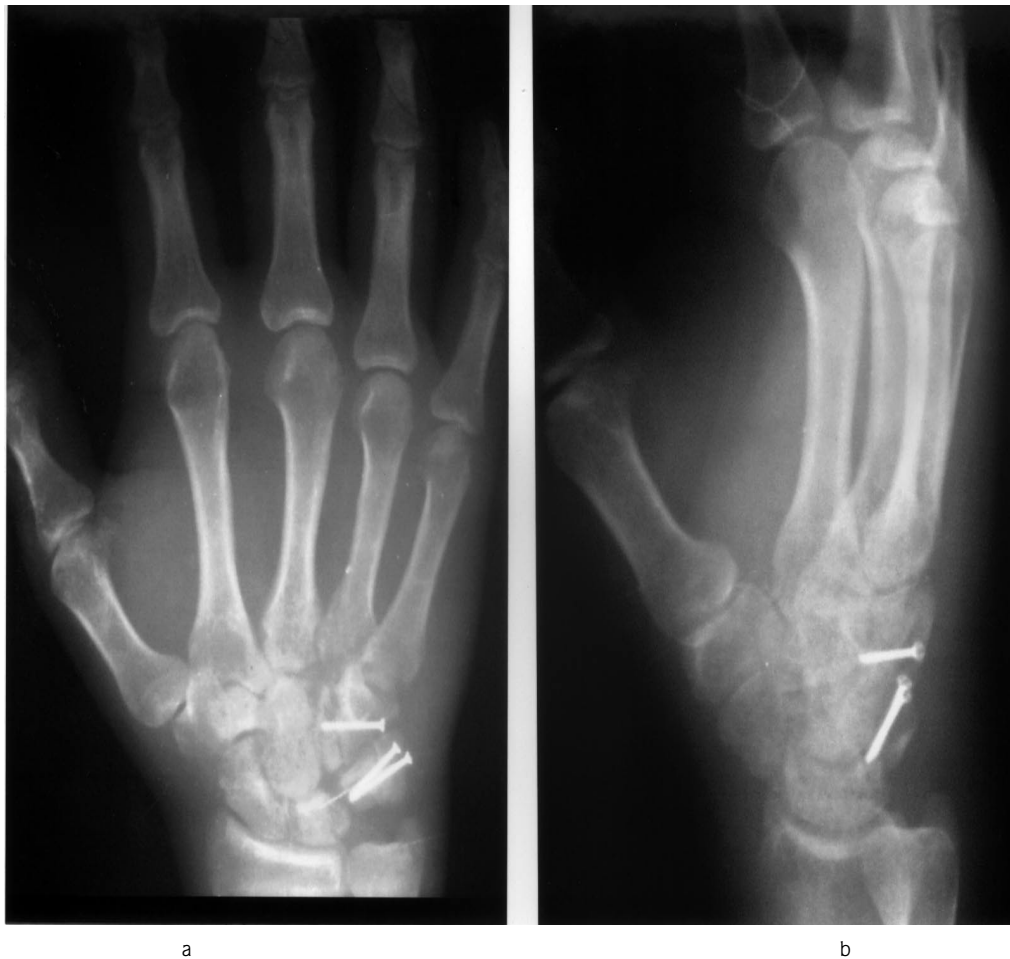

Figure 5. Early postoperative X-rays showing the location of the lag screws. a) P-A, b) lateral.

**Discussion**

Isolated fractures of the body of the hamate are rare and usually reported with fourth and fifth metacarpal bone fracture-dislocation together (4,5). If the fragments of the fractures are displaced, it can only be treated by open reduction and internal fixation (4).

Isolated fractures of the triquetrum are the third most common carpal fracture and the most common type is a chisel fracture. Body fractures occur rarely and if non-displaced this can be treated by closed reduction (5).

Traumatic longitudinal disruption of the carpal bones is a rare injury. It occurs through a weak point between the third and fourth metacarpals, and the capitate and hamate (6).

Our patient had fractures at the base of the fourth metacarpal bone, and the body of the hamate and triquetrum. The fragments were displaced and diastasis was present, with rotational deformities of the last 2 fingers. Closed reduction was not considered because there was interposition between the fragments and excessive displacement. Open reduction and internal fixation were performed (7,8). Mini lag screws were preferred to achieve stability and for early rehabilitation, although Ogunro has advised using K-wire (9).

Active exercises began the third postoperative week. Solid union was achieved at the end of the third month. Wrist motion was painless and the patient returned work the seventh postoperative month.

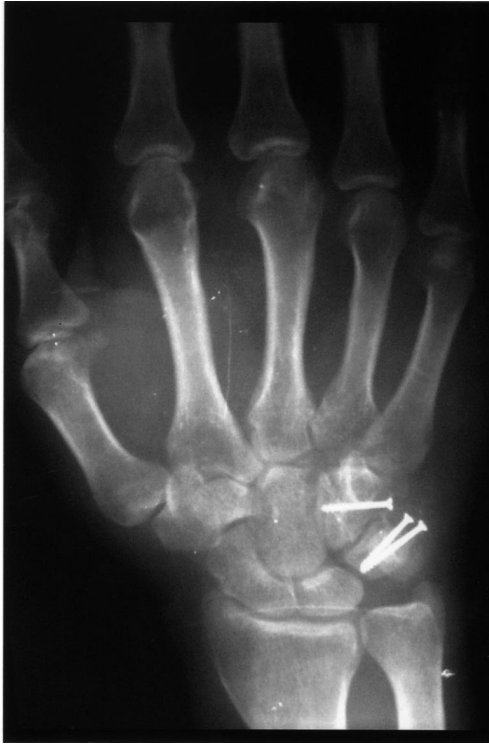

Figure 6. P-A X-ray of the right wrist 4 years after the operation.

There was no evidence of avascular necrosis after 4 years of follow-up. Although dorsiflexion of the wrist was slightly limited ( $10^{\circ}$ ) when compared to the other hand, pinch and grip strength were equal.

In conclusion, complex, displaced multiple carpal fractures can be treated with open reduction and internal fixation. Mini lag screws achieve adequate stable fixation so that active rehabilitation exercises can begin as early as the third postoperative week.

## References

1. Garcia-Elias M, Abanco J, Salvador E, Sanches R. Crush injury of the carpus. *J Bone Joint Surg* 1985; 67B: 286-9.
2. Zoltie N. Fractures of the body of the hamate. *Injury* 1991; 22: 459-62.
3. Ozcelik A, Gunal I, Kose N, Seber S, Omeroglu H. Wrist ligaments: Their significance in carpal instability. *Ulus Travma Derg* 2005; 11: 115-20.
4. Amadio PC, Taleisnik J. Fractures of the carpal bones. In: Green DP editor. *Operative hand surgery*. 3rd ed. New York: Churchill Livingstone, 1993: p799-860.
5. Ruby L. Fractures and dislocations of the carpus. In: Browner B editor. *Skeletal Trauma*. 1st ed. Philadelphia: WB Saunders Company, 1992: p1025-62.
6. Norbeck DE Jr., Larson B, Blair SJ, Demos TC. Traumatic longitudinal disruption of the carpus. *J Hand Surg* 1987; 12A: 509-14.
7. Kimura H, Kamura S, Akai M, Ohno T. An unusual coronal fracture of the body of the hamate bone. *J Hand Surg* 1988; 13A: 743-5.
8. Loth TS, McMillan MD, Riley F. Coronal dorsal hamate fractures. *J Hand Surg* 1988; 13A: 616-8.
9. Ogunro O. Fracture of the body of the hamate bone. *J Hand Surg* 1983; 8: 353-5.