

## Prevention of Adhesions by Omentoplasty: An Incisional Hernia Model in Rats

Bülent AYDINLI<sup>1</sup>  
Gürkan ÖZTÜRK<sup>1</sup>  
Mahmut BAŞOĞLU<sup>1</sup>  
S. Selçuk ATAMANALP<sup>1</sup>  
İlhan YILDIRGAN<sup>1</sup>  
K. Yalçın POLAT<sup>1</sup>  
Mehmet ÖZTÜRK<sup>1</sup>  
Cemal GÜNDOĞDU<sup>2</sup>  
Durkaya ÖREN<sup>1</sup>

<sup>1</sup> Department of General Surgery,  
Faculty of Medicine,  
Atatürk University,  
Erzurum - TURKEY

<sup>2</sup> Department of Pathology,  
Faculty of Medicine,  
Atatürk University,  
Erzurum - TURKEY

**Background and Aim:** Adhesion formation following abdominal wall hernia repair with prosthetic mesh may lead to intestinal obstruction and enterocutaneous fistulae. The purpose of this study was to compare the efficacy of fibrin glue (FG) and omentoplasty in the prevention of adhesion formation in a polypropylene mesh (PPM) abdominal wall replacement model.

**Materials and Methods:** The study consisted of 3 groups of rats. A full-thickness abdominal wall defect was replaced with PPM. The control group (group 1) had no further treatment. The under surface of the PPM was covered with human FG in the FG group (group 2) and with greater omentum in the omentoplasty group (group 3). Two observers blinded to the randomization assessed the degree of adhesions (0-4) to PPM and percentage of the PPM area covered by adhesions (0%-100%).

**Results:** The degree of adhesions in group 1 was significantly higher than that in groups 2 and 3. Group 2 had a higher adhesion degree than group 3. The mean percentage of the patch surface area covered by adhesions in group 1 was higher than that in groups 2 and 3. This was higher in group 2 than in group 3.

**Conclusion:** FG reduced the adhesions, but the greater omentum is an autologous anti-adhesive barrier and omentoplasty reduced adhesions more significantly than FG.

**Key Words:** Incisional hernia, polypropylene mesh, fibrin glue, omentoplasty

### Ratlarda Oluşturulan İnsizyonel Herni Modelinde Omentoplasti ile Yapışıklıkların Önlenmesi

**Giriş ve Amaç:** Protetik yamalarla yapılan karın duvarı fitik tamirlerini takiben oluşan yapışıklıklar barsak tıkanıklığına ve enterokutanöz fistüllere neden olabilirler. Bu çalışmanın amacı Polypropylene yama ile yapılan karın duvarı tamiri modelinde Fibrin yapıştırıcı ve omentoplastinin etkinliklerini mukayese etmektir.

**Yöntem ve Gereç:** Çalışma üç grup rattan oluşmaktaydı. Bir tam kat karın duvarı defekti Polypropylene yama ile kapatıldı. Kontrol grubuna (grup 1) başka tedavi yapılmadı. Fibrin yapıştırıcı grubunda (grup 2) ise insan fibrinojenile, yamanın alt yüzeyi omentoplasti grubunda (grup 3) büyük omentumla kaplandı. Yapılan randomizasyondan habersiz olan iki gözlemci yamaya olan yapışıklıkların derecesini (0-4) ve yama yüzeyinin yapışıklıkla kaplı alanının yüzdesini değerlendirdiler (% 0-100).

**Bulgular:** Grup 1'deki yapışıklıklar grup 2 ve 3'ten önemli derecede yüksekti. Grup 2 ise grup 3'e göre daha yüksek bir yapışıklık oranına sahipti. Yapışıklıklarla kaplı olan yama yüzeyinin yüzdesi grup 1'de grup 2 ve 3'ten yüksekti. Grup 2'de bu oran grup 3'ten yüksekti.

**Sonuç:** Bu bulgular göstermektedir ki her ne kadar fibrin yapıştırıcı yapışıklıkları azaltmaktadır fakat omentum otolog yapışıklıkları önleyici bir bariyerdir ve yapışıklıkları önlemede fibrin yapıştırıcılardan daha etkilidir.

**Anahtar Sözcükler:** İnsizyonel Herni, polypropylene yama, fibrin yapıştırıcı, omentoplasti

Received: September 05, 2006  
Accepted: March 09, 2007

### Introduction

Incisional hernias occur in 11% of patients after laparotomy (1,2). The repair of large abdominal wall defects resulting from trauma, necrosis, tumor, or other causes presents a challenge for the surgeon. Many synthetic materials have been tried and no single material has gained universal acceptance or preference (3). The ideal prosthesis is one that maintains adequate strength, incorporates with surrounding tissues, and does not stimulate visceral adhesion formation (1,3). Postsurgical adhesion formation is a significant clinical problem for every surgical section (4). These adhesions are significant sources of morbidity and mortality as a result of postoperative bowel obstruction,

#### Correspondence

Bülent AYDINLI  
Department of General Surgery,  
Faculty of Medicine,  
Atatürk University,  
Erzurum, TURKEY

e-mail: bulentaydinli@gmail.com

infarction, fistula formation and erosion after every abdominal surgery (3-5). Because of these problems, a wide variety of adjunctive treatments to prevent the formation and reformation of adhesions have been proposed. Most of these treatments, however, show controversial results. In an attempt to reduce the inflammatory reaction at the site of the peritoneal trauma, corticosteroids were used. Later the anti-adhesive properties of calcium channel blockers and antihistamines were studied. More recent studies deal with non-steroidal anti-inflammatory drugs, tissue plasminogen activators, and selective immunosuppressors (6-9). One of these modalities that has been studied extensively and showed promising results is the so-called barrier method. With this technique, surgically traumatized surfaces are kept covered during mesothelial regeneration, thus preventing adherence of adjacent structures and reducing adhesion formation. Barriers consist of fluids such as 32% Dextran 70 and Ringer's lactate solution, as well as of solid materials such as carboxymethylcellulose, oxidized regenerated cellulose, expanded polytetrafluoroethylene, fibrin glue (FG) and seprafilm, a bioresorbable, translucent membrane composed of hyaluronic acid (HA), and carboxymethylcellulose (CMC).

The purpose of the present study was to compare the efficacy of FG and omentoplasty in the prevention of adhesion formation in a rat model using a polypropylene mesh in abdominal wall replacement.

## Materials and Methods

All the experiments in this study were performed in accordance with the Guidelines for Animal Research by the National Institute of Health, and the experimental procedures in the present study were approved by the local ethics committee (Atatürk University Ethical Committee). The animals were treated according to guidelines set by the Atatürk University Animal Laboratory. Forty-five Sprague Dawley male rats weighing 225-275 g were used. The rats were obtained from the Atatürk University Animal Laboratory, Erzurum, Turkey. The experiments were performed at the Atatürk University Experimental Research Center. The rats were kept in stainless steel cages, given food and water ad libitum, and quarantined 7 days before surgery. Food was withheld 8 h prior to surgery, but there was free access

to water. The rats were anesthetized with intraperitoneal administration of 50 mg/kg ketamin hydrochloride (Ketalar; Parke-Davis, Morris Plains, NJ, USA) and 10 mg/kg xylazine hydrochloride for the operation. The abdomen was shaved and disinfected with 70% povidone iodine. All the surgical procedures were performed under sterile conditions by a single researcher. After a 4 cm midline incision was made, skin flaps were prepared. A 1.5 to 2.5 cm segment of the abdominal wall (muscles and attached peritoneum) was removed. The antimesenteric border of the cecum was abraded with sterile gauze until punctuate bleeding occurred. After replacement of the abraded cecum, the abdominal wall defect was repaired with a 1.5 to 2.5 cm piece of PPM that was sutured to the abdominal wall with 4-0 polypropylene continuously. The rats were then randomized into 3 equal groups as follows: control group (group 1), FG group (group 2), and omentoplasty group (group 3).

Group 1 had no further treatment of their patches. In group 2, the undersurface of the PPM was covered with human fibrinogen obtained from 0.5 ml of cryoprecipitate mixed with 0.5 ml of bovine thrombin (1000 U/ml) and calcium (6.24 mmol/l). In group 3, the undersurface of the PPM was covered with the greater omentum fixed with interrupted sutures. The laparotomy incision was closed with a running 3-0 polypropylene suture. On postoperative day 21, all the rats were sacrificed using lethal doses of intra-abdominal pentobarbital sodium. The laparotomy was performed, and the degree of adhesion formation was graded from 0 to 4 by a blinded independent observer as follows: grade 0: no adhesions; grade I: a thin, filmy, easily separated adhesion; grade II: several thin adhesions; grade III: thick broad adhesions, and grade IV: several thick adhesions or thick adhesions to organs or the abdominal wall (10). The extent and severity of adhesions in the operation site for each parietal peritoneum were evaluated using an established scoring system (11). According to this system, the extent of adhesions was evaluated as follows: 0, no adhesion; 1, 25% of traumatized area; 2, 50% of traumatized area; and 3, total involvement.

Peritoneal biopsy specimens were taken from the edge of the PPM (in the right lower quadrant) using a disposable 6 mm diameter biopsy punch while the animals were alive. Pathological specimens of patches and adhesions obtained at laparotomy were fixed in 10%

formalin. Histological specimens were stained with hematoxylin and eosin. The sections were studied to evaluate the following histological features: inflammation, fibrosis, and granulomatosis. For histological analysis under light microscopy, tissues were fixed in 10% formalin in phosphate-buffered saline and processed with paraffin wax. Tissue sections of 6 mm were stained with hematoxylin and eosin and were examined with a light microscope (Olympus BH-2). Five coded slides from each group were examined by a pathologist blind to all the study groups using light microscopy to evaluate the presence and degree of neutrophil infiltration.

The percentage coverage of each patch by adhesion formation was determined using a surface area grid and rounding off to the nearest 5%.

Statistical analysis was performed by Mann-Whitney U test. All the data are expressed as the mean  $\pm$  SD. Differences with a P value  $<0.05$  were considered statistically significant.

## Results

The results of the study are shown in Figures 1 and 2. Of the 15 animals in group 3, 11 had no adhesions, and 1 had grade 1 adhesions (80.0%). While only 2 animals in group 1 had grade 1 adhesions, the remainder had higher grade adhesions (13.3%). While 2 animals in group 2 had no adhesions, 5 had grade I adhesions (46.6%). The degree of adhesions in group 1 was significantly higher than that in groups 2 and 3 ( $P < 0.05$ ,  $P < 0.000$ , respectively). Group 2 had a significantly higher adhesion degree than group 3 ( $P < 0.01$ ).

All the animals in group 3 (100%), 10 of the 15 (66.6%) in group 2, and 3 of the 15 (20%) in group 1

had adhesions involving  $\leq 25\%$  of surface area of the patch. The mean percentage patch surface area covered by adhesions in group 1 was significantly higher than that in groups 2 and 3 ( $P < 0.01$  and  $P < 0.0001$ , respectively). Group 2 had significantly higher mean percentage patch surface areas covered by adhesions than group 3 ( $P < 0.001$ ). The adhesions were significantly lower in omentoplasty-treated animals.

Histological analysis revealed good fibroblast proliferation in the wound site, resulting in well-formed scar tissue in the 3 groups.

## Discussion

Tension-free repair of incisional hernias with prosthetic material has reduced the recurrence rates reported as 30%-46% after primary repairs to 2.2%-10% in recent studies. The ideal mesh maintains adequate permanent closure of the abdominal wall defect, has a low infection rate, causes few adhesions, and induces no enterocutaneous fistulas (1). PPM, which is used to repair large incisional hernias, induces foreign body reaction and acts as ischemic tissue in the peritoneum (11). This makes adhesion formation almost inevitable between the viscera and PPM. These intra-abdominal adhesions are significant sources of morbidity and mortality as a result of postoperative bowel obstruction, infarction, and fistula formation (1,5,11-13).

The development of adhesions involves a complex interaction between the deposition of fibrinous exudates and the lyses of fibrin via the fibrinolytic system of the mesothelial cells (15). In the presence of inflammation or tissue ischemia, fibrinolysis may be inhibited because of decreased plasminogen activity, thereby facilitating the

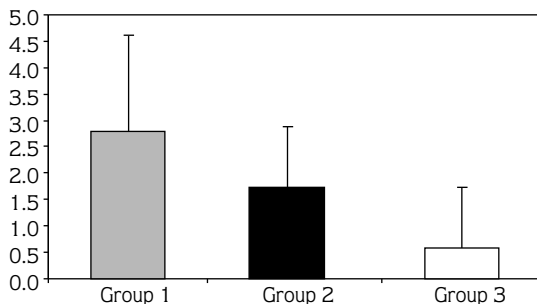


Figure 1. The effects of fibrin glue and omentoplasty on adhesion formation (grades).

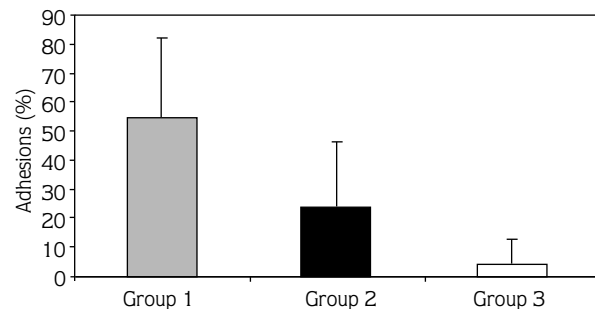


Figure 2. The effects of fibrin glue and omentoplasty on adhesion formation (percentages).

organization of fibrin exudates into fibrinous adhesions (5).

The role of FG in the formation of adhesions has only become the subject of studies recently. According to the traditional model of adhesion formation, fibrin serves as a matrix for ingrowths of fibroblasts with their subsequent elaboration of collagen, and FG seemed to have the potential for markedly increasing adhesion formation. However, several studies in rats and rabbits where peritoneal defects were treated with FG showed a significant decrease in intra-abdominal adhesion formation and reformation (13-17). Other investigators have not reported good results with FG as an adhesion prevention method (14,18). The mechanism by which FG reduces adhesion formation is not clear. Application of FG to the injured surfaces might be expected to enhance the formation of adhesions, but instead it appears that by coating the injured surfaces with FG a smooth layer covers the surface and prevents contact adherence (14). Dulchavsky et al. (19) showed a decrease in post-injury inflammatory cellular infiltration after FG application and suggested that FG may decrease adhesions in this way. Toosie et al. (5) postulated that FG might provide a physical barrier between the surrounding tissue and the foreign material, thereby isolating the healing wound and its inflammatory process from the remainder of the peritoneum and viscera.

In the present study, we evaluated the efficacy of FG in reducing intra-abdominal adhesion formation in a model using PPM. We detected that the degree of adhesion formation and the percentage coverage to PPM were higher in group 1 than in group 2 ( $P < 0.01$  and  $P < 0.05$ , respectively). However, the degree of adhesion formation and the percentage coverage of PPM in group 2 were significantly higher than those in group 3 ( $P < 0.01$  and  $P < 0.001$ , respectively). In a rat ventral hernia model study, Toosie et al. (5) showed that FG

significantly reduced adhesion formation to a synthetic patch (Gore-Tex).

To prevent adhesions, some authors recommend that the parietal peritoneum must be preserved during incisional hernia repair because it forms a barrier. When the parietal peritoneum cannot be kept intact, the surgeon may attempt to place the greater omentum between the abdominal contents and the prosthetic material (1). In the present study, our data demonstrate that omentoplasty significantly reduces both the degree of adhesion formation and the percentage coverage of PPM. Group 3 showed a significantly lower adhesion degree and area than groups 1 and 2. Sperlongano et al. (20) described 5 patients who underwent repair of complex giant ventral hernias with PPM and omentoplasty. They concluded that the omentum, when there is a lack of tissue and a need for autologous tissue to place between the viscera and the above-lying PPM, is potentially useful, and stated that no complications or recurrences occurred. Geoffrey et al. (2) reported that, although not statistically significant, excision of the hernia sac, lack of omentum interposition, and the presence of a fascial gap could cause a higher incidence of enterocutaneous fistula formation. Bowel protection is essential in an attempt to avoid long-term complications after prosthetic repair in incisional hernias. Minimizing dissection and attempting to perform a fascial on-lay when possible may help to accomplish this. The hernia sac should be imbricated when feasible and used as a further barrier between the bowel and mesh. If this is not feasible, the greater omentum should be laid on the intestines to form a barrier between the mesh and intestines.

Finally, we recommend that although FG caused a reduction of adhesions the greater omentum proved to be an effective autologous anti-adhesive barrier in PPM repair of abdominal wall hernia.

## References

1. Vrijland WW, Bonthuis F, Steyerberg EW, Marquet RL, Jeeker J, Bonjer HJ. Peritoneal adhesions to prosthetic materials: Choice of mesh for incisional hernia repair. *Surg Endosc* 2000; 14: 960-3.
2. Leber GE, Garb JL, Alexander AI, Reed WP. Long-term complications associated with prosthetic repair of incisional hernias. *Arch Surg* 1998; 133: 378-82.
3. Jenkins SD, Klamer TW, Parketa JJ, Condon RE. A comparison of prosthetic materials used to repair abdominal wall defects. *Surgery* 1983; 94: 392-8.
4. Hellebrekers BWJ, Trimbos-Kemper GCM, van Blitterswijk CA, Bakkum EA, Trimbos JBMZ. Effects of five different barrier materials on postsurgical adhesion formation in the rat. *Human Reproduction* 2000; 15: 1358-63.
5. Toosie K, Gallego K, Stabile BE, Schaber B, French S, deVirgilio C. Fibrin glue reduces intra-abdominal adhesions to synthetic mesh in a rat ventral hernia model. *Am Surg* 2000; 66: 41-5.
6. diZegera GS. Contemporary adhesion prevention. *Fertil Steril* 1994; 61: 219-35.

7. Pijlman BM, Dörr PJ, Brommer EJP, Vemer HM. Prevention of adhesion. *Eur J Obstet Gynecol. Reprod Biol* 1994; 53: 155-63.
8. Bakkum EA, Trimbos JB, Trimbos-Kemper TCM. Postsurgical adhesion formation and prevention – recent developments. *Reprod Med Rev.* 1996; 5: 1-13.
9. Risberg B. Adhesions: preventive strategies. *Eur J Surg Suppl* 1997; 577: 32-9.
10. Nagler A, Rivkind AI, Raphael J, Levi-Schaffer F, Genina O, Lavelin I, Pines M Halofuginone—an inhibitor of collagen type I synthesis—prevents postoperative formation of abdominal adhesions. *Ann Surg.* 1998; 227: 575-82.
11. Alponat A, Lakshminarasappa SR, Yavuz N, Goh PMY. Prevention of adhesions by seprafilm, an absorbable adhesion barrier: an incisional hernia model in rats. *Am Surg* 1997; 63: 818-9.
12. van't Riet M, de Vos van Steenwijk PJ, Bonthuis F, Marquet RL, Steyerberg EW, Jeekel J, Bonjer HJ. Prevention of adhesion to prosthetic mesh: comparison of different barriers using an incisional hernia model. *Ann Surg* 2003; 237: 123-8.
13. Dubay DA, Wang X, Kuhn MA, Robson MC, Franz MG. The prevention of incisional hernia formation using a delayed-release polymer of basic fibroblast growth factor. *Ann Surg* 2004; 240: 179-86.
14. Harris ES, Morgan RF, Rodeheaver GT. Analysis of the kinetics of peritoneal adhesion formation in the rat and evaluation of potential antiadhesive agents. *Surgery* 1995; 117: 663-9.
15. deVirgilio C, Dubrow T, Sheppard BB, MacDonald WD, Nelson RS, Lesavoy MA, Robertson SM. Fibrin glue inhibits intra-abdominal adhesion formation. *Arch Surg* 1990; 125: 1378-81.
16. Caballero J, Tulandi T. Effects of ringers' lactate and fibrin glue on postsurgical adhesions. *J Reprod Med.* 1992; 37: 141-3.
17. Sheppard BB, deVirgilio C, Bleiweis M, Milliken JC, Robertson JM. Inhibition of intra-abdominal adhesions: fibrin glue in a long term model. *Am Surg* 1992; 59: 786-90.
18. Tulandi T. Effects of fibrin sealant on tubal anastomosis and adhesion formation. *Fertil Steril* 1991; 56: 136-8.
19. Dulchavsky SA, Geller ER, Mauer J, Kennedy PR, Tortora GT, Maitra SR. Autogenous Fibrin gel: bactericidal properties of fibrin gel in contaminated hepatic injury. *J Trauma* 1991; 31: 991-5.
20. Sperlongano P, Pisaniello D, Pone D. Repair of complex giant ventral hernias with polypropylene and omentoplasty. *Chir Ital* 1999; 51: 389-92.