

Ogilvie's Syndrome: Presentation of 15 Cases*

S. Selçuk ATAMANALP
M. İlhan YILDIRGAN
Mahmut BAŞOĞLU
Bülent AYDINLI
Gürkan ÖZTÜRK

Department of General Surgery,
Faculty of Medicine,
Atatürk University,
25070 Erzurum - TURKEY

Background: Ogilvie's syndrome is characterized by acute, massive colonic dilatation, without any mechanical obstruction.

Methods: The records of 15 patients with Ogilvie's syndrome were retrospectively reviewed with respect to gender, age, associated problems, symptom duration, symptoms, signs, treatment, morbidity, mortality, and recurrence.

Results: Mean age of the patients (8 male, 7 female) was 49.9 years (range: 32-76 years). Among them, 5 had medical problems, while 4 patients had had abdominal surgery, and 2 patients had burns. Mean symptom duration was 2.9 days (range: 1-7 days). The most common symptoms were abdominal pain and distention, while the most common signs were abdominal tenderness and distention. Mean cecal diameter was 10.0 cm (range: 7-13 cm) in plain abdominal X-ray films. The initial treatment was conservative in all patients; 5 were treated with intravenous neostigmine and complete resolution was achieved in 4 of them (80%). Flexible colonoscopic decompression was performed in 9 patients, with placement of a colonic tube; a success rate of 88.9% and a recurrence rate of 12.5% were noted. Tube cecostomy procedures were performed on 4 patients. No major complications were encountered in this series, but one patient with burns died (6.7%).

Conclusions: The initial treatment of Ogilvie's syndrome is conservative, and neostigmine treatment is generally successful. Decompression colonoscopy can be performed safely and successfully. Surgical treatment is performed when colonoscopy is unsuccessful, or when cecal ischemia, necrosis, or perforation is suspected.

Key Words: Ogilvie's syndrome, neostigmine, colonoscopy, cecostomy

Ogilvie Sendromu: Onbeş Olgunun Sunumu

Giriş: Ogilvie Sendromu, mekanik bir tıkanıklık olmaksızın kolonun akut yaygın dilatasyonu ile karakterizedir.

Yöntem ve Gereç: Ogilvie Sendromlu 15 hastanın kayıtları, cins, yaş, eşlik eden problemler, belirti süresi, belirtiler, bulgular, tedavi, morbidite, mortalite ve nüks yönünden retrospektif olarak gözden geçirildi.

Bulgular: Sekiz hasta erkek, 7 hasta bayan olup yaş ortalaması 49,9 idi (32-76 arası). Beş hastada medikal problemler varken, 4 hasta ameliyat geçirmişti ve 2 hastada da yanık vardı. Ortalama belirti süresi 2,9 gündü (1-7 arası). En sık karşılaşılan belirtiler karın ağrısı ve şişkinlik iken, en sık görülen bulgular karında hassasiyet ve distansiyonu. Düz karın grafilerinde ortalama çekum çapı 10,0 cm idi. (7-13 arası). Başlangıç tedavisi bütün hastalarda konservatifti. Beş hasta intravenöz neostigmin ile tedavi edildi ve bunların 4'ünde tam açılma sağlandı (% 80,0). Fleksibil kolonoskopik dekompresyon 9 hastaya uygulandı, başarı % 88,9 ve nüks % 12,5 oranında görüldü. Dört hasta cerrahi olarak tüp çekostomi ile tedavi edildi. Bu seride büyük bir komplikasyon görülmedi, fakat yanıklı 1 hasta kaybedildi (% 6,7).

Sonuç: Ogilvie Sendromu'nda başlangıç tedavisi konservatiftir ve neostigmine tedavisi genellikle başarılıdır. Dekompresyon kolonoskopisi güvenle ve başarıyla kullanılabilir. Cerrahi tedavi, kolonoskopi başarısız olduğunda ya da çekal iskemi, nekroz veya perforasyon şüphesi varlığında kullanılır.

Anahtar Sözcükler: Ogilvie Sendromu, neostigmin, kolonoskopi, çekostomi

Received: September 05, 2006
Accepted: March 01, 2007

Correspondence

S. Selçuk ATAMANALP
Department of General Surgery,
Faculty of Medicine
Atatürk University,
25070 Erzurum – TURKEY

ssa@atauni.edu.tr

* A part of this manuscript was presented as a poster presentation at the 21st Biennial Congress of the International Society of University Colon and Rectal Surgeons, June 25-28, 2006, İstanbul, Turkey.

Introduction

Ogilvie's syndrome (acute colonic pseudo-obstruction: ACPO) is characterized by acute, massive colonic dilatation, without any mechanical obstruction (1-5). It is often seen in association with some critical surgical or medical problems (1,4-7). The common clinical features of ACPO are significant abdominal distention and abdominal silence. Although patients may continue to pass small amounts of flatus or stool, colonic function is generally inadequate. Abdominal pain, tenderness, and low-grade fevers are also common, while nausea and vomiting are rare (4-6). Plain abdominal radiographs are generally diagnostic with significant colonic distention, with minimal or no distention of the small intestine (1,3-6). ACPO resolves spontaneously over a few days in most cases, and so the initial treatment is generally conservative, which consists of the restriction of oral intake, nasogastric decompression, rectal tube placement, correction of fluid or electrolyte abnormalities, and treatment of specific problems. Some bowel stimulants, including neostigmine, may be used (5-8). Colonoscopic decompression, with or without colonic tube placement, is the basic treatment method (5,9). Surgical treatment is indicated when colonoscopy is unsuccessful, or cecal ischemia, necrosis, or perforation is suspected. Cecostomy is successful if the bowel is viable (1-5).

Methods

We retrospectively reviewed the records of 15 patients with Ogilvie's syndrome, who underwent medical, endoscopic, or surgical treatment at Atatürk University, School of Medicine, Department of General Surgery between January 1995 and December 2005. The records were evaluated with respect to age, gender, associated problems, symptom duration, symptoms, signs, treatment, morbidity, mortality, and recurrence.

The diagnoses were made by physical examination and radiological findings in all patients. The diagnostic parameters included the presence of acute massive colonic dilatation (cecal diameter ≥ 7 cm on abdominal plain X-ray films) and the absence of mechanical obstruction. The diagnoses were also supported by endoscopic examination or surgical treatment findings.

Conservative treatment, which included the restriction of oral intake, nasogastric decompression, rectal tube placement, and correction of metabolic problems, was the initial treatment in all the patients, except in those who had acute abdominal symptoms and signs, and whose cecal diameter was > 13 cm. After 24 h, in addition to the conservative treatment, some selected patients, in whom there were no contraindications for neostigmine treatment, were treated with 2.5 mg of neostigmine intravenously in 100 ml of saline over 1 h monitored by electrocardiography. Similarly, in some patients, in whom there were no contraindications for endoscopic treatment or in whom neostigmine treatment was unsuccessful, a colonic tube was placed by flexible colonoscopy (Olympus CFP 10 L, CF 30 L, CF 240 AL). The indications for surgery were as follows: unsuccessful colonoscopy, recurrence after successful colonoscopy, presence of acute abdominal symptoms and signs, and cecal diameter > 13 cm. In the surgical treatment, tube cecostomy, with or without appendectomy, was performed.

Results

In all, 15 patients with Ogilvie's syndrome were treated during an 11-year-period. Mean age of the patients was 49.9 years (range: 32-76 years), and 8 (53.3%) were male and 7 (46.7%) were female. Among the patients, 5 (33.3%) had medical problems (2 patients had diabetes mellitus, 1 patient had epilepsy, 1 patient had Parkinsonism, and 1 patient had drug intoxication with amitraz), 4 (26.7%) had had abdominal surgery (cesarean in 3 patients and hysterectomy in 1 patient), and 2 patients (13.3%) had burns (1 patient had 35% and 1 patient had 42% second and third degree burns), while in 4 patients (26.7%) no causative factors were found. None of the patients had a prior history of colonic disease. The mean symptom duration was 2.9 days (range: 1-7 days). The main symptoms were abdominal pain and distention in all the patients, constipation in 13 patients (86.7%), nausea in 4 patients (26.7%), vomiting in 3 patients (20.0%), and diarrhea in 2 patients (13.3%). The main signs were abdominal tenderness and distention in all patients, hypoactive or no bowel sounds in 9 patients (60%), low-grade fever in 3 patients (20%), and muscular rigidity and rebound phenomenon in 2 patients (13.3%). The mean cecal diameter was 10.0 cm (range: 7-13 cm) on plain abdominal X-ray films.

Initial treatment included the restriction of oral intake, nasogastric decompression, rectal tube placement, and correction of metabolic problems. Five patients (33.3%), with a mean cecal diameter of 9.2 cm (range: 9-10 cm), were treated with intravenous neostigmine, and no complications occurred. In 4 patients (80%) complete resolution was obtained within 90 min, while in one patient (20%) neostigmine treatment was unsuccessful and he was treated with colonoscopy. Colonoscopic decompression was performed in 9 patients (60%), with a mean cecal diameter of 9.7 cm (range 7 to 11), and no complications occurred. There were 8 successful colonoscopic decompressions (88.9%). In one patient (11.1%), colonoscopic decompression was unsuccessful, and in another patient (12.5%), recurrence was seen 1 day later; they were both subsequently treated surgically. Thus, the total success rate of the non-surgical treatments was 84.6% (11/13).

Four patients (26.7%), with a mean cecal diameter of 10.8 cm (range: 7-3 cm), were treated surgically; tube cecostomy was performed in 3 patients (75%) with appendectomy, while in one patient (25%), no appendectomy was performed. The cecostomy tubes were discharged 2 weeks later and no major complications occurred, except for one incisional infection (25%). One patient (6.7%), with 42% third degree burns, died from septic shock. The treatment methods used are summarized in the Figure, and the details for each case are listed in the Table.

Discussion

Ogilvie's syndrome (acute colonic pseudo-obstruction: ACPO) was first described by William Heneage Ogilvie in 1948 (1,2,4-6). It is characterized by acute massive dilatation of the cecum and the right colon, without any organic obstruction (2,3,5,6). ACPO may occur in any patient population, but has a higher predilection for males in the sixth decade (3,5,6). In the present study, the male to female ratio was 8:7 and our patient group was younger than the commonly afflicted population. This difference in age may be explained by the mean age of the general population of Turkey and the causes of ACPO in this series.

The pathogenesis of ACPO is not fully understood, although it is thought to be an imbalance between inhibitory sympathetic and stimulatory parasympathetic

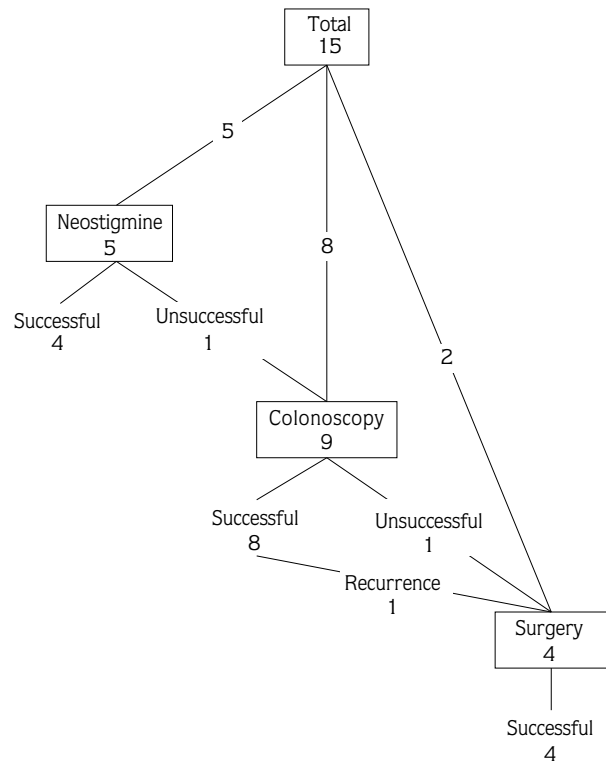


Figure. Treatments of the patients with Ogilvie's syndrome.

innervations (3-5,7). Delgado-Aros and Camilleri (5) have summarized the pathophysiology of ACPO as follows: reflex motor inhibition through splanchnic afferents in response to noxious stimuli; excess sympathetic motor input to the gut (intestine does not contract); excess parasympathetic motor input to the gut (intestine does not relax); decreased parasympathetic motor input to the gut (intestine does not contract); excess stimulation of peripheral micro-opioid receptors by endogenous or exogenous opioids; inhibition of nitric oxide release from inhibitory motoneurons.

ACPO is typically a secondary diagnosis and it is generally associated with some surgical or medical problems, as it was in 11 of the patients in the present series. Intra-, retro-, or extraperitoneal surgery (gastrointestinal, urological, gynecologic, orthopedic, cranial, and vertebral), traumas, burns, sepsis, transplantations, malignancies, systemic diseases (cardiovascular, pulmonary, hepatic, renal, hematological, endocrinal, metabolic, neural, myopathic, and psychiatric), fluid or electrolyte imbalances, medications,

Table. Characteristics of the patients with Ogilvie's syndrome.

| Age | Gender | Associated problems | Symptom period | Symptoms | Signs | Cecal diameter | Treatment |
|-----|--------|---|----------------|--|---|----------------|---|
| 55 | Female | Diabetes mellitus | 7 days | Pain Distention Constipation | Tenderness Distention Hypoactivity Fever | 10 cm | Colonoscopy, Recurrence, Surgery |
| 40 | Female | Cesarean | 3 days | Pain Distention Constipation | Tenderness Distention Hypoactivity | 10 cm | Colonoscopy |
| 55 | Male | - | 2 days | Pain Distention Constipation Nausea | Tenderness Distention Hypoactivity | 11 cm | Colonoscopy |
| 76 | Male | Diabetes mellitus | 5 days | Pain Distention Constipation Nausea Vomiting | Tenderness Distention | 7 cm | Unsuccessful colonoscopy, Surgery |
| 58 | Female | Hysterectomy | 2 days | Pain Distention Diarrhea | Tenderness Distention Fever | 11 cm | Colonoscopy |
| 55 | Male | - | 3 days | Pain Distention Constipation | Tenderness Distention Hypoactivity | 9 cm | Neostigmine |
| 32 | Female | Epilepsy (Sodium valproate treatment) | 2 days | Pain Distention Constipation Nausea Vomiting | Tenderness Distention Hypoactivity Muscular rigidity Rebound Fever | 13 cm | Surgery |
| 52 | Male | - | 1 days | Pain Distention Diarrhea | Tenderness Distention Hypoactivity | 9 cm | Unsuccessful neostigmine, Colonoscopy |
| 42 | Female | Cesarean | 2 days | Pain Distention Constipation | Tenderness Distention | 11 cm | Colonoscopy |
| 70 | Male | Parkinsonism (Biperiden hydrochloride treatment) | 5 days | Pain Distention Constipation Nausea Vomiting | Tenderness Distention Hypoactivity Muscular rigidity Rebound | 13 cm | Surgery |
| 60 | Male | - | 3 days | Pain Distention Constipation | Tenderness Distention | 10 cm | Colonoscopy |
| 36 | Female | Drug intoxications (Amitraz) | 2 days | Pain Distention Constipation Nausea | Tenderness Distention Hypoactivity | 9 cm | Neostigmine |
| 34 | Female | Cesarean | 2 days | Pain Distention Constipation | Tenderness Distention | 8 cm | Colonoscopy |
| 36 | Male | Burn | 2 days | Pain Distention Constipation | Tenderness Distention Hypoactivity | 9 cm | Neostigmine |
| 48 | Male | Burn | 2 days | Pain Distention Constipation | Tenderness Distention Hypoactivity | 10 cm | Neostigmine |

intoxications, and radiotherapy may be the predisposing factors (1,4-7,10-17). Delgado-Aros and Camilleri (5) reported that, in 2 systematic reviews of ACPO cases from 1948 to 1980 and 1970 to 1985, 88% of 351 and 95% of 400 cases, respectively, had a recognizable associated underlying disorder. Our findings are compatible with the literature findings.

In ACPO, significant abdominal distention and abdominal silence are the common clinical features. Patients may continue to pass small amounts of flatus or stool, but it is generally inadequate (1-6,18). According to Delgado-Aros and Camilleri (5), up to 41% of patients still pass some gas or even present with diarrhea. Abdominal pain, tenderness, and low-grade fevers are also common. Nausea and vomiting are rare (1-6), and their presence varies from 0% to 71% (5). The presence of muscular rigidity, rebound phenomenon, or evident leukocytosis may be the signs of bowel ischemia, necrosis, and perforation (1-6). Our results are also compatible with these reports.

There are no specific alterations in laboratory tests of ACPO patients. They may show electrolyte imbalances or alterations due to underlying disorders, and an elevated white blood cell count. The latter was present in 100% of patients with bowel perforation and only in 27% of patients without ischemia or perforation (5). ACPO is basically a radiological diagnosis. Plain abdominal X-ray radiographs are generally diagnostic, with the demonstration of significant colonic distention, with minimal or no distention of the small intestine (4-6,19,20). Evidence of rapid cecal dilatation or a cecal diameter > 11-13 cm on abdominal X-ray radiographs has been associated with increased risk of cecal ischemia, necrosis, and perforation (1,3-5,11,12,20). On the other hand, endoscopy and contrast studies may be necessary to rule out any mechanical cause (1-5,19,21). Moreover, the performance characteristics of abdominal CT have not been evaluated in ACPO (5). In the present study, the diagnosis of ACPO was based on physical examination and radiological findings in all the patients, and the diagnosis was also supported by endoscopic examination or surgical treatment findings, as it was in earlier reports.

The differential diagnosis of ACPO is not easy. According to Chapman et al. (22), when air is present through all colonic segments on plain abdominal X-ray radiographs, ACPO can be differentiated from mechanical obstruction; however, when air is not demonstrable in

the rectosigmoid colon, the differentiation of both entities cannot be based on plain abdominal X-ray radiographs. In the retrospective reports about ACPO, which referred to colonoscopy, 5% to 9% of the cases were reported to have a mechanical obstruction, such as colonic malignancy, volvulus, or adhesion (5,18,23).

ACPO resolves spontaneously in a few days in most cases; thus, initial treatment is generally non-operative in patients with cecal diameters < 9 or 10 cm (2,5,6,14,15). This treatment consists of the restriction of oral intake, nasogastric decompression, rectal tube placement, correction of fluid or electrolyte abnormalities, discontinuation of medications that decrease colonic motility, and treatment of predisposing problems (1,4-7,10,24). Even though nasogastric decompression has been widely used, its role has not been clearly defined because the stomach and duodenum are not usually involved. Hence, use of a nasogastric tube may not be necessary unless there is significant vomiting (5). Serial plain X-ray radiographs should be reviewed every 12-24 h, depending on clinical course (1,5,6,19). In general, it seems that 30%-70% of patients may be successfully managed by conservative treatment, with a complication rate of 6% and a mortality of 10% (5,15,19). With treatment of potential underlying triggers, ACPO disappeared in 2-6 days in 83%-96% of the patients in the series reported by Delgado-Aros and Camilleri (5), and in 30% of the patients in the series described by Rajiv et al. (16).

Although some bowel stimulants, including vasopressin, urecholine, and neostigmine, have been used with variable success, neostigmine appears to offer the best medical option with high rates of treatment success and low toxicity. Neostigmine may be administered intravenously at a dose of 2.0-2.5 mg over a few minutes or 1 h, monitored by electrocardiography (4-6,8,13,16,24). In one randomized study by Ponc et al. (25), 91% of ACPO patients had resolution of the ileus with 2.0 mg intravenous neostigmine administration. Ould-Ahmed et al. (13), Rajiv et al. (16), Sgouros et al. (24), and Di Giorgio et al. (26) reported similarly successful results with neostigmine treatment; however, neostigmine treatment is not without morbidity, especially in elderly patients (4-6,8,16,24). The most frequent adverse events of neostigmine treatment are abdominal cramps in 17%, excessive salivation in 13%, sweating in 4%, nausea, vomiting in 4%, and transient

bradycardia in 6% of cases (5). Delgado-Aros and Camilleri (5) reported the following contraindications for neostigmine: heart rate < 60 bpm and/or systolic blood pressure < 90 mmHg; active bronchospasm; serum creatinine concentration > 3 mg/dl; signs of bowel perforation. In the present study, in addition to conservative treatment, neostigmine infusion resulted in prompt resolution of ACPO in 4 out of 5 patients, while neostigmine treatment was unsuccessful in one patient, who was subsequently treated with colonoscopy. Although conservative treatment and medical treatment are considered to be different treatment methods, and conservative treatment is continued for a few days, we used this treatment alone for 24 h, and then we added medical or endoscopic treatment. Therefore, the success of conservative treatment alone could not be evaluated.

In the treatment of ACPO, contrast enema with water-soluble contrasts, like cystografin or gastrografen, is potentially therapeutic because it induces peristalsis, but it should be avoided if perforation is suspected (4-6,27,28). Another therapeutic alternative may be spinal or epidural anesthesia with low-dose bupivacaine (0.25%-0.5%), and blockade of the superior splanchnic nerve may be expected to result in sympathectomy (4-6,29,30). We do not have any experiences with these treatment methods.

During the conservative treatment of ACPO, if the cecal diameter continues to increase and exceeds 12 or 13 cm, or if there is no improvement in 48-72 h, the colon should be decompressed by colonoscopy (1,2-5). A successful decompression can be achieved with passage to the cecum or the hepatic flexure. The lumen should be collapsed by applying intermittent suction as the endoscope is withdrawn. If desired, a tube can be left in

the ascending colon (2-5), and when required a second colonoscopic decompression may be performed. The success rate of colonoscopic decompression is reported to vary between 70% and 90%, and the recurrence rate is between 10% and 30% (1,2,4-6,9,21). Delgado-Aros and Camilleri (5) reported 0.2%-2% perforation, and 13%-32% mortality rates for colonoscopy. On the other hand, ACPO tends to recur in some cases and Grassi et al. (20) reported a 33% recurrence rate. In our study 9 patients were treated with colonoscopy; the success rate was 88.9% and the recurrence rate was 12.5%.

In ACPO, surgical treatment is indicated whenever cecal ischemia, necrosis, and perforation are clinically suspected, or on the basis of colonoscopic examination. Progression of cecal distention or failure of resolution after several days of aggressive treatment is a relative indication (1-6,14). Cecostomy is successful in the absence of ischemia, necrosis, and perforation (1,3,5,6,12,31,32). If the bowel is ischemic, necrotic, and perforated, resection with or without anastomosis is required, but is generally associated with 35%-60% mortality rates (4-6,14,19,24,31,33). Cecostomy can also be accomplished either laparoscopically or percutaneously (5,6,32,34). In our series, tube cecostomy was performed in 4 patients with open surgery. There was no mortality in this surgery group, and wound infection developed in only one patient.

In conclusion, initial treatment of ACPO is conservative, and neostigmine treatment may be used successfully. Decompression colonoscopy can also be performed safely and successfully. Surgical treatment is needed when colonoscopy is unsuccessful or when cecal ischemia, necrosis, or perforation is suspected. Cecostomy may be successful if the bowel is viable.

References

1. Kodner IJ, Fry RD, Fleshman JW, Birnbaum EH, Read TE. Colon, rectum and anus. In: Schwartz SI, Shires GT, Daly JM, Fischer JE, Galloway AC, editors. Principles of Surgery, 7th ed. New York: McGraw Hill; 1999, p.1275.
2. Fink AS. Endoscopy. In: Zinner MJ, Schwartz SI, Ellis H, Arstley SW, McFadden DW, editors. Maingot's Abdominal Operations, 10th ed. Stamford: Appleton and Lange; 1997, p.224.
3. Rolandelli RH. Diarrhea and constipation. In: Zinner MJ, Schwartz SI, Ellis H, Arstley SW, McFadden DW, editors. Maingot's Abdominal Operations, 10th ed. Stamford: Appleton and Lange; 1997, p.347.
4. Saclarides TJ, Harrison J. Pseudo-obstruction (Ogilvie's syndrome). In: Fazio VW, Church JM, Delaney CP, editors. Current Therapy in Colon and Rectal Surgery, 2nd ed. Philadelphia: Elsevier Mosby; 2005, p.321-326.
5. Delgado-Aros C, Camilleri M. Pseudo-obstruction in the critically ill. Best Prac Res Clin Gastroenterol 2003; 17: 427-444.
6. Senagore AJ. Ogilvie: I remember that name. Current Surgery 2001; 58: 345-349.

7. Rondeau M, Weber JC, Nodot I, Storck D. Etiology and prognosis of acute colonic pseudo-obstruction: a retrospective study in an internal medicine unit. *Rev Med Interne* 2001; 22: 536-541.
8. Ponec RJ, Saunders MD, Kimmey MB. Neostigmine for the treatment of acute colonic pseudo-obstruction. *N Engl J Med* 1999; 341: 137-141.
9. Strodel WE, Nostrant TT, Eckhauser FE, Dent TL. Therapeutic and diagnostic colonoscopy in nonobstructive colonic dilatation. *Ann Surg* 1983; 197: 416-421.
10. Aslan S, Bilge F, Aydinli B, Ocak T, Uzkeser M, Erdem AF et al. Amitraz: an unusual aetiology of Ogilvie's syndrome. *Hum Exp Toxicol* 2005; 24: 481-483.
11. Jani PG. Acute colonic pseudo obstruction (Ogilvie's syndrome): case report. *East Afr Med J* 2005; 82: 325-328.
12. Pokorny H, Plochl W, Soliman T, Herneth AM, Scharitzer M, Pokieser P, Berlakovich GA, Muhlbacher F. Acute colonic pseudo obstruction (Ogilvie's syndrome) and pneumatosis intestinalis in a kidney recipient patient. *Wiener Klinische Wochenschrift* 2003; 115: 732-735.
13. Ould-Ahmed M, de Saint-Martin L, Ansart S, Renault A, Boles JM. Acute colonic pseudo obstruction (Ogilvie's syndrome) in pneumococcal meningo-encephalitis treated with neostigmine. *Annales Francaises D Anesthesie et de Reanimation* 2003; 22: 900-903.
14. Singh S, Nadgir A, Bryan RM. Post-cesarean section acute colonic pseudo-obstruction with spontaneous perforation. *Int J Gynecol Obstet* 2005; 89: 144-145.
15. Attarbashi S, Yadav Y, Ahmad G. Intestinal pseudoobstruction (Ogilvie's syndrome) following cesarean delivery. *Int J Gynecol Obstet* 2006; 94: 133-134.
16. Rajiv M, Anil J, Prem N, Raj VV, Mustafa CP, Deepak S, Balakrishnan, V. Factors predicting successful outcome following neostigmine therapy in acute colonic pseudo-obstruction: A prospective study. *J Gastroenterol and Hepatol* 2006; 21: 459-461.
17. Kakarla A, Posnett H, Jain A, Ash A. Acute pseudo-obstruction of the colon (Ogilvie's syndrome) following instrumental vaginal delivery. *Int J Clin Pract* 2006; 60: 1303-1305.
18. Fazel A, Verne GN. New solutions to an old problem: Acute colonic pseudo-obstruction. *J Clin Gastroenterol* 2005; 39: 17-20.
19. Pham TN, Comsan BC, Chu P, Savides TJ. Radiographic changes after colonoscopic decompression for acute pseudo-obstruction. *Dis Colon Rectum* 1999; 42: 1586-1591.
20. Grassi R, Cappabianca S, Porto A, Sacco M, Montemarano E, Quarantelli M, Di Mizio R, De Rosa R. Ogilvie's syndrome (acute colonic pseudo-obstruction): review of the literature and report of 6 additional cases. *Radiologia Medica* 2005; 109: 370-375.
21. Wegener M, Borsch G. Acute colonic pseudo-obstruction (Ogilvie's syndrome): Presentation of 14 our own cases and analysis of 1027 cases reported in the literature. *Surg Endosc* 1987; 1: 169-174.
22. Chapman AH, McNamara M, Porter G. The acute contrast enema in suspected large bowel obstruction: value and technique. *Clinical Radiology* 1992; 46: 273-278.
23. Mongardini M, Schillaci F, Cola A, Fanello G, Benedetti F, Maturo A, Pappalardo G. Adhesion ileus in patient with previous diagnosis of Ogilvie's syndrome. *G Chir* 2005; 26: 318-320.
24. Sgouros SN, Vlachogiannakos J, Vassiliades K, Bergele C, Stefanidis G, Nastos H, Avgerinos A, Mantides A. The effect of polyethylene glycol electrolyte balanced solution on patients with acute colonic pseudoobstruction after the resolution of colonic dilatation: a prospective, randomised, placebo-controlled trial. *Gut* 2006; 55: 638-642.
25. Ponec RJ, Saunders MD, Kimmey MB. Neostigmine for the treatment of acute colonic pseudo-obstruction. *N Eng J Med* 1999; 341: 137-141.
26. Di Giorgio R, Stanghellini V, Barbara G, Guerrini S, Lioce A, Vasina V, Tonini M, Cola B, Corinaldesi R, De Ponti F. Prokinetics in the treatment of acute intestinal pseudo-obstruction. *Idrugs* 2004; 7: 160-165.
27. Schermer CR, Hanosh JJ, Davis M, Pitcher DE. Ogilvie's syndrome in the surgical patient: A new therapeutic modality. *J Gastrointest Surg* 1999; 3: 173-177.
28. Jones C, Mitre R, Cobb C, Frame K, Agrawal R, Brodmerkel GJ. Gastrografin as a primary treatment modality for Ogilvie's syndrome. *Gastroenterology* 1996; 112: 756.
29. Lee JT, Taylor BM, Singleton BC. Epidural anesthesia for acute pseudo-obstruction of the colon (Ogilvie's syndrome). *Dis Colon Rectum* 1988; 31: 686-691.
30. Mashour GA, Peterfreund RA. Spinal anesthesia and Ogilvie's syndrome. *J Clin Anesth* 2005; 17: 122-123.
31. Catena F, Caira A, Ansaloni L, Calo G, De Bonis F, Agrusti S, D'Alessandro L, Taffurelli M. Ogilvie's syndrome treatment. *Acta Biomed Ateneo Parmense* 2003; 74: 26-29.
32. Chevallier P, Marcy PY, Francois E, Peten EP, Motamedi JP, Padovani B, Bruneton JN. Controlled transperitoneal percutaneous cecostomy as a therapeutic alternative to the endoscopic decompression for Ogilvie's syndrome. *Am J Gastroenterol* 2002; 97: 471-474.
33. Reverdy D, Gebhart M, Kothionidis K, Gallez J, De Becker D, Liberale G. Pseudo-colonic obstruction after lumbar spine surgery: a case report. *Acta Orthop Belg* 2006; 72: 769-771.
34. Lynch CR, Jones RG, Hilden K, Wills JC, Fang JC. Percutaneous endoscopic cecostomy in adults: a case series. *Gastrointest Endosc* 2006; 64: 279-282.