

## Anesthesia for an Adult Patient with Congenital Diaphragmatic Eventration

Hale YARKAN UYSAL

Solmaz GÜNAL

Ahmet Ş. UYAR

Hülya BAŞAR

**Abstract:** Congenital diaphragmatic eventration is an uncommon condition in adults and is defined as an abnormal elevation of the diaphragm.

In adults, diaphragmatic eventration causes respiratory impairment that is associated with severe dyspnea, orthopnea and hypoxia. Most of the symptomatic patients may survive with supportive therapy without any need for surgical correction, though they are at risk of spontaneous diaphragm rupture. Spontaneous diaphragmatic rupture may develop in a patient with diaphragmatic eventration as a result of any event that leads to increase in intraabdominal pressure.

In this case report, we present the anesthetic management of an adult patient with congenital diaphragmatic eventration undergoing craniotomy operation.

**Key Words:** Congenital diaphragmatic eventration, anesthesia, craniotomy

Department of Anesthesiology and  
Reanimation Clinic,  
Ankara Training and  
Research Hospital,  
Ankara - TURKEY

### Kraniyotomi Operasyonu Geçiren Konjenital Diyafragma Eventrasyonlu Hastada Anestezik Yaklaşım

**Özet:** Erişkinlerde konjenital diyafragma eventrasyonu nadir karşılaşılan bir durum olup, diyaframanın anormal yüksekliği olarak tanımlanmaktadır.

Yetişkinlerde diyafragma eventrasyonu ciddi dispne, ortopne ve hipoksi sonucu gelişen solunumsal bozukluklara neden olur. Semptomatik hastaların çoğu destekleyici tedaviyle cerrahi onarıma gerek kalmadan yaşamlarını sürdürse de spontan diyafragma rüptürü açısından risk altındadırlar. Spontan diyafragma rüptürü diyafragma eventrasyonu olan hastalarda intra-abdominal basınç artışına neden olabilecek herhangi bir olay sonucunda gelişebilir.

Bu olgu sunumunda intrakraniyal kitle operasyonu geçirecek diyafragma eventrasyonlu erişkin hastada anestezik yaklaşımı sunmayı amaçladık.

**Anahtar Sözcükler:** Konjenital diyafragma eventrasyonu, Anestezi, Kraniyotomi

### Introduction

Diaphragmatic eventration is defined as an abnormal elevation of the whole diaphragm or some part of it, caused by paralysis, aplasia or atrophy of muscular fibers of the diaphragm (1). Diaphragmatic eventration is rarely encountered and can be either congenital (non-paralytic) or acquired (paralytic). Congenital eventration develops in fetal life as a result of absent or insufficient muscularization of the pleuroperitoneal membrane. Pleural and peritoneal cavities are separated from each other by the diaphragm and the phrenic nerve is intact. Congenital eventration may be associated with other congenital abnormalities (2). Anatomically, congenital eventration has three forms: partial, complete and bilateral. Partial eventration is frequently located anteromedially to the right hemidiaphragm whereas complete eventration is generally located at the left hemidiaphragm (3). Acquired diaphragmatic eventration is associated with phrenic nerve injury caused by childbirth or major abdominal surgery. Neurological disorders, myopathies or lesions of the neighboring organs can cause acquired eventration by altering diaphragm levels (4). The diagnosis of diaphragmatic eventration is generally confirmed by anteroposterior chest radiography and fluoroscopy, though

Received: June 12, 2007  
Accepted: October 05, 2007

#### Correspondence

Hale YARKAN UYSAL  
Çetin Emeç Bulvarı,  
Ceyhan Atif Kansu Caddesi,  
11. Sokak, 8/7  
Balgat, Ankara - TURKEY

haleuysal@gmail.com

computerized thorax tomography, pulmonary function tests and ultrasonography can be helpful in further diagnosis (5). In this case report, we present the anesthetic management of an adult patient suffering from intracranial meningioma and congenital diaphragmatic eventration.

### Case Report

A 79-year-old woman was scheduled to undergo craniotomy because of olfactory meningioma. Her medical history revealed frequent pulmonary infections, hypertension, coronary vascular disease and congestive heart failure and diaphragmatic eventration. She was receiving lisinopril, hydrochlorothiazide and digoxin 0.25 mg once a day orally. The planned operation was postponed due to pneumonia development. After 10 days of medical treatment, the operation was rescheduled. Her preoperative blood pressure was 180/110 mmHg and heart rate was 115 min<sup>-1</sup>. Blood pressure could be measured after 4 mg of metoprolol administration. The operation was postponed once again for blood pressure regulation.

After two weeks, the patient's blood pressure returned to normal values with ACE inhibitor and furosemide therapy and she was scheduled for the operation for the third time. In the preoperative evaluation, her blood pressure was 140/80 mmHg, heart rate was 80 beats min<sup>-1</sup> and respiratory rate was 12 breaths min<sup>-1</sup>. Examination of the chest revealed diminished pulmonary sounds and apparent bowel sounds at the lower part of the right hemithorax.

Laboratory examinations displayed normal values except slightly increased urea (54.2 mg dl<sup>-1</sup>) and creatinine (1.22 mg dl<sup>-1</sup>). Anteroposterior chest radiography (Figure 1) showed elevation of the right diaphragm and computerized thorax tomography (Figure 2) showed the high position of the right hemidiaphragm and bowel segments reaching up to the carina at the anterior part of the right hemidiaphragm. Electrocardiography revealed atrial fibrillation with a normal heart rate and echocardiography showed 2° mitral valve insufficiency; ejection fraction rate was 45% and mean pulmonary arterial tension was 30 mmHg.

Arterial blood analysis showed a pH of 7.46, arterial carbon dioxide tension ( PaCO<sub>2</sub>) of 37.5 mmHg, arterial oxygen tension (PaO<sub>2</sub>) of 72.7 mmHg and oxyhemoglobin

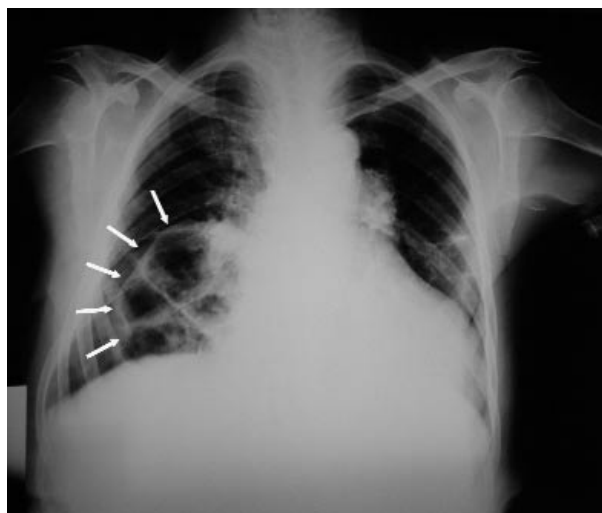


Figure 1. Anteroposterior chest X-ray.

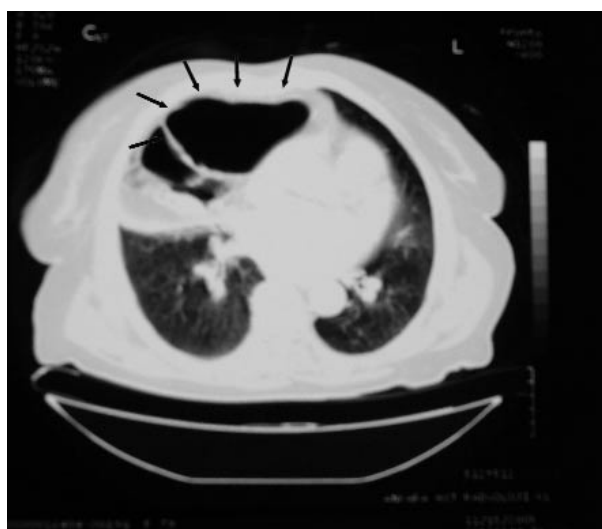


Figure 2. CT scan of the thorax indicating diaphragmatic eventration.

saturation of 99.3% when breathing room air. Pulmonary function tests could not be performed because of the discordance of the patient.

The patient was premedicated with oral 10 mg diazepam 1 h before the surgery. In the operating room, routine monitoring of electrocardiography, non-invasive blood pressure and pulse oximetry were performed. Her blood pressure was 140/93 mmHg, and heart rate was 72 beats min<sup>-1</sup>. Her oxyhemoglobin saturation was 93% when breathing room air. After preoxygenation with

100% oxygen for 5 mins at 25° head up position, anesthesia induction was performed using 1  $\mu\text{g kg}^{-1}$  iv lidocaine, 3  $\text{mg kg}^{-1}$  etomidate, 1.5  $\text{mg kg}^{-1}$  fentanyl and 0.1  $\text{mg kg}^{-1}$  vecuronium. The trachea was intubated and the patient was mechanically ventilated with the pressure-controlled mode (pressure-controlled ventilation at 15  $\text{cm H}_2\text{O}$ , PEEP 5  $\text{cm H}_2\text{O}$ , respiratory rate 12 breaths  $\text{min}^{-1}$ ) to maintain the end-tidal carbon dioxide ( $\text{ETCO}_2$ ) tension between 30-35 mmHg. Anesthesia was maintained with 4-5% desflurane in 100% oxygen at a total fresh gas flow of 2  $\text{L min}^{-1}$ .

An arterial catheter was inserted into the radial artery for continuous blood pressure monitoring. Central venous pressure (CVP) was monitored with a central catheter placed percutaneously via the left brachial vein. The patient's initial CVP was 7  $\text{cm H}_2\text{O}$ . 0.9% NaCl was infused during the surgery and her blood pressure remained between 140/90 and 100/65 mmHg and her heart pulse rate between 68  $\text{min}^{-1}$  and 60  $\text{min}^{-1}$ . Oxyhemoglobin saturation was 97% or higher. Measured CVP values were between 7-10  $\text{cm H}_2\text{O}$ . The operation lasted approximately 3.5 hours. Tramadol (1  $\text{mg kg}^{-1}$ ) was given 15 mins before extubation for postoperative analgesia. At the end of the operation, the patient was extubated and transferred to the neurosurgical intensive care unit with a oxyhemoglobin saturation of 96% when breathing room air.

Arterial blood analysis showed a pH of 7.49,  $\text{PaO}_2$  of 63.5 mmHg,  $\text{PaCO}_2$  of 31.9 mmHg, and oxyhemoglobin saturation of 93.6% when breathing room air in the intensive care unit, during the early postoperative period. 100% oxygen therapy via face-mask was applied to the patient. On the second and third postoperative days, her arterial blood analysis values were normal and oxygen therapy was terminated. On the ninth day after the surgery, she was discharged home without any complications.

## Discussion

Anesthetic management of diaphragmatic eventration in adults is poorly described in the literature. As it is an extremely rare condition, during preoperative evaluation, the diagnosis may not be established only by examination of the chest radiograph. In this case, we had the opportunity to prepare for possible difficulties and complications that are expected in this situation, since the

diagnosis of diaphragmatic eventration was established and confirmed in this patient before craniotomy.

In newborns and infants, diaphragmatic eventration results in life-threatening symptoms such as respiratory distress, therefore it should be corrected surgically (6). In adults, the symptoms are mild. In some adult patients, severe dyspnea, orthopnea, hypoxia and reduction in lung volumes can be seen. Repeated chest infections, gastrointestinal disorders and palpitation may exist due to the mass effect of the diaphragmatic eventration (7). In symptomatic adult patients, oxygen therapy, upright positioning and antibiotherapy for the control of the infections may be necessary for the treatment. If the patient does not respond to supportive treatment, surgical correction must be performed (6). Our case had a history of several hospitalizations for respiratory distress caused by repeated pulmonary infections, but she responded each time to supportive therapy without any need for surgical correction for diaphragmatic eventration.

The principals of anesthetic management of cases with diaphragmatic eventration resemble those in management of diaphragmatic hernia. Large gauge intravenous access should be gained, and arterial and CVP monitoring should be considered. Any event that leads to increase in intraabdominal pressure, such as coughing, straining during light anesthesia or extubation, may result in sudden diaphragmatic rupture (7). When the eventration of the diaphragm changes into a true rupture, by the mass effect of the abdominal viscera relocating into the intrathoracic cavity, direct compression of the heart and mediastinal shift may occur. Kinking in the vena cavae and pulmonary veins caused by the mass effect impairs venous return to the heart and decreases cardiac output (8).

In order to prevent the rupture of the diaphragm, a deep level of anesthesia should be maintained in these patients undergoing surgery, especially during induction and extubation periods. Mask ventilation and nitrous oxide use should be avoided in these patients, as the expansion of intraabdominal viscera can impair the circulation and respiration (9).

There are only two cases of spontaneous rupture of diaphragmatic eventration in the literature. In one of these, Faheem and Fayad (7) reported a case of spontaneous diaphragmatic rupture after lower limb

surgery with epidural anesthesia. The probable mechanism of the rupture was explained by the increased workload of the diaphragm due to high regional anesthesia. In an animal experimental study, Polaner et al. (10) showed the shift of the workload of breathing from the ribcage to diaphragm under thoracic epidural anesthesia.

In conclusion, congenital diaphragmatic eventration is a rare condition in adults, and meticulous management in general or regional anesthesia should be considered. Although regional anesthesia seems to be advantageous compared to general anesthesia, high levels of regional

block may cause paresis of the intercostal muscles, which can increase the workload of the diaphragm and lead to diaphragmatic rupture. In order to prevent high block levels in regional anesthesia practices, titration of local anesthetic drugs should be calculated carefully. General anesthesia was preferred in this patient because this type of neurosurgery is performed under general anesthesia as a standard procedure. For the patients undergoing general anesthesia, precautions should be taken to prevent the increase in intraabdominal pressure, especially during the induction and extubation periods, in order to reduce the risks.

## References

1. Arensman RM, Bambini DA. Congenital diaphragmatic hernia and eventration. In: Ashcraft KW, Murphy JP, Sharp RJ, Sigalet DL, Snyder CL, editors. *Pediatric Surgery*. 3rd ed. Philadelphia: W. B. Saunders; 2000. pp. 300-17.
2. Obara H, Hoshina H, Iwai S, Ito H, Hisano K. Eventration of the diaphragm in infants and children. *Acta Paediatr Scand* 1987; 76: 654-8.
3. Jawad AJ, al-Sammarai AY, al-Rabeeah A. Eventration of the diaphragm in children. *J R Coll Surg Edinb* 1991; 36: 222-4.
4. Singh G, Bose SM. Agenesis of hemidiaphragm in adults (review). *Aust N Z J Surg* 1993; 63: 327-8.
5. Yazici M, Karaca I, Arikan A, Eriksi V, Etensel B, Temir G et al. Congenital eventration of the diaphragm in children: 25 years' experience in three pediatric surgery centers. *Eur J Pediatr Surg* 2003; 13: 298-301.
6. Commare MC, Kurstjens SP, Barois A. Diaphragmatic paralysis in children: a review of 11 cases. *Pediatr Pulmonol* 1994; 18: 187-93.
7. Faheem M, Fayad A. Diaphragmatic rupture after epidural anaesthesia in a patient with diaphragmatic eventration. *Eur J Anaesthesiol* 1999; 16: 574-6.
8. Katz RI, Belenker SL, Poppers PJ. Intraoperative management of a patient with a chronic, previously undiagnosed traumatic diaphragmatic hernia. *J Clin Anesth* 1998; 10: 506-9.
9. Williams DJ, Sandby-Thomas MG. Anaesthetic management of acute gastric volvulus in an adult. *Br J Anaesth* 2003; 90: 96-8.
10. Polaner DM, Kimball WR, Fratacci MD, Wain JC, Zapol WM. Thoracic epidural anesthesia increases diaphragmatic shortening after thoracotomy in the awake lamb. *Anesthesiology* 1993; 79: 808-16.