

Rare Complication of Meckel's Diverticulum: Loop Formation of Diverticulum

Oğuzhan KARATEPE¹

Cem DURAL²

Candaş ERÇETİN²

Gamze ÇITLAK²

Artur SAMASLIOĞLU³

Osman Bilgin GÜLÇİÇEK¹

Servet KARAHAN¹

Abstract: Meckel's diverticulum is the most prevalent congenital anomaly of the gastrointestinal tract, and is reported to occur in 1%-3% of the general population and autopsy series. The total lifetime rate of complications is widely accepted at 4%. Intestinal obstruction is the most common complication in adult patients. We present the diagnosis and management of our patient with intestinal obstruction due to loop formations of a Meckel's diverticulum.

Key Words: Meckel's diverticulum, obstruction, complication

Meckel Divertikülünün Nadir Bir Komplikasyonu: Divertikülün Halka Formasyonu

Özet: Meckel divertikülü otopsi serilerinde ve genel popülasyonda %1-%3 sıklığında rastlanılan en yaygın gastrointestinal sistem anomolisidir. Divertiküllü hastalarda yaşam boyunca komplikasyon görülme oranı %4'tür. En sık görülen komplikasyonu erişkinde barsak tıkanıklığıdır. Biz tanı ve tedavisi Meckel divertikülünün halka oluşumuna bağlı intestinal tıkanıklık olan hastayı sunmayı uygun gördük.

Anahtar Sözcükler: Meckel divertikülü, tıkanıklık, komplikasyon

¹ Department of General Surgery, Okmeydanı Training and Research Hospital, İstanbul - TURKEY

² Department of General Surgery, İstanbul Medical Faculty, İstanbul University, İstanbul - TURKEY

³ Department of Radiology, İstanbul Medical Faculty, İstanbul University, İstanbul - TURKEY

Introduction

Meckel's diverticulum is the most common congenital anomaly of the gastrointestinal tract, occurring in 2%-3% of the population (1,2). In the majority of patients, Meckel's diverticulum is asymptomatic (2-4). Many Meckel diverticula are discovered incidentally during a radiologic evaluation or surgical procedure performed for other reasons or they are found at autopsy (3,4). Hemorrhage, small intestinal obstruction, and diverticulitis are the most frequent complications. Preoperative diagnosis of a complicated Meckel's diverticulum may be challenging because clinical and imaging features overlap with those of other acute inflammatory conditions in the abdomen (2-4).

The most common obstruction is intussusception with the Meckel's diverticulum being the lead point. Other causes of obstruction include volvulus around fibrous bands adherent to the umbilicus, Littre's hernias and diverticular strictures, and loop formations of Meckel's diverticulum (5-7). We present the diagnosis and management of our patient with intestinal obstruction due to loop formations of a Meckel's diverticulum.

Received: July 02, 2007
Accepted: January 26, 2008

Correspondence

Oğuzhan KARATEPE
Department of General Surgery,
Okmeydanı Training and
Research Hospital,
İstanbul - TURKEY

drkaratepe@yahoo.com

Case Report

A 32-year-old man with no previous abdominal surgery presented with a 48-hour history of abdominal pain, nausea and vomiting. Examination of the abdomen showed marked distension with peritonitis. No masses were palpable. There was no significant medical history. His body temperature was 37.5 °C. Laboratory findings showed a white blood cell count of 15,600, hemoglobin 12.3 g/dl, and platelets 200,000. All other studies, including electrolytes and urinalysis, were within normal limits. An abdominal

plain roentgenogram showing an air fluid level of the small intestine and computed tomography (CT) showing marked dilatation of the small intestine suggested the obstruction was near the end of the ileum (Figure 1). The patient was diagnosed as having ileus and a nasal decompression was performed. The patient was taken to the operating room for emergency laparotomy, and the distal part of the ileum was markedly dilated and formed a loop, clasped at its base by a loop-like structure located 60 cm proximal to the end of the ileum (Figure 2). After

separating the structure from the mesentery, it proved to be Meckel's diverticulum, the end of which was adhered to the corresponding dorsal mesentery. The ileal loop was released from the diverticulum (Figure 3). A resection of the necrotic segment and Meckel's diverticulum and functional end to end anastomosis of the bowel were completed. The diverticulum was confirmed as Meckel's diverticulum by histological examination. The patient recovered without incident and was discharged after five days in hospital.

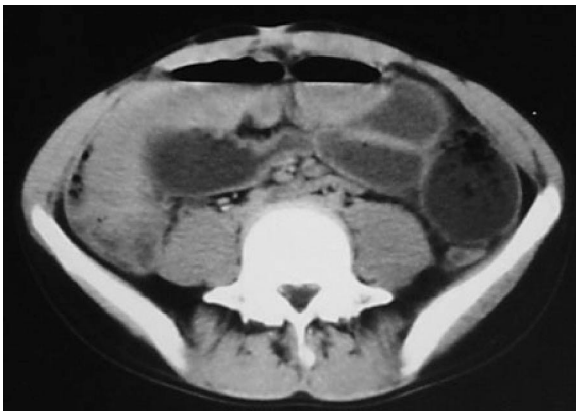


Figure 1. CT examination revealed the presence of distended jejunal and ileal bowel loops. Colonic loops were not dilated and were partially compressed by fluid-filled intestinal loops. The findings suggested the diagnosis of ileus due to obstruction at the ileal level but the cause of the obstruction could not be demonstrated.

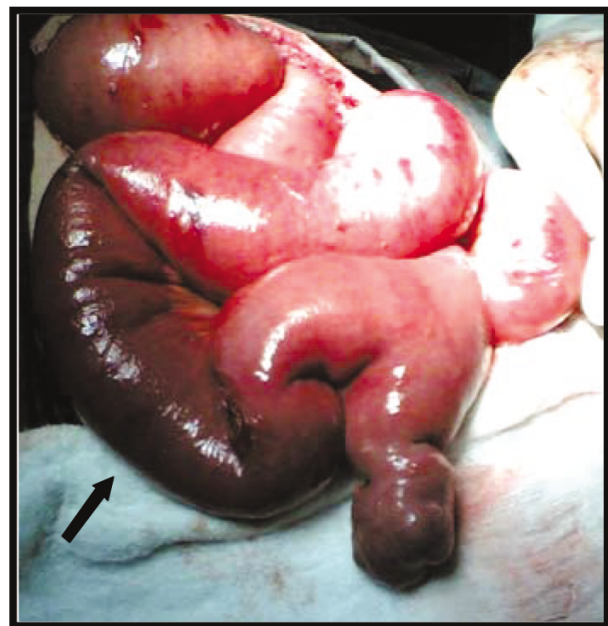

Figure 3. Meckel's diverticulum and necrotic ileal segment (arrow).

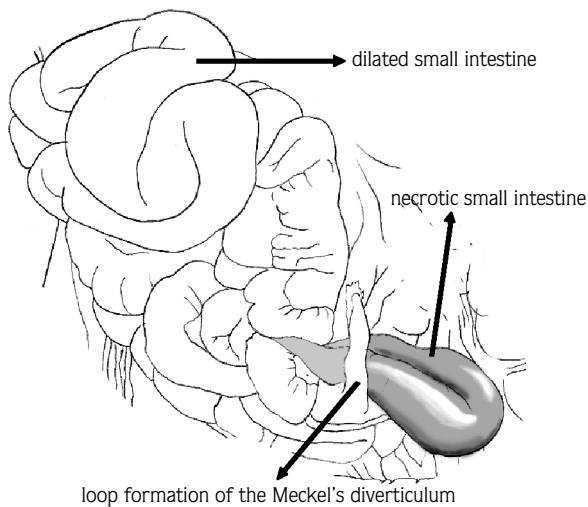


Figure 2. Schema of the loop formation of the Meckel's diverticulum.

Discussion

Meckel's diverticulum is the most common end result of the spectrum of omphalomesenteric duct anomalies, which also include umbilico-ileal fistula, omphalomesenteric duct sinus, omphalomesenteric duct cyst, fibrous connection of the ileum to the umbilicus, and Meckel's diverticulum. Meckel's diverticulum is the most common (98% of cases) of the omphalomesenteric duct anomalies. The diverticulum is usually found within 100 cm of the ileocecal valve on the antimesenteric border of the ileum (1-3).

In the majority of patients, Meckel's diverticulum is asymptomatic, and the diagnosis is difficult to establish preoperatively. Heterotopic gastric and pancreatic mucosa are frequently found histologically within the diverticula of symptomatic patients (4,5).

The complications of Meckel's diverticulum are hemorrhage, intestinal obstruction, and diverticulitis. Intestinal obstruction is the second most common complication of Meckel's diverticulum (5). There are many mechanisms for small intestinal obstruction from a Meckel's diverticulum. It may produce obstruction by diverticular inversion causing luminal obstruction or leading to an intussusception; volvulus from persistent attachment to the umbilicus, adhesions, or congenital meso-diverticular bands; diverticulitis; foreign body impaction; inclusion of the diverticulum into a hernia; neoplasm; or formation of a loop (5-7). We present a patient with intestinal obstruction due to loop formation of a Meckel's diverticulum. The important aspect of our case is that the patient is an adult. The case presented by Tomikawa (7), which was caused by almost the same

mechanism as in our case, was also seen in adulthood. However, there is insufficient evidence in the literature to state with certainty that the obstructive case with loop formation is seen in adulthood.

Ultrasonography and CT are performed for evaluation of patients with acute symptoms. Therefore, while it is difficult to use CT to accurately identify a Meckel's diverticulum as the cause of intestinal obstruction, CT is an invaluable imaging modality for the evaluation of patients with intestinal obstruction (4). The operation should always include resection of the diverticulum or the segment of the bowel affected by the pathology (1,2).

In conclusion, although relatively rare, the complications of Meckel's diverticulum should be included in the differential diagnosis of small bowel obstruction.

References

1. Turgeon DK, Barnett JL. Meckel diverticulum. *Am J Gastroenterol* 1990; 85: 777-81.
2. Arnold JF, Pellicane JV. Meckel's diverticulum: a ten-year experience. *Am Surg* 1997; 63: 354-5.
3. Yahchouchy EK, Marano AF, Etienne JC, Fingerhut AL. Meckel's diverticulum. *J Am Coll Surg* 2001; 192: 658-62.
4. Levy AD, Hobbs CM. From the archives of the AFIP. Meckel diverticulum: radiologic features with pathologic correlation. *Radiographics* 2004; 24: 565-87.
5. Dumper J, Mackenzie S, Mitchell P, Sutherland F, Quan ML, Mew D. Complications of Meckel's diverticula in adults. *Can J Surg* 2006; 49: 353-7.
6. Karadeniz Cakmak G, Emre AU, Tascilar O, Bektas S, Ucan BH, Irkorucu O et al. Lipoma within inverted Meckel's diverticulum as a cause of recurrent partial intestinal obstruction and hemorrhage: a case report and review of literature. *World J Gastroenterol* 2007; 13: 1141-3.
7. Tomikawa M, Taomoto J, Saku M, Takeshita M, Yoshida K, Sugimachi K. A loop formation of Meckel's diverticulum: a case with obstruction of the ileum. *Ulus Travma Acil Cerrahi Derg* 2003; 9: 134-6.