

Transient Fetal and Neonatal Ascites: A New Finding of Down Syndrome?

Nurdan URAS¹
Semra KARA¹
Alpaslan TONBUL¹
Melike METİN³
Tuğba HALICI²
Mustafa Mansur TATLI¹
Ahmet KARADAĞ¹

Transient fetal ascites is a rare condition caused by many different underlying abnormalities, and can occur with both immunologic and non-immunologic hydrops. Its etiology includes chromosomal anomalies, intrauterine infections, and genitourinary, gastrointestinal, and cardiac malformations (1).

A newborn delivered at 38 weeks of gestational age was admitted to our department with respiratory distress and cyanosis. Polyhydramnios was detected at the 37th gestational week. In addition, the fetus was noted to have gross ascites, but no other abnormality was seen (Figure 1). The female infant was born via an uncomplicated spontaneous vaginal delivery, weighed 3300 g, and had external features consistent with Down syndrome. Left sided choanal atresia and diastasis recti were also noted. Gross ascites that contained fibrous septations was detected with abdominal ultrasonography (Figure 2). Serological test results for infections in the maternal and fetal blood, fetal

¹ Division of Neonatology,
Department of Pediatrics,
Faculty of Medicine,
Fatih University, Ankara - TURKEY

² Department of Pediatrics,
Faculty of Medicine,
Fatih University,
Ankara - TURKEY

³ Department of Radiology,
Faculty of Medicine,
Fatih University,
Ankara - TURKEY

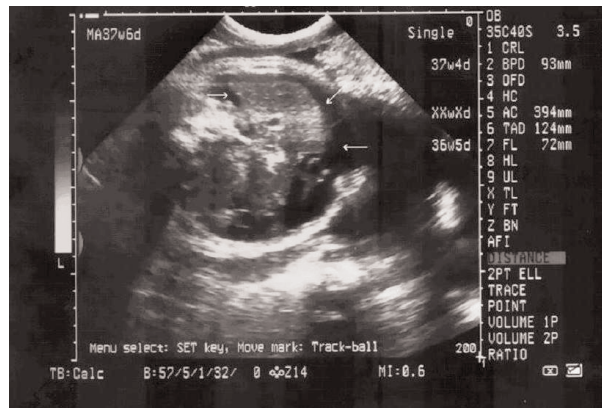

Figure 1. Ascites in the abdominal cavity during the antenatal period (white arrows).

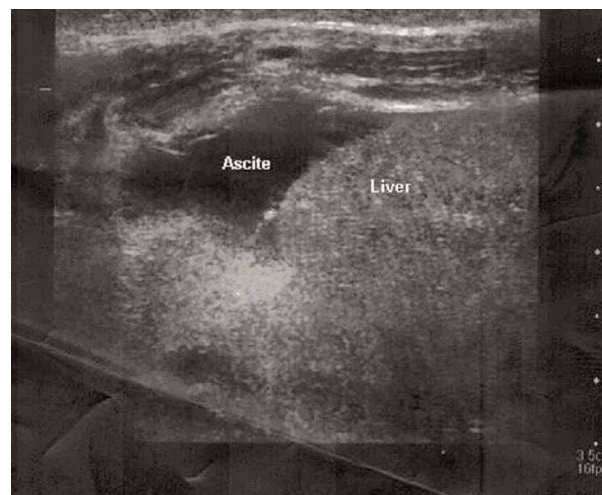


Figure 2. Postnatal abdominal ultrasound image showing ascites.

Received: March 13, 2008
Accepted: April 02, 2008

Correspondence

Ahmet KARADAĞ
Department of Pediatrics,
Faculty of Medicine,
Fatih University,
Hoşdere Cad. No: 145,
Y. Ayrancı, Çankaya
06540 Ankara, TURKEY

ahmetkaradag@gmail.com

ascites, and amniotic fluid (herpes simplex virus types 1 and 2, cytomegalovirus, Epstein-Barr virus, hepatitis A, B, and C virus, parvovirus B19, varicella, rubella, toxoplasmosis) were negative. Karyotype analysis revealed 47, XX non-disjunctional trisomy 21. At the follow-up examination gross ascites had resolved spontaneously and only a trace of ascites fluid was observed during the abdominal ultrasound examination. The baby is now 2 months old and remains in good health, with no recurrence of ascites.

Fetal ascites has been reported in association with a wide range of pathologies (2), but it is unusual as an isolated presenting feature of Down syndrome. The transient nature of the ascites in the presented case is very unusual. The main causes of fetal ascites are

chromosomal anomalies or infections, if no associated malformations are present.

In the presented case the etiology of ascites could not be detected by routine tests, including those for infectious, cardiac, and hormonal disorders. It is well known that chromosomal anomalies, such as Down syndrome, may be associated with isolated pleural effusion (3). The content of the isolated pleural effusion in Down syndrome is mostly chylous. There are a limited number of reported cases of Down syndrome with ascites (4).

Transient fetal ascites may be a new finding in a fetus with Down syndrome and we suggest cytogenetic analysis should be considered in the work-up of transient fetal ascites.

References

1. Zelop C, Benacerraf BR. The causes and natural history of fetal ascites. *Prenat Diagn* 1994; 14: 941-6.
2. Griscom NT, Colodny AH, Rosenberg HK, Fliegel CP, Hardy BE. Diagnostic aspects of neonatal ascites: report of 27 cases. *Am J Roentgenol* 1977; 128: 961-70.
3. Hwang JY, Yoo JH, Suh JS, Rhee CS. Isolated non-chylous pleural effusion in two neonates. *J Korean Med Sci* 2003; 18: 603-5.
4. Hogeman PH, van der Vorm DH, Puyenbroek JI, Exalto N: Chyloperitoneum in newborn infants. *Tijdschr Kindergeneeskd* 1983; 51: 143-6.