

## Lone Atrial Septal Aneurysm With Spontaneous Echo Contrast: An Increased Stroke Risk

Serpil DEMİRCİ<sup>1</sup>

M. Cem DÖNMEZ<sup>2</sup>

Süleyman M. ASLAN<sup>2</sup>

**Aims:** The etiology of stroke in young adults may be challenging. After preliminary investigations, a cause is not established in about one-third of patients. Cardiovascular embolism has been recognized as the cause of unexplained stroke or transient ischemic attack in a relevant number of young stroke patients.

**Materials and Methods:** A 39-year-old right-handed woman was admitted to hospital with a left-side weakness of sudden onset. Her personal and family history were unremarkable except for several episodes of left arm weakness lasting for less than 10 minutes. On cranial magnetic resonance imaging, a right frontotemporal infarction was observed.

**Results:** Laboratory work-up revealed normal clotting, thrombophilia and vasculitis screen. The transesophageal echocardiogram showed an atrial septal aneurysm with a large thrombus in the right atrium and spontaneous echo contrast inside the left atrium. The patient was started on anticoagulation. During the four-year follow-up she had no recurrence of stroke or transient ischemic attacks.

**Conclusions:** An atrial septal aneurysm is a rare but well-recognized cardiac abnormality that is recently recognized as an occult cardiac source of cerebral embolism. Its association with spontaneous echo contrast presents a higher embolic risk.

**Key Words:** Stroke, atrial septal aneurysm, embolism

<sup>1</sup> Department of Neurology,  
Faculty of Medicine,  
Süleyman Demirel University,  
Isparta - TURKEY

<sup>2</sup> Department of Cardiology,  
Faculty of Medicine,  
Süleyman Demirel University,  
Isparta - TURKEY

### Spontan Eko Kontrast ile Tek Atriyal Septal Anevrizma: Artmış İnme Riski

**Amaç:** Genç erişkinlerde inmenin nedenini belirlemek güç olabilir. İlk değerlendirmelerden sonra olguların yaklaşık üçte birinde bir neden saptanamayabilir. Yanısıra, genç inme olgularının önemli bir kısmında kardiyovasküler embolizm etiyojisi belirlenemeyen inme veya geçici iskemik atakların nedeni olarak saptanabilir.

**Yöntem:** 39 yaşında, sağ-el tercihli kadın hasta sol tarafında ani gelişen güçsüzlük şikayeti ile yatırıldı. Öz ve soy geçmişinde birkaç kez sol kolunda 10 dakikadan daha kısa süren güçsüzlük şikayeti dışında önemli bir özellik yoktu. Kraniyal manyetik rezonans görüntüleme sağ frontotemporal infarkt izlendi.

**Bulgular:** Laboratuvar incelemelerinde pıhtılaşma, trombofili ve vaskülitte yönelik incelemeler normaldi. Ekokardiyografik incelemede atrial septal anevrizma, sağ atriyumda büyük bir trombus ve sol atriyumda spontan eko-kontrast izlendi. Hastaya antikoagulan başlandı. Dört yıllık takibinde hastada inme veya geçici iskemik atakların tekrarı görülmedi.

**Sonuç:** Atriyal septal anevrizma nadir ancak iyi tanımlanmış ve serebral embolizm kaynağı olabilecek bir kalp anomalisidir. Spontan eko-kontrast ile birlikteliği embolizm riskini artırır.

**Anahtar Sözcükler:** inme, atriyal septal anevrizma, embolizm

Received: September 21, 2007  
Accepted: July 07, 2008

### Introduction

In the elderly, atherothrombotic ischemic infarction accounts for the majority of stroke cases. In the young, stroke constitutes a challenge because of the unconventional etiological factors and hence requires a detailed work-up. Cardioembolism is the first etiology that clinicians should rule out in a young adult with ischemic stroke. Patent foramen ovale, atrial septal defects and atrial septal aneurysms (ASAs) are recognized independent risk factors for cardioembolic strokes (1-4). We report the four-year follow-up of a case of stroke in a young patient secondary to ASA.

#### Correspondence

Serpil DEMİRCİ

Department of Neurology  
Faculty of Medicine  
Süleyman Demirel University  
32260 Isparta - TURKEY

serpildemirci@hotmail.com

## Case Report

A 39-year-old right-handed woman was admitted to hospital with a left-side weakness of sudden onset. When she had the attack, she was alone at home and was found on the ground by her husband four-to-five hours later. She had no previous personal or family history of diabetes mellitus, hypertension, hypercholesterolemia, vascular disease or recurrent abortion. Her personal history was remarkable only for episodic smoking. A detailed history revealed that she had experienced several episodes of left arm weakness lasting less than 5-10 minutes, to which she paid no attention.

Physical examination revealed left upper motor neuron facial palsy and left hemiplegia. Stretch reflexes on the left were diminished, and she had an upgoing toe on the left. Physical and neurological examination was otherwise normal.

Initial investigations including complete blood cell count, urea and electrolytes, fasting lipid profile, glucose, erythrocyte sedimentation rate, clotting and thrombophilia screen (prothrombin time, aPTT, fibrinogen, protein C, S, antithrombin III) and vasculitis screen (RF, ANA, anti DNA, ANCA, antiphospholipid antibodies) were all normal. Bilateral carotid and vertebral Doppler ultrasonography revealed no pathology. A 24-hour electrocardiogram showed normal sinus rhythm. Urgent cranial computed tomography on admission was normal but a cranial magnetic resonance

imaging revealed a right fronto-temporal low hypodensity area on the second day (Figure 1). Magnetic resonance angiography revealed no occlusion of cerebral arteries. The transesophageal echocardiogram (TEE) revealed an ASA with a large, immobile, hyperechogenic thrombus in the right atrium and spontaneous echo contrast inside the left atrium (Figure 2). There was no right-to-left shunt following a Valsalva maneuver.

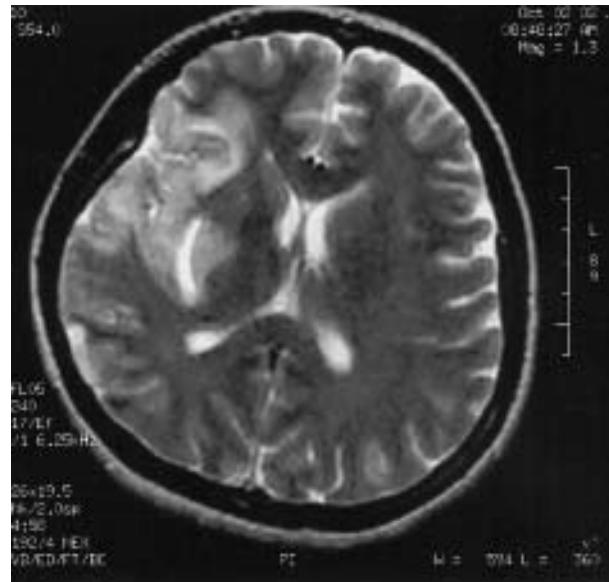


Figure 1. Cranial MRI, T2 axial image revealing right frontotemporal infarction.

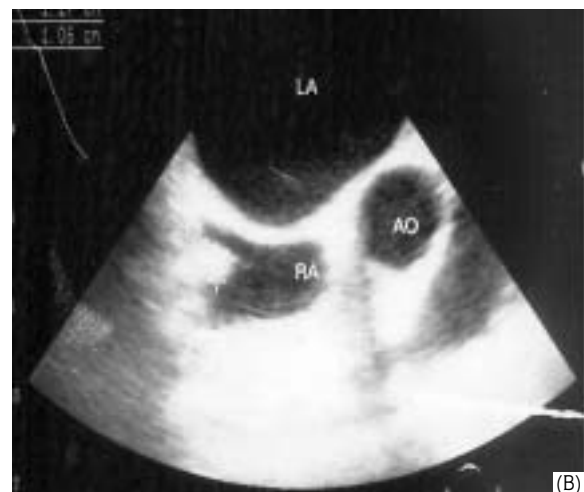
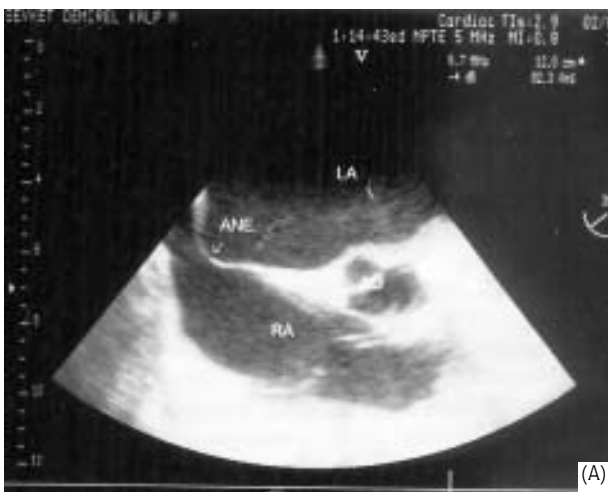

Figure 2. Transesophageal echocardiogram: (A) Interatrial septum showing an atrial septal aneurysm (ANE) bulging toward the right atrium (RA). (B) Inside the right atrium, there is a large, immobile, hyperechogenic thrombus attached to the atrial wall with a wide base (black arrow). LA: left atrium; AO: aorta.

The patient was commenced on warfarin anticoagulation, which is continuing. At present, after four years' follow-up, she is moderately disabled and has had no recurrence of stroke or transient ischemic attacks.

## Discussion

This patient presented with an infarction in the territory of the right middle cerebral artery in which a detailed work-up displayed ASA.

Atrial septal aneurysm is defined as a localized deformity of the interatrial septum that protrudes to the right or the left atrium, or both. Anatomically, it is a saccular formed dilatation of the tissue, generally located at the level of the fossa ovalis (5). Though reported as a rare congenital malformation, with the increasing use of transthoracic echocardiogram (TTE) and TEE, ASAs are increasingly being recognized as closely associated with strokes otherwise classified as cryptogenic. The incidence of ASA in the normal population is controversial; it has been reported to be found in about 1% of consecutive autopsies and in up to 4-9% of patients undergoing TEE for reasons other than a search for sources of emboli (2,3). The significantly higher prevalence of ASA in patients with a cerebral event than in controls emphasizes the role of ASA as a potential embolic source and as an independent risk factor for stroke and transient ischemic attacks (2,6-8).

Atrial septal aneurysm is rarely an isolated abnormality, but is, more often, associated with other cardiac abnormalities such as patent foramen ovale, mitral valve prolapsus, atrial septal defect, and others (9,10). This association is important because the risk of embolic events increases when compared with either factor being present in isolation. Lone ASA is defined as one without other cardiac abnormalities like atrial arrhythmias, hypertension or coronary heart disease (11). Lone ASA is the least recognized association in cryptogenic strokes (11).

Despite a well-recognized association of ASA, lone or with patent foramen ovale, with stroke, the causal link

has not yet been established. Paradoxical embolism, with passage of thrombi from the peripheral venous system to the left cardiac cavities through a septal defect, is considered the most likely mechanism leading to emboli occurrence. The potential risk of temporary supraventricular arrhythmias, just because of the atrial vulnerability, may be another potential explanation for the embolism. These were not found in our patient. Thrombi formation within or on the ASA is another mechanism proposed as responsible for systemic embolism. Actually, in our patient, TEE revealed a large, immobile thrombus attached to the wall of the right atrium. There was no right-to-left shunt in our patient. Spontaneous echo contrast is an independent predictor of high embolic risk in other disorders such as atrial fibrillation, mitral stenosis, etc. Its association with ASA would provide an anatomic and rheological substrate for in situ thrombus formation, as seen in our patient. Small and rapidly resolving thrombi can not totally be excluded as a cause of embolism in ASA (9).

The diagnosis of ASA by TEE in an ischemic stroke patient may alter the management. Harloff et al. (12) reported that TEE results strongly influenced their use of oral anticoagulation in one-third of their patients with stroke of undetermined etiology. Secondary prevention of strokes needs to be addressed because of a high recurrent event rate of 14% to 20% (13,14). Lifelong warfarin is administered to most patients with stroke or intraaneurysmal thrombi associated with ASA. An antiplatelet agent, aspirin, was suggested to be effective in patients with ASA without previous cerebral events (15). Although recurrence was reported to be low in lone ASA (16), accompanying findings, i.e. the presence of thrombi and spontaneous echo contrast justified the use of warfarin in our patient. In young and middle-aged patients, surgical repair of ASA can also be considered for the prevention of systemic thromboembolism (17). Future studies might delineate the treatment options in patients with stroke associated with ASA and patent foramen ovale, and isolated ASA.

## References

1. Warlow CP, Dennis MS, Van-Gijn J, Hankey GJ, Sandercock PAG, Bamford JM et al. Stroke: a practical guide to management. Oxford: Blackwell Science 1998. 190-257.
2. Meissner I, Khandheria BK, Heit JA, Petty GW, Sheps SG, Schwartz GL et al. Patent foramen ovale: innocent or guilty? Evidence from a prospective population-based study. *J Am Coll Cardiol* 2006; 47: 440-5.

3. Ghosh S, Ghosh AK, Ghosh SK. Patent foramen ovale and atrial septal aneurysm in cryptogenic stroke. *Portgrad Med J* 2007; 83: 173-7.
4. Palmieri V, Tufano A, Carmen Bonito M, Martino S, Sabatella M, Di Minno G et al. Right-to-left shunt, atrial septal aneurysm and thrombophilia in patients with cryptogenic stroke or TIA vs. those with thrombo-embolism. *Int J Cardiol* 2007 doi:10.1016/j.ijcard.2007.06.072.
5. Hanley PC, Tajik AJ, Hynes JK, Edwards WD, Reeder GS, Hagler DJ et al. Diagnosis and classification of atrial septal aneurysm by two-dimensional echocardiography: report of 80 consecutive cases. *J Am Coll Cardiol* 1985; 6: 1370-82.
6. Mattioli AV, Aquilina M, Oldani A, Mattioli G. Atrial septal aneurysm as a cardioembolic source in adult patients with stroke and normal carotids arteries. A multicentre study. *Eur Heart J* 2001; 22: 261-8.
7. Serafini O, Misuraca G, Greco F, Bisignani G, Manes MT, Venneri N. Prevalence of structural abnormalities of the atrial septum and their association with recent ischaemic attack: echocardiographic evaluation in 1861 patients. *Ital Heart J* 2003; 4(Suppl 1): 39-45.
8. Agmon Y, Khandheria BK, Meissner I, Gentile F, Whisnant JP, Sicks JD et al. Frequency of atrial septal aneurysm in patients with cerebral ischemic events. *Circulation* 1999; 99(15): 1942-4.
9. Mugge A, Daniel WG, Angermann C, Spes C, Khandheria BK, Kronzon I et al. Atrial septal aneurysm in adult patients: a multicenter study using transthoracic and transesophageal echocardiography. *Circulation* 1995; 91: 2785-92.
10. Rahko PS, Xu QB. Increased prevalence of atrial septal aneurysm in mitral valve prolapse. *Am J Cardiol* 1990; 66: 235-7.
11. Madan V, Harkness K, Brien EO, Warburton EA. Lone atrial septal aneurysm and stroke- a case report and review of the literature. *Eur J Intern Med* 2005; 16: 520-2.
12. Harloff A, Handke M, Reinhard M, Geibel A, Hetzel A. Therapeutic strategies after examination by transesophageal echocardiography in 503 patients with ischemic stroke. *Stroke* 2006; 37(3): 859-64.
13. Rahmatullah AF, Rahko PS, Stein JH. Transesophageal echocardiography for the evaluation and management of patients with cerebral ischemia. *Clin Cardiol* 1999; 22(6): 391-6.
14. Iliceto S, Papa A, Sorino M, Rizzon P. Combined atrial septal aneurysm and mitral valve prolapse: detection by two-dimensional echocardiography. *Am J Cardiol* 1984; 54(8): 1151-3.
15. Burger AJ, Sherman HB, Charlamb MJ. Low incidence of embolic strokes with atrial septal aneurysms: a prospective, long-term study. *Am Heart J* 2000; 139(1 Pt 1): 149-52.
16. Mas JL, Arquizan C, Lamy C, Zuber M, Cabanes L, Derumeaux G et al. Patent Foramen Ovale and Atrial Septal Aneurysm Study Group. Recurrent cerebrovascular events associated with patent foramen ovale, atrial septal aneurysm, or both. *N Engl J Med* 2001; 345(24): 1740-6.
17. Lanzberg MJ, Khairy P. Indications for the closure of patent foramen ovale. *Heart* 2004; 90(2): 219-24.