

## Cause of Fever in a Case with End-Stage Renal Disease: Splenic Marginal Zone Lymphoma

Ramazan ÇETİNKAYA<sup>1</sup>  
İlhami KİKİ<sup>2</sup>  
Abdullah UYANIK<sup>1</sup>  
Mustafa KELEŞ<sup>1</sup>  
Bülent AYDINLI<sup>3</sup>  
Fazlı ERDOĞAN<sup>4</sup>  
Nesrin GÜRSAN<sup>4</sup>  
Mecit KANTARCI<sup>5</sup>

**Abstract:** Splenic marginal zone lymphomas (SMZL) are rare tumors arising from B-cells, accounting for approximately 1% of all lymphomas. An accompanying lymphoma is uncommon in patients who have chronic renal failure and undergo hemodialysis. We present herein a 35-year-old male hemodialysis patient admitted with fever, abdominal pain, and splenomegaly, diagnosed with SMZL. In our investigations in the English literature, we did not observe any SMZL case among hemodialysis patients. Fever may emerge due to different causes in chronic hemodialysis patients, primarily infections. In hemodialysis patients presenting with fever, lymphoma and other malignant diseases should be considered.

**Key Words:** Splenic marginal zone lymphoma, hemodialysis patient, fever

### Son Dönem Böbrek Yetmezlikli Bir Olguda Ateş Nedeni Olarak Splenik Marjinal Zon Lenfoma

**Özet:** Splenik marjinal zon lenfomalar, B hücrelerinden kaynaklanan, tüm lenfomaların yaklaşık % 1'ini oluşturan, nadir tümörlerdir. Kronik hemodiyaliz hastalarında lenfoma görülmesi seyrekdir. Ateş, karın ağrısı ve dalak büyüklüğü ile başvuran ve splenik marjinal zon lenfoma tanısı konulan 35 yaşında bir erkek hemodiyaliz hastasını sunmayı amaçladık. Biz İngilizce literatürde daha önce hemodiyaliz hastalarında gösterilmiş bir splenik marjinal zon lenfoma olgusuna rastlamadık. Hemodiyaliz hastalarında başta enfeksiyonlar olmak üzere değişik nedenlerle ateş ortaya çıkabilir. Hemodiyaliz hastalarında ateş nedeni olarak lenfomalar ve diğer malign hastalıklar da dikkate alınmalıdır.

**Anahtar Sözcükler:** Splenik marjinal zon lenfoma, hemodiyaliz hastası, ateş

### Introduction

Splenic marginal zone lymphomas (SMZL) are rare tumors arising from B-cells, accounting for approximately 1% of all lymphomas. This is a type of lymphoma commonly observed in elderly individuals, and is often asymptomatic, presenting with abdominal pain, splenomegaly, cytopenia, and generally a slow clinical course (1-5).

SMZL was first described by Schmid et al. (6) as a low-grade B-cell lymphoma of the spleen, characterized by a nodular infiltrate based on pre-existing white pulp follicles, which are partly or completely overrun by the neoplastic cells.

Previous studies have suggested that the frequency of cancer is higher in patients with end-stage renal disease (ESRD) than in the general population, but have not established whether this increase is confined to certain cancers or to certain categories of ESRD patients. On the other hand, an accompanying lymphoma is uncommon in patients who have chronic renal failure and undergo hemodialysis (7-9). In our investigations in the English literature, we did not observe any SMZL case among hemodialysis patients. Therefore, we present a 35-year-old male hemodialysis patient who admitted with fever, abdominal pain, and splenomegaly, and was diagnosed with SMZL.

<sup>1</sup> Department of Nephrology,  
Faculty of Medicine,  
Atatürk University,  
Erzurum - TURKEY

<sup>2</sup> Department of Hematology,  
Faculty of Medicine,  
Atatürk University,  
Erzurum - TURKEY

<sup>3</sup> Department of General Surgery,  
Faculty of Medicine,  
Atatürk University,  
Erzurum - TURKEY

<sup>4</sup> Department of Pathology,  
Faculty of Medicine,  
Atatürk University,  
Erzurum - TURKEY

<sup>5</sup> Department of Radiology,  
Faculty of Medicine,  
Atatürk University,  
Erzurum - TURKEY

Received: August 14, 2007  
Accepted: August 25, 2008

#### Correspondence

Ramazan ÇETİNKAYA  
Atatürk University,  
Post Office,  
PK: 7  
25171 Erzurum - TURKEY  
ramazancetinkaya@yahoo.com

**Case Report**

A 35-year-old male patient, who was on a hemodialysis program for two months due to ESRD secondary to chronic interstitial nephritis, was hospitalized with high fever lasting for two days. The cause of fever was thought to be catheter-related, as he had a hemodialysis catheter in his jugular vein, and hence, blood samples were obtained and cephazolin sodium 1 g 2x1 was administered. The catheter was removed. The blood cultures obtained before treatment yielded *Staphylococcus aureus*. The antibiotic administered was sensitive, but he was administered

vancomycin 1 g since there was no reduction in the fever. Appropriate antibiotherapy was administered for *Escherichia coli* that grew in the urine culture, the specimen of which had been obtained on admission. Control blood and urine cultures were negative. Fever was not under control with this treatment. On physical examination, there were multiple lymphadenopathies in the axillary and inguinal regions, in addition to hepatosplenomegaly. In the laboratory analyses, the complete blood count revealed a hemoglobin level of 6.3 g/dl, a hematocrit of 20%, a white blood cell count of

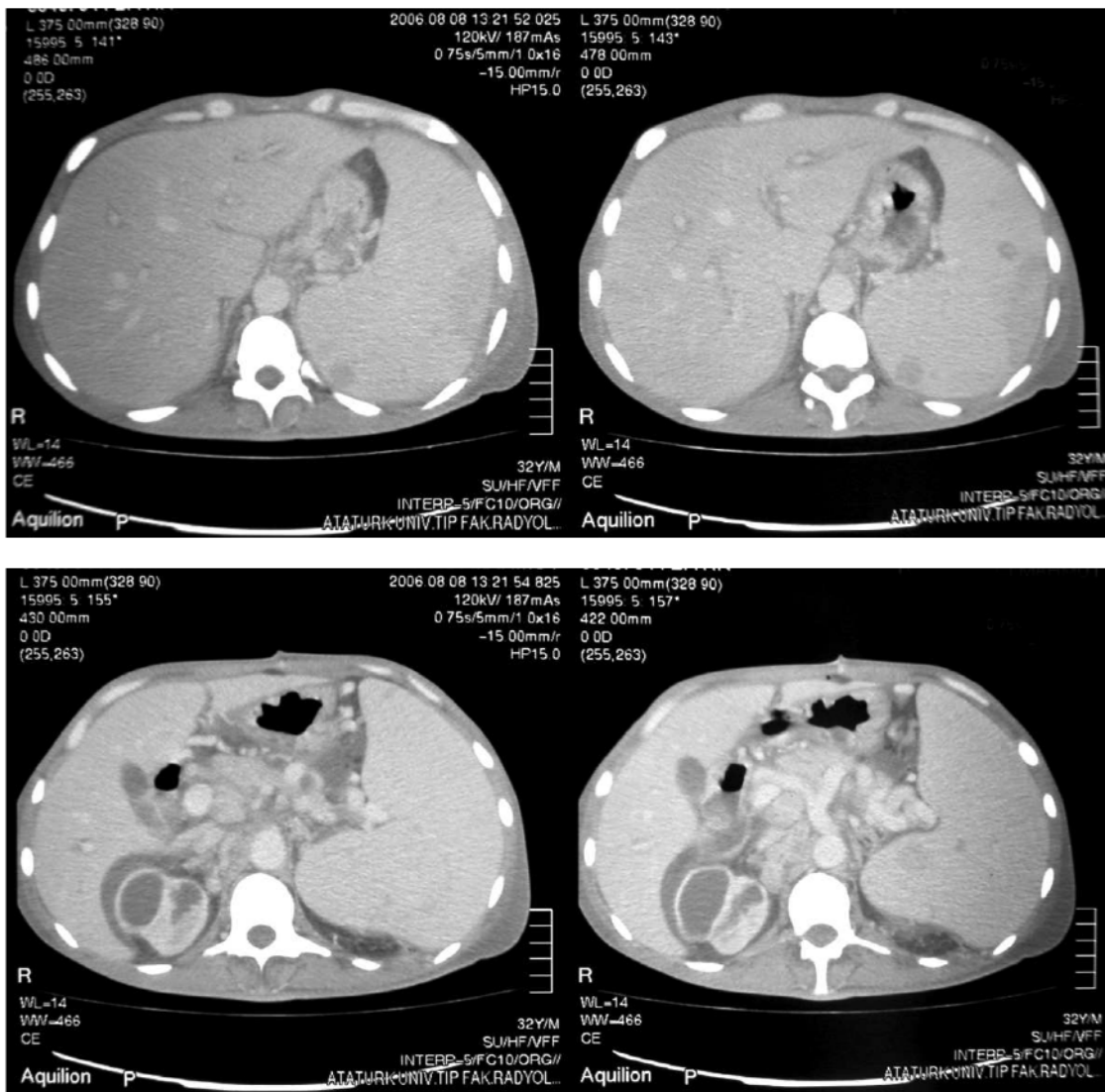

Figure 1. Computed tomography of the abdomen shows multiple paraaortic conglomerated lymphadenopathies, large liver of 200 mm, extremely large spleen 290 mm in size, necrotic infarct areas in upper and lower poles of the spleen, hypodense lesions in the spleen, and 20 mm-sized lymphadenopathy anterior to liver.

7900  $\mu\text{L}$ , and a platelet count of 176000  $10^3/\mu\text{L}$ . The white blood cell differential showed 76% neutrophils, 17% lymphocytes, 5% monocytes, 1% eosinophils, and 1% basophils. Blood urea nitrogen was 40 mg/dl (N: 5-20), creatinine: 5.5 mg/dl (N: 0.5-1.6), potassium: 4.8 mEq/L (N: 3.5-5.5), sodium: 143 mEq/L (N: 135-150), calcium: 8.3 mg/dl (N: 8.5-10.5), AST: 23 U/L (N: 7-39), ALT: 9 U/L (N: 2-40), glucose: 71 mg/dl (N: 70-110), LDH: 756 (N: 110-250), CRP: 0.5 (N: 0-0.5), and parathormone: 108 pg/ml (N: 0-78). Salmonella, brucella, thyroid function tests, vitamin B 12, folic acid, ferrum parameters, hepatitis markers, and coagulation tests revealed normal results. In ultrasonography, hepatosplenomegaly and multiple lymphadenopathies of varying sizes were observed adjacent to the aorta. In the computerized tomography of the abdomen, hepatomegaly, massive splenomegaly, and periportal and paraaortic adenopathies of different sizes were absorbed. Left axillary biopsies were performed twice. It was reported as reactive lymphadenopathy. Bone marrow biopsy was reported as normal. Another abdominal tomography was performed due to persistence of severe abdominal pain. In addition to the findings in the initial tomography, regions of infarct were detected in the spleen (Figure 1). Splenectomy was performed with diagnostic and therapeutic intentions. Pathologic evaluation of the spleen was positive for splenic marginal zone B-cell lymphoma (Figure 2). His fever regressed following splenectomy and significant improvement was observed in the clinical course. The patient was then referred to a hematologist for consultation, and we await his follow-up.

## Discussion

Fever may emerge due to different causes in chronic hemodialysis patients, primarily infections. In hemodialysis patients presenting with fever, lymphoma and other malignant diseases should be considered (10).

In our investigations in the English literature, we did not observe any SMZL case among hemodialysis patients. In this hemodialysis patient presenting with high fever, which continued despite resolution of the infection, we considered that he had lymphoma based on other clinical and laboratory findings; however, peripheral adenopathy and bone marrow biopsies did not provide diagnostic results. Pathological evaluation of splenectomy was decided due to massive splenomegaly in both physical examination and computerized tomography, which revealed SMZL.

SMZL accompanying extranodal marginal zone B-cell lymphoma of mucosa-associated lymphoid tissue (MALT-lymphoma) and nodal marginal zone lymphoma comprise the marginal-zone lymphoma group. SMZL is a newly defined, separate clinicopathological entity. SMZL is a disease involving the spleen, bone marrow and peripheral blood as the initial manifestations of the disease. Definitive diagnosis was possible only by laparotomy and splenectomy. Because of the slow course of these types of lymphomas, surgical treatment with splenectomy appears to play an important role in the treatment of some patients, with a resultant clinical response in most cases (1,2,5,10).

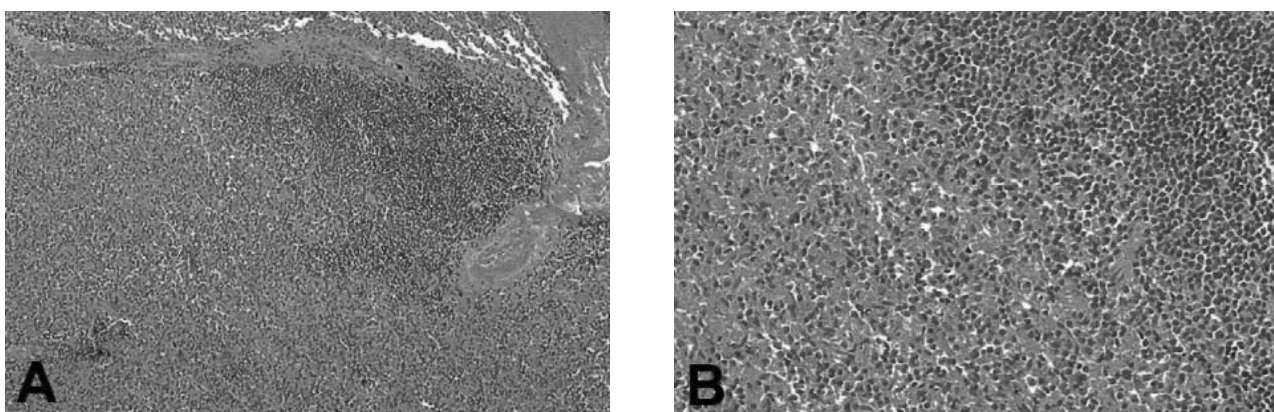


Figure 2. Splenic marginal zone B-cell lymphoma (hematoxylin-eosin). (A,B) Histologically, the germinal center is surrounded by small lymphoid cells that merge peripherally into slightly larger cells with pale-staining cytoplasm. Both the small lymphoid cells and larger cells are neoplastic.

**References**

1. Thieblemont C. Clinical presentation and management of marginal zone lymphomas. *Hematology Am Soc Hematol Educ Program* 2005; 307-313.
2. Dogan A, Isaacson PG. Splenic marginal zone lymphoma. *Semin Diagn Pathol* 2003; 20: 121-7.
3. Thieblemont C, Felman P, Callet-Bauchu E, Traverse-Glehen A, Salles G, Berger F et al. Splenic marginal-zone lymphoma: a distinct clinical and pathological entity. *Lancet Oncol* 2003; 4: 95-103.
4. El Mezni F, Zeddini A, Ismail O, Braham E. Splenic marginal zone lymphoma. One case report. *Tunis Med* 2005; 83: 366-8.
5. Tsimberidou AM, Catovsky D, Schlette E, O'Brien S, Wierda WG, Kantarjian H et al. Outcomes in patients with splenic marginal zone lymphoma and marginal zone lymphoma treated with rituximab with or without chemotherapy or chemotherapy alone. *Cancer* 2006; 107: 125-35.
6. Schmid C, Kirkham N, Diss T, Isaacson PG. Splenic marginal zone cell lymphoma. *Am J Surg Pathol* 1992; 16: 455-66.
7. Pamuk GE, Demir M, Örum H, Turgut B, Özyılmaz F, Tekgündüz E. Secondary amyloidosis causing nephrotic syndrome in a patient with non-Hodgkin's lymphoma: quite a rare diagnosis. *Clin Lab Haematol* 2006; 28: 259-61.
8. Maisonneuve P, Agodoa L, Gellert R, Stewart JH, Buccianti G, Lowenfels AB et al. Cancer in patients on dialysis for end-stage renal disease: an international collaborative study. *Lancet* 1999; 354: 93-9.
9. Cengiz K. Increased incidence of neoplasia in chronic renal failure (20-year experience). *Int Urol Nephrol* 2002; 33: 121-6.
10. Depowski PL, Dunn H, Purdy S, Ross JS, Nazeer T. Splenic marginal zone lymphoma: a case report and review of the literature. *Arch Pathol Lab Med* 2002; 126: 214-6.
11. Thieblemont C, Felman P, Berger F, Dumontet C, Arnaud P, Hequet O et al. Treatment of splenic marginal zone B-cell lymphoma: an analysis of 81 patients. *Clin Lymphoma* 2002; 3: 41-7.