

## Oropharyngeal Anthrax\*

Abdullah TAŞ<sup>1</sup>  
Recep YAĞIZ<sup>1</sup>  
Şaban GÜRÇAN<sup>2</sup>  
Deniz KARAOĞLU<sup>1</sup>

**Aims:** To report a rare case of oropharyngeal anthrax.

**Materials and Methods:** A case report of oropharyngeal anthrax is presented together with the related world literature.

**Results:** A 70-year-old female patient with respiratory distress and extensive swelling of neck, soft palate and uvula is presented. There was ecchymosis on the neck circumferentially. *Bacillus anthracis* grew in the blood culture. The patient died of toxemia and sepsis.

**Conclusions:** Oropharyngeal anthrax is the least common form of anthrax. This acute illness should be added to the differential diagnosis of inflammatory lesion of the oropharynx with extensive neck swelling. Successful diagnosis of anthrax depends on a high level of suspicion.

**Key Words:** Anthrax, oropharyngeal, toxic shock

### Orofarengel Şarbon

**Amaç:** Orofarengel şarbonlu nadir bir vaka sunmak.

**Yöntem ve Gereç:** Orofarengel şarbonlu bir olgu literatür ile birlikte değerlendirilmiştir.

**Bulgular:** Solunum sıkıntısı ve boyunda, yumuşak damak ve uvulada ileri derecede şişlik ile başvuran 70 yaşında kadın hasta sunulmuştur. Boyunda yaygın ekimoz vardı. Kan kültüründe *Bacillus anthracis* üredi. Hasta toksemi ve sepsis nedeniyle kaybedildi.

**Sonuç:** Orofarengel şarbon en az sıklıkla bulunan şarbon formudur. Bu akut hastalık yaygın boyun şişliği ile seyreden orofarengel inflamatuvar lezyonlarının ayırıcı tanısında akılda bulundurulmalıdır. Şarbonun başarılı tanısı, bundan şüphelenmeye bağlıdır.

**Anahtar Sözcükler:** Şarbon, orofarenks, toksik şok

### Introduction

Anthrax is often a fatal bacterial infection occurring when *Bacillus anthracis* (*B. anthracis*) endospores enter the body through abrasions in the skin or by inhalation or ingestion. Human infections result from contact with contaminated animals or animal products; there are no known cases of human-to-human transmission (1,2). *B. anthracis* is primarily found in tropical environments in Africa, Asia, South and Central America and the Caribbean (3). There are four clinical types of human anthrax: cutaneous, inhalational, gastrointestinal, and oropharyngeal. Cutaneous anthrax accounts for more than 90% of the cases worldwide, while oropharyngeal anthrax is the least common form (3). Oropharyngeal anthrax develops after ingestion of infected meat and subsequent invasion of mucosal and submucosal lymphatics (4). Initial symptoms include cervical edema and local lymphadenopathy, which cause dysphagia and respiratory difficulties (5). Patients with oropharyngeal anthrax may also complain of fever, hoarseness, cough, globus sensation, and neck pain. Intraoral examination typically reveals inflammatory lesions (red–purple ulcerations) or asymmetric swelling of oral cavity or oropharynx. If localized to the tonsillar region, it may mimic a peritonsillar abscess; however, there is no pus (6).

\* This paper was presented in part at the 29th Turkish National Otorhinolaryngology and Head and Neck Surgery Congress, Antalya, Turkey, 26-31 May 2007.

<sup>1</sup> Department of Otorhinolaryngology,  
Faculty of Medicine,  
Trakya University,  
Edirne - TURKEY  
<sup>2</sup> Department of Microbiology and  
Clinical Microbiology,  
Faculty of Medicine,  
Trakya University,  
Edirne - TURKEY

Received: November 14, 2007  
Accepted: August 28, 2008

#### Correspondence

Abdullah TAŞ  
Department of  
Otorhinolaryngology  
Faculty of Medicine,  
Trakya University  
22030 Edirne - TURKEY

abdultas@yahoo.com

In this article, we report a case with oropharyngeal anthrax, with the complaints of respiratory distress and extensive swelling of the neck.

### Case Report

A 70-year-old previously healthy female was admitted to a state hospital with respiratory distress complaint. Oropharyngeal edema was detected and intravenous and inhaler corticosteroid were applied, as angioneurotic edema was suspected. This medication and observation failed to reduce her complaints. She was consigned to our medical faculty hospital. The symptoms began after basement sweeping. The respiratory distress and swelling of the neck became rapidly more severe after two days. She was admitted about two days after the onset of symptoms. At the time of admission, the patient was in severe respiratory distress. Her blood pressure was 140/90 mmHg, pulse rate 88/minute and axillary temperature 35.7 °C. There was swelling and ecchymosis on the neck circumferentially. Throat examination revealed marked swelling of the soft palate and uvula. There was no necrosis or ulceration in this area. Laboratory data included a hematocrit of 47.8% and a white blood cell count of 14,800 mm<sup>3</sup> with 93.3% neutrophils and 6.3% lymphocytes. Chest X-rays were normal. The blood gas analysis showed mild respiratory acidosis. Blood culture was taken three times at 30-minute intervals. Ceftriaxone every 12 hours was started intravenously together with acidosis treatment. The

patient lost consciousness 18 hours after admission. Blood pressure decreased to 60/40 mmHg. The patient was intubated with endotracheal intubation tube and ventilation was adjusted. Body temperature increased up to 37.3°C. The patient died 64 hours after admission. A postmortem hepatic needle biopsy was performed, and *B. anthracis* was isolated both in the blood culture and hepatic biopsy material (Figure). There was no contact with infected animals or contaminated animal products. The source of infection could not be established. Other family members were healthy.

### Discussion

Anthrax infections are initiated by endospores of *B. anthracis*, a gram-positive soil organism. Anthrax endospores do not grow, have no measurable metabolism, and are resistant to drying, heat, ultraviolet light, gamma radiation, and many disinfectants. In some types of soil, anthrax spores can remain dormant for decades (5). Anthrax toxin contains three proteins: protective antigen (PA), edema factor (EF), and lethal factor (LF). These toxins decrease polymorphonuclear function and cause toxic clinical manifestations (7). Oropharyngeal anthrax is usually associated with ingestion of contaminated meat (4,6-9). There was no ingestion of contaminated meat in our patient's history. Sirisanthana et al. (6) reported that the oropharyngeal form of anthrax is a potentially fatal, febrile illness characterized by a short incubation period and an oral/oropharyngeal lesion that can progress from edema and congestion to a pseudomembranous necrosis, associated with pharyngeal and cervical lymphadenopathy and surrounding edema. Systemic anthrax involves massive bacteremia and toxemia with nondescript initial symptoms until the onset of hypotension, shock, and sudden death. Manifestations of advanced disease, including shock and sudden death are believed to result from the action of the exotoxin complex secreted by anthrax bacilli (2). Most of the patients who died of anthrax sepsis, despite treatment, had incubation periods of less than 48 h and typically died within 48 h of the onset of symptoms (7). Doganay et al. (8) reported six cases with oropharyngeal anthrax. The lesions were localized on tonsils in five cases and on the base of the tongue in one case. The source of infection was not established in two cases. In our case, the lesion was localized on the soft plate and uvula. The source of

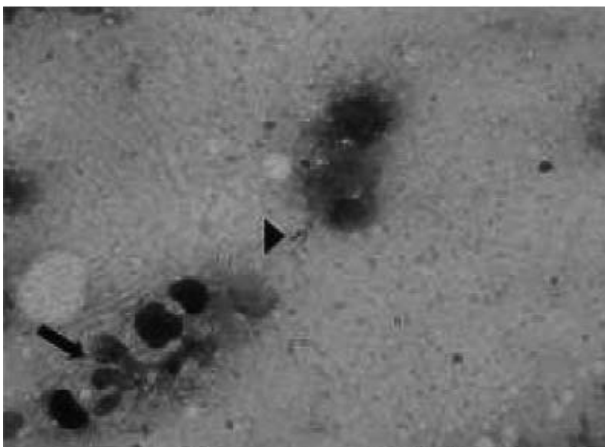


Figure. *Bacillus anthracis* in liver. Polymorphonuclear leukocyte (arrow) and *B. anthracis* (arrow head) (Gram stain X1000).

infection could not be established. Penicillin is the drug of choice in the treatment of anthrax. Despite penicillin treatment, the mortality rate of pulmonary and gastrointestinal system anthrax or septicemia and meningitis is >80% (8). Death may occur secondary to a toxin from *B. anthracis* (4,8). In our patient, despite antimicrobial treatment (ceftriaxone) and supportive care, the patient died 64 hours after admission. In our opinion, death results from toxemia. The diagnosis is rarely made before death except in endemic areas (7). In this case, there was no suspicion of anthrax. Our region is not an endemic area for anthrax. Differential diagnosis of oropharyngeal anthrax should include peritonsillar abscess, parapharyngeal space abscess, streptococcal

pharyngitis, Ludwig's angina, and diphtheria (3). Blood cultures of systemic anthrax infection cases are almost always positive because of the large numbers of bacterial cells in the circulation (1). All oropharyngeal cases must be carefully observed, because rapid edema may develop and necessitate endotracheal intubation or even tracheotomy. Corticosteroids may be indicated in addition to appropriate antibiotic therapy (2,3).

In conclusion, oropharyngeal anthrax is the least common form of anthrax. This acute illness should be added to the differential diagnosis of inflammatory lesion of the oropharynx with extensive neck swelling. Successful diagnosis of anthrax depends on a high level of suspicion.

## References

1. Hanna P. Anthrax pathogenesis and host response. *Curr Top Microbiol Immunol* 1998; 225: 13-35.
2. Dixon TC, Meselson M, Guillemin J, Hanna PC. Anthrax. *N Engl J Med* 1999; 341: 815-26.
3. Wirtschaffner A, Cherukuri S, Benninger MS. Anthrax: ENT manifestations and current concepts. *Otolaryngol Head Neck Surg* 2002; 126: 8-13.
4. Navachareon N, Sirisanthana T, Navachareon W, Ruckphaopunt K. Oropharyngeal anthrax. *J Laryngol Otol* 1985; 99: 1293-5.
5. Watson A, Keir D. Information on which to base assessments of risk from environments contaminated with anthrax spores. *Epidemiol Infect* 1994; 113: 479-90.
6. Sirisanthana T, Navachareon N, Tharavichitkul P, Sirisanthana V, Brown AE. Outbreak of oral- oropharyngeal anthrax: an unusual manifestation of human infection with *Bacillus anthracis*. *Am J Trop Med Hyg* 1984; 33: 144-50.
7. Babamahmoodi F, Aghabarari F, Arjmand A, Ashrafi GH. Three rare cases of anthrax arising from the same source. *J Infect* 2006; 53: 175-9.
8. Doğanay M, Almaç A, Hanagasi R. Primary throat anthrax. A report of six cases. *Scand J Infect Dis* 1986; 18: 415-9.
9. Onerci M, Ergin NT. Oropharyngeal anthrax. *Laryngorhinootologie* 1993; 72: 350-1.