

## Is the Traditional Treatment Approach Adequate in Children with Adenoid Hypertrophy?

Baran ACAR

Hayriye KARABULUT

Mehmet Ali BABADEMEZ

Selahattin GENÇ

R. Murat KARAŞEN

Department of Otorhinolaryngology,  
Keçioren Training and  
Research Hospital,  
Ankara - TURKEY

**Aim:** We aimed to show the necessity of 1) endoscopic assessment after adenoidectomy performed blindly by adenoid curette, adenotome or adenoid punch forceps after checking adenoid size with finger palpation, which is commonly used in routine practice and 2) extraction of residual adenoids with additional methods.

**Materials and Methods:** Prospective intraoperative flexible endoscopic evaluation of the nasopharynx in a case series of 51 patients was performed. The degree of residual postnasal obstruction due to adenoid tissue was assessed endoscopically with 2.7-mm 0° telescope (small, moderate, large) after routine transoral adenoidectomy. The telescope was then introduced transnasally, and residual adenoid tissue was both assessed and removed with powered-shaver adenoidectomy.

**Results:** In the first assessment (E1) of 51 patients, 15 (29.4%) cases with moderate- and 36 (70.6%) with large-size adenoids were found, while in the second assessment (E2) after traditional blind curettage adenoidectomy, 26 of the patients had moderate and 25 had small residual adenoid tissue. Adenoid size was reduced 1 level in 41 patients (80.4%) and 2 levels in 10 patients (19.6%). Residual adenoid tissue rate was higher in large adenoids when the adenoid sizes determined in the first assessment were compared ( $P = 0.024$ ).

**Conclusions:** Residual tissue rate is fairly high after blind curettage adenoidectomy, particularly in large adenoids. Therefore, residual tissues should be cleaned with additional methods.

**Key Words:** Adenoid hypertrophy, blind curettage, residual adenoid tissue, powered-shaver adenoidectomy

### Adenoid Hipertrofi Çocuklar da Geleneksel Tedavi Yaklaşımı Yeterli mi?

**Amaç:** Bu çalışmanın amacı rutinde sıklıkla yapılan adenoid büyüklüğünü parmakla kontrol edip kör küretaj, adenotom veya adenoid punch forseps ile yapılan adenoidektomi sonrası endoskopi ile değerlendirilmesi ve rezidüel adenoidlerin ek yöntemler ile çıkarılmasının gerekliliğini göstermektir.

**Materyal ve metod:** 51 hastanın prospektif intraoperatif fleksibl nazofaringoskop ile değerlendirilmesi. Rutin transoral adenoidektomi sonrası postnazal obstrüksiyona neden olan rezidüel adenoid doku 2.7-mm 0° teleskop ile küçük (S), orta (M) ve büyük (L) olarak değerlendirildi. Daha sonra transnazal endoskop kullanılarak rezidüel adenoid doku değerlendirildi. Rezidüel adenoid dokular shaver ile çıkartıldı.

**Bulgular:** 51 hastanın ilk değerlendirmesinin (E1) de 15 (% 29.4) M, 36 (% 70.6) L adenoid varken, geleneksel kör küretaj adenoidektomiyi takiben yapılan ikinci değerlendirmesinin (E2) de 26'sında (% 51) M, 25'inde (% 49) S adenoid dokusu varlığı tespit edildi. Adenoid büyüklüğü 41 hastada (% 80.4) 1 derece, 10 hastada (% 19.6) 2 derece küçültülmüştü. İlk değerlendirmede M ve L olarak tespit edilen adenoidler karşılaştırıldığında L adenoidlerde residual adenoid doku kalma oranı daha fazla idi  $P = 0.024$ .

**Sonuç:** Özellikle L adenoidlerde kör küretaj adenoidektomi sonrası rezidüel adenoid doku kalma olasılığı oldukça yüksektir. Bu yüzden kalan rezidüel dokular ek yöntemler ile temizlenmelidir.

**Anahtar Sözcükler:** Adenoid hipertrofi, kör küretaj, rezidüel adenoid doku, shaver adenoidektomi

Received: March 25, 2008  
Accepted: October 30, 2008

### Introduction

The adenoid, or nasopharyngeal tonsil, is a lymphoepithelial organ located in a critical anatomical position in the roof of the nasopharynx, and it plays an important role in disease of the upper respiratory tract (1). Present from early gestation, adenoid growth continues until about six years of age, after which atrophy occurs. Adenoidal hypertrophy during childhood may both fill the nasopharynx and extend through the posterior choanae into the nose, resulting in mouth breathing and rhinorrhea, sleep-disordered breathing, speech anomalies, feeding difficulties, chronic sinusitis, otitis media with effusion (OME) and craniofacial growth anomalies (2).

#### Correspondence

Baran ACAR

Keçioren Training and Research  
Hospital, Department of  
Otorhinolaryngology  
Pınarbaşı Mahallesi Sanatoryum  
Caddesi Ardahan Sok.

No: 1, Keçioren  
06310 Ankara - TURKEY

drbaranacar@gmail.com

An accurate assessment of the adenoid size and its relationship to the postnasal space is difficult to achieve clinically, yet it is important in the selection of children for adenoidectomy (3). Adenoidectomy is one of the most commonly performed procedures in pediatric otolaryngological practice (4). However, the indications for adenoidectomy are still a matter of discussion. Wilhelm Meyer, the famous Danish otolaryngologist, first described adenoidectomy in 1885 and recommended curettage through the nose assisted by a finger in the postnasal space (5). Since then, many alternative techniques have been described, including suction electrocautery ablation performed transnasally (4) or transorally (6,7), power-assisted adenoidectomy (8-10) and laser adenoidectomy (11). The traditional technique, by means of adenotomes (12), remains quite popular, and although simple and time-honored, it has certain pitfalls, such as incomplete removal and trauma to underlying tissues (13). Utilization of 0° endoscopes to assist further removal of incompletely removed adenoid tissue with Weil or Blakesley forceps through a combined transoral and transnasal approach after curettage has been reported to result in more complete and functional adenoidectomy (14-16). However, the use of forceps has the disadvantages of bleeding after forceps use, and the need to transition between transoral and transnasal setups; both potentially may increase operating time. The power-assisted adenoidectomy is more effective in clearing adenoid tissue compared with curettage (17), but this has yet to be objectively assessed.

In this study, we assessed the residual adenoids transorally with an adenoid curette during the surgery and extracted the residual tissues with power-assisted adenoidectomy.

## Materials and Methods

### Assessment of Adenoid Size

Adenoid size in all patients was evaluated by the primary surgeon according to Wang's classification (18). According to the distance from the vomer to the adenoid tissue, the relative size of the adenoid tissue was estimated and classified into three categories: (1) Small adenoid (S), distance >1.0 cm; (2) Moderate adenoid (M), distance between 0.5 and 1.0 cm; (3) Large adenoid (L) (adenoid hypertrophy), distance <0.5 cm. The palate and

uvula were inspected and palpated to exclude a soft palate cleft. Adenoid sizes of children enrolled in the study were L and M. Cases with S adenoids most likely did not apply to our clinic since they do not commonly cause obstructive symptoms.

Adenoidectomies of the patients were done by a second surgeon with blind curettage method, either alone or in combination with tonsillectomy or ear tube insertion. After being anesthetized, the patient was positioned supine with the neck extended, and a Boyle–Davis mouth gag was inserted. The bulk of the adenoid tissue was felt digitally by the surgeon and then removed blindly with several passes of the curette. Hemostasis was achieved using plain packs or adrenaline packs. After the second surgeon finished adenoidectomy, residual adenoid size was again assessed transnasally with 2.7-mm 0° telescope according to the classification described by Wang. If the patient had residual adenoid tissue, adenoidectomy was completed transorally with powered-shaver adenoidectomy technique guided by transnasal videoendoscopy, and a nasopharyngeal sponge was placed for a few minutes for hemostasis.

### Statistical Analyses

Statistical analyses were performed using SPSS 13.0 for Windows. P value of <0.05 was considered significant. For overall comparisons of the groups (patients with E1 L and E1 M), chi-square test was used.

## Results

A prospective study was conducted that included 51 children undergoing adenoidectomy. Twenty-five (49%) of the patients were girls and 26 (51%) were boys. In 85% of the cases, the procedure was accompanied by insertion of ventilation tubes. Mean age of the patients was 8.07 (4-12) years.

Adenoid sizes of the patients were 15 (29.4%) M and 36 (70.6%) L in the first assessment (E1), and were 25 (49%) S, 26 (51%) M in the second assessment (E2), respectively (Figure 1). Adenoid size was reduced 1 level in 41 patients (80.4%) and 2 levels in 10 patients (19.6%) (Figure 2). Residual adenoid rate was significantly higher in the cases with L adenoids when sizes of the adenoids were compared in E1 (P=0.024).

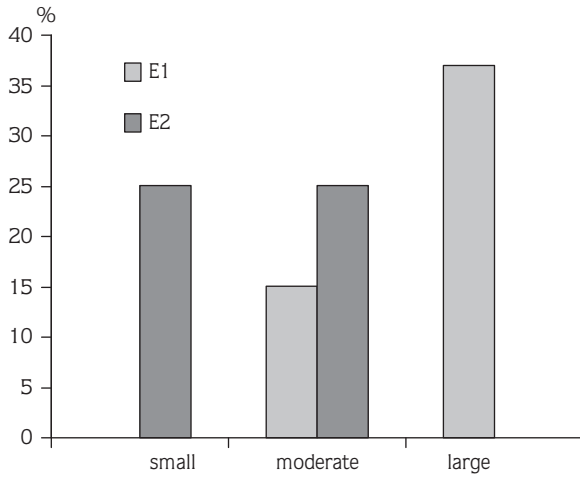


Figure 1. Adenoid sizes of patients in E1 and E2 assessments.

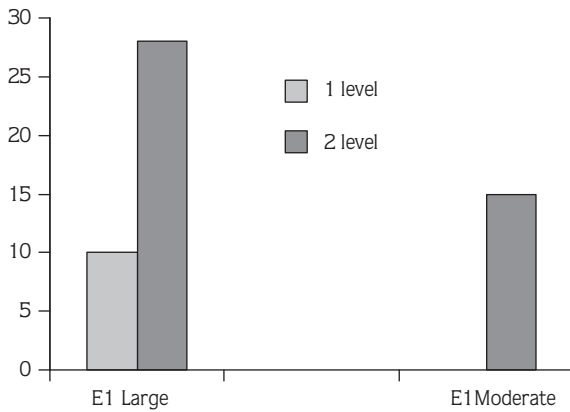


Figure 2. Reduction levels of L and M adenoids in E2 compared to E1.

**Discussion**

Adenoid hypertrophies cause problems not only because of their size but also because they serve as a reservoir for upper respiratory tract pathogens (19).

Adenoidectomy has been performed for more than 100 years (20). The aim of adenoidectomy is to extract the hypertrophic adenoid tissue that causes obstructive or infective symptoms (21). It has been performed for many years with the aid of transoral curettes, an adenoid punch, and an adenotome. Besides the traditional blind curettage adenoidectomy, the procedure can be performed with many alternative methods like suction electrocautery adenoid ablation, power-assisted adenoidectomy and laser adenoidectomy. The most commonly used method in Turkey is blind curettage

performed with finger palpation. The efficacy of these methods can be improved using endoscope or mirror. A technique suggested by Monroy et al. (22) allows indirect visualization of the nasopharynx using mirrors for as complete a removal as possible, while sparing the tori tubarius.

Visualization and coordination of the mirror method is limited to large adenoids causing choanal occlusion when compared to endoscope. It also has disadvantages like damaging the choanae and torus tubarius and leaving residual tissue (17). Similarly, the use of an adenoid punch or avulsion with grasping forceps, under endoscopic vision, can cause trauma in nasopharyngeal structures (10). Complete and partial adenoidectomy with the microdebrider is faster than that with curettes, and due to greater control over tissue removal, it is safer as well (23).

Re-growth of adenoid tissue is due to residual tissue after inadequate surgery performed in early ages. In a prospective study, Cannon et al. (16) reported that residual tissue was always left after blind curettage adenoidectomy. In a similar study, Havas and Lowinger (17) reported that they found residual adenoid tissue at a rate of 39% when they assessed patients endoscopically after blind adenoidectomy. Authors have reported that re-growth incidence of adenoid tissue is high when blind adenoidectomy is performed.

In our study, residual tissue rate was particularly high in large adenoids (26%). Because these adenoids fill the nasopharynx and choana orifice, it is not possible to remove them with blind curettage. Another cause of adenoidectomy failure is choanal adenoids (24). Pearl and Manoukian (24) reported the rate of choanal adenoids as 9% in a study performed on 330 patients. These tissues located in the choanae can cause repeated surgeries if they are not noticed during the surgery. As seen in our study, blind curettage method was inadequate in extracting large adenoids filling the choanae.

The powered-shaver adenoidectomy technique is a very efficient technique that can be used to extract this residual tissue and prevent the patients from undergoing a second surgery and thus the possible associated risks. The precision of the microdebrider permits complete resection of tissue when desired, while enabling the surgeon to avoid damage to vital structures and excess removal of adenoid tissue inferiorly (25). However, the

disadvantage of the powered-shaver adenoidectomy technique is its higher cost when compared to the traditional curettage methods.

In conclusion, adenoidectomies, performed most commonly with blind curettage method in Turkey, are far from providing efficient results. In this study, we recommend the powered-shaver technique, which is a

safer and more comfortable method that does not cause damage to nasopharyngeal structures. However, if blind curettage method is preferred, we think that the nasopharynx should be re-assessed with mirror or 0° telescope, and residual tissue should be cleaned with powered-shaver adenoidectomy technique guided by transnasal videoendoscopy.

## References

1. Van Cauwenberge P, Bellusi L, Maw AR, Paradise JL, Solow B. The adenoid as a key factor in upper airway infection. *Int Paediatric Otolaryngol* 1995; 32(Suppl): 71-80.
2. Wang DY, Clement PA, Kaufman L, Derde MP. Chronic nasal obstruction in children: a fiberoptic study. *Rhinology* 1995; 33: 4-6.
3. Parker AJ, Maw AR, Powell JE. Rhinomanometry in the selection for adenoidectomy and its relation to preoperative radiology. *Int J Pediatr Otorhinolaryngol* 1989; 17(2): 155-61.
4. Shin JJ, Hartnick CJ. Pediatric endoscopic transnasal adenoid ablation. *Ann Otol Rhinol Laryngol* 2003; 112: 511-4.
5. Thornval A. Wilhelm Meyer and the adenoids. *Arch Otolaryngol Head Neck Surg* 1969; 90(3): 383-6.
6. Walker P. Paediatric adenoidectomy under vision using suction-diathermy ablation. *Laryngoscope* 2001; 111: 2173-7.
7. Hartley BE, Papsin BC, Albert DM. Suction diathermy adenoidectomy. *Clin Otolaryngol* 1998; 23: 308-9.
8. Rodriguez K, Murray N, Guarisco L. Power-assisted partial adenoidectomy. *Laryngoscope* 2002; 112: 26-8.
9. Koltai P, Chan J, Younes A. Power-assisted adenoidectomy: total and partial resection. *Laryngoscope* 2002; 112: 29-31.
10. Koltai PJ, Kalathia AS, Stanislaw P, Heras HA. Power assisted adenoidectomy. *Arch Otolaryngol Head Neck Surg* 1997; 123: 685-8.
11. Martinez SA, Akin DP. Laser tonsillectomy and adenoidectomy. *Otolaryngol Clin North Am* 1987; 20: 371-6.
12. Talbot H, Shore B. Adenotonsillectomy, technique and postoperative care. *Laryngoscope* 1965; 75: 1877-92.
13. Huang HM, Chao MC, Chen YL, Hsiao HR. A combined method of conventional and endoscopic adenoidectomy. *Laryngoscope* 1998; 108: 1104-6.
14. Becker SP, Roberts N, Coglianese D. Endoscopic adenoidectomy for relief of serous otitis media. *Laryngoscope* 1992; 102: 1379-84.
15. Huang HM, Chao MC, Chen YL, Hsiao HR. A combined method of conventional and endoscopic adenoidectomy. *Laryngoscope* 1998; 108: 1104-6.
16. Cannon CR, Replogle WH, Schenk MP. Endoscopic assisted adenoidectomy. *Otolaryngol Head Neck Surg* 1999; 121: 740-4.
17. Havas T, Lowinger D. Obstructive adenoid tissue: an indication for powered-shaver adenoidectomy. *Arch Otolaryngol Head Neck Surg* 2002 Jul; 128(7): 789-91.
18. Wang DY, Bernheim N, Kaufman L, Clement P. Assessment of adenoid size in children by fiberoptic examination. *Clin Otolaryngol Allied Sci* 1997 Apr; 22(2): 172-7.
19. Suzuki M, Watanabe T, Mogi G. Clinical, bacteriological and histological study of adenoids in children. *Am J Otolaryngol* 1999; 20: 85-90.
20. Cortin JM. The history of tonsil and adenoid surgery. *Otolaryngol Clin North Am* 1987; 20: 415-9.
21. Chisholm EJ, Lew-Gor S, Hajioff D, Caulfield H. Adenoid size assessment: a comparison of palpation, nasendoscopy and mirror examination. *Clin Otolaryngol* 2005; 30: 39-41.
22. Monroy A, Behar P, Brodsky L. Revision adenoidectomy--a retrospective study. *Int J Pediatr Otorhinolaryngol* 2008 May; 72(5): 565-70. Epub 2008 Mar 4.
23. Murray N, Fitzpatrick P, Guarisco JL. Powered partial adenoidectomy. *Arch Otolaryngol Head Neck Surg* 2002; 128(7): 792-6.
24. Pearl AJ, Manoukian JJ. Adenoidectomy: indirect visualisation of choanal adenoids. *J Otolaryngol* 1994; 23: 221-4.
25. Rodriguez K, Murray N, Guarisco JL. Power-assisted partial adenoidectomy. *Laryngoscope* 2002; 112(8 Pt 2 Suppl 100): 26-8.