

## Glass Particles in the Frontal Sinus

Sedat AYDIN  
Arif ŞANLI  
Mehmet EKEN  
Ümit HARDAL

**Abstract:** We present a patient that had a frontal sinus mucocele, which was the result of a traffic accident that occurred 3 years earlier. During surgery via the osteoplastic approach we observed glass particles in the left frontal sinus. As patients with foreign bodies in the paranasal sinus are not commonly seen in otolaryngological practice, especially glass particles in the frontal sinus, and papers dealing with this issue are rare in the English language literature, we present our case and a review of the literature.

**Key Words:** Frontal sinus, foreign body, glass particle, frontal mucocele

### Frontal Sinüste Cam Parçacıkları

**Özet:** Üç yıl önce geçirilen bir trafik kazası sonucunda frontal sinüs mukoseli gelişen bir hastamızı sunduk. Hastaya osteoplastik yaklaşımla müdahale ettiğimizde, sol frontal sinüs içinde cam partiküllerini saptadık. Otolarengolojik açıdan hastalarda paranasal sinüs yabancı cisimleri (özellikle frontal sinüs içindeki cam partikülleri) yaygın görülmediği ve bu konu ile ilgili yayınlanmış makaleler İngilizce literatürde sınırlı olduğundan, literatür bilgileri ışığında vakamızı sunmayı uygun bulduk.

**Anahtar Sözcükler:** Frontal sinüs, yabancı cisim, cam parçası, frontal mukosel

ENT II Department,  
Kartal Training and Research Hospital,  
İstanbul - TURKEY

### Introduction

The occurrence of a foreign body in the paranasal sinuses is extremely rare. Garces and Norris reported that about 70% of these foreign bodies are associated with some form of maxillofacial trauma, while 30% occur in patients that undergo surgical treatment for dental problems. A foreign body lodging in the frontal sinus is an even rarer occurrence (1). Foreign bodies in the paranasal sinuses cause vague symptoms. They are discovered either after the occurrence of complications or after radiological workup; therefore, they might be overlooked if their presence is not suspected (2).

We present a patient that had glass particles in his left frontal sinus. The glass was discovered following a mucocele complication 3 years after a traffic accident.

### Case Report

A 25-year-old male patient was referred to our ENT clinic with diplopia and dull frontal headache. Three years earlier he had been in a traffic accident, and suffered multiple lacerations and fractures to his face and body. He was sitting in the front seat of a car and was not wearing a seatbelt. At that time he had undergone neurological and orthopedic surgery. Afterwards, he suffered from gradually increasing diplopia and dull frontal headache. The patient was referred to our ENT clinic by the ophthalmology clinic due to enophthalmus and restriction of superior movement of the eye. Except for displacement of the left eye and scars on his face, results of the ENT examination were within normal limits. The patient complained of diplopia and dull frontal headache. Computed tomography (CT) revealed a 45 × 25 × 15-mm mucocele that obliterated the left frontal sinus and protruded into the upper-medial side of the orbit. The rest of the sinus cavity showed diffuse opacification. CT did not indicate a foreign body in the

Received: February 20, 2008  
Accepted: November 13, 2008

#### Correspondence

Sedat AYDIN  
ENT II Department,  
Kartal Training and Research  
Hospital, İstasyon Caddesi,  
Merdivenli Sokak Özkan Apt.  
No: 5 Daire: 6, 34860  
Kartal, İstanbul - TURKEY  
sedataydin63@yahoo.com

frontal sinus (Figure 1). Frontal sinus exploration was performed under general anesthesia via the osteoplastic approach, with which we observed a large pyomucocele and purulent discharge that completely blocked the left side of the frontal sinus. After excision of the pyomucocele, purulent discharge, and non-healthy sinus mucosa, we observed a bony defect (20 × 20 mm) in the posterior wall of the sinus and a slit-like opening in the dura. We also noted that the inferior bony wall of the left frontal sinus was completely eroded (Figure 2). In addition, many pieces of glass were seen in the left frontal sinus that were stuck to the lateral side of the left

peri-orbital soft tissue, and 1 piece of glass was observed in the ostium of the frontal sinus, which caused the obstruction of the sinus. All of the glass pieces that were observed were removed (Figure 3). A polyethylene drainage tube was inserted down through the enlarged nasofrontal duct and was sutured to the external nares. The patient did well after this surgery and was discharged on the seventh postoperative day. CT at the 4-month follow-up showed a clear frontal recess and sinus without opacity, except for a superomedially orbital defect (Figure 4). At 11 months postsurgery the patients was continuing to do well (Figure 5).

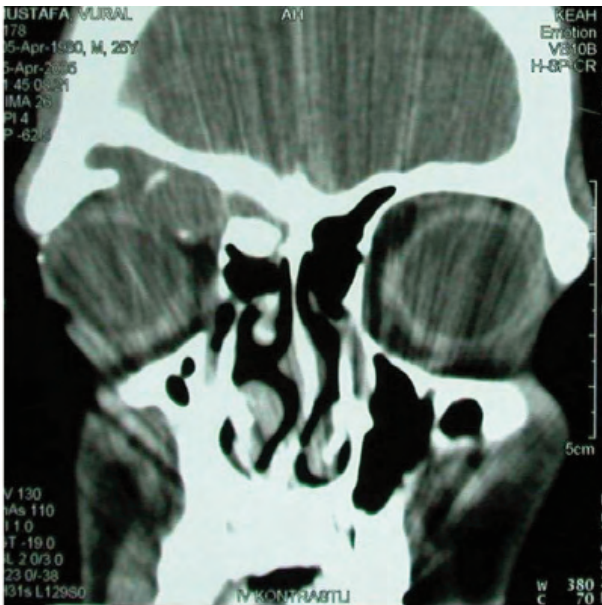


Figure 1. Preoperative coronal CT scan of the patient.

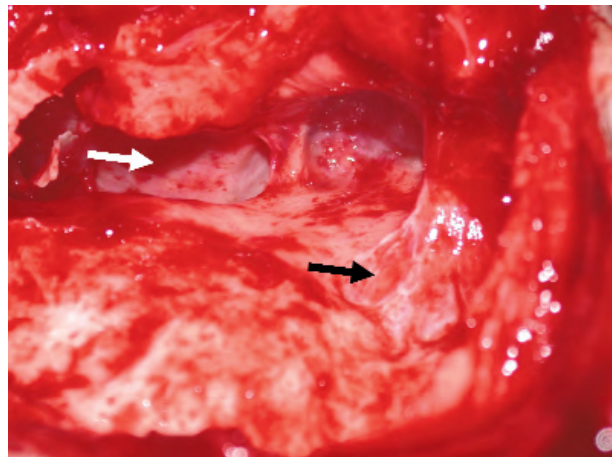


Figure 2. Supero-inferior view of the left frontal sinus cavity. Black arrow: Bony defect in the posterior wall of the sinus and a slit-like opening in the dura. White arrow: Posterior aspect of the ocular bulbus (location of the glass particles). Inferior bony wall of the left frontal sinus was completely absent.

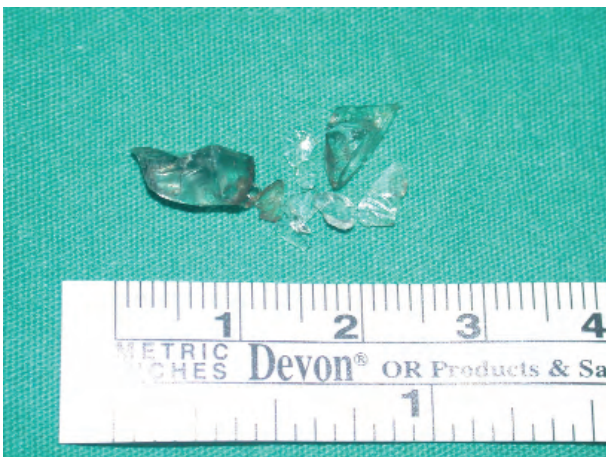

Figure 3. All glass particles were removed from the left frontal sinus.

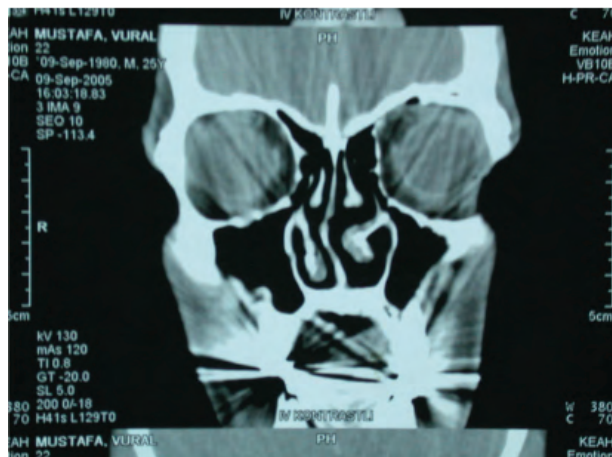

Figure 4. Coronal CT scan 4 months postsurgery.

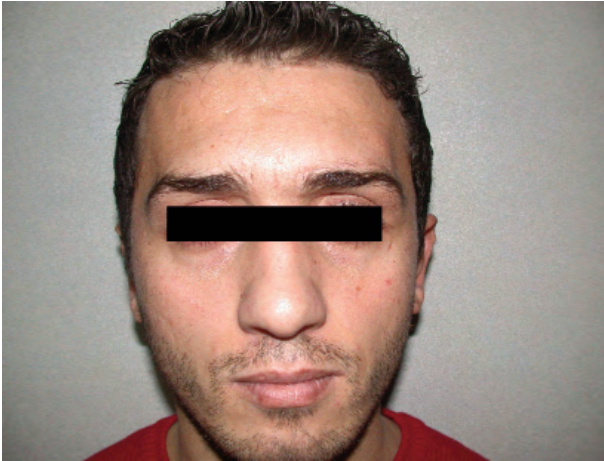

Figure 5. View of the patient at the 11-month follow-up.

## Discussion

Foreign bodies in the frontal sinuses are rare, but as the number of traffic accidents increases they may become more common. As a piece of glass is an inert foreign body, the patient may have no symptoms, although recurrent infection or obstructions of the nasofrontal duct are possible; therefore, the presence of foreign bodies should be suspected, even in seemingly trivial lacerations in cases of maxillofacial trauma (1-3).

More than 50% of foreign bodies in the paranasal sinuses occur in the maxillary sinus. The foreign body incidence rates in the frontal, ethmoid, and sphenoid

sinuses are nearly equal. A wide variety of foreign bodies has been reported in the paranasal sinuses, including retained roots of teeth and fillings, wood or bamboo splinters, pieces of cotton or gauze, bullets, shrapnel, knife blades, and glass fragments (1-7). Glass may be present for weeks or years, with chronic sinusitis or frontal headaches being the only symptoms. If diagnosis and treatment of these patients is delayed, they may develop severe headache caused by obstruction of the frontal duct and recurrent infection of the sinus (2-7). In the presented case, history of a traffic accident and frontal mucocele together with some eye problems compelled us to consider the possibility of a foreign body in the frontal sinus.

We preferred the osteoplastic approach to the transnasal endoscopic approach suggested by Tosun et al. (4), because the nasofrontal ductus was blocked and multiple pieces of glass were located at the farthest lateral to the left frontal sinus.

The importance of complete wound exploration in cases of frontal sinus trauma cannot be overstated. Digital palpation through the wound, in combination with direct visualization of the underlying bone, should be attempted whenever the possibility of a penetrating trauma to the frontal sinus exists. For all maxillofacial trauma patients with skin laceration over the paranasal sinuses, suspicion of foreign bodies is critical and may prevent the possibility of intracranial and intrasinus complications.

## References

1. Garces SM, Norris CW. Unusual frontal sinus foreign body. *Journal of Laryngology and Otology*. 1972; 86: 1265-1268.
2. Onerci M, Ogretmenoglu O, Yilmaz T. Glass in the frontal sinus: report of three cases. *J Laryngol Otol* 1997; 111: 156-8.
3. Payne RF. Foreign bodies in the frontal sinus. *British Journal of Radiology*. 1967; 40: 778-780.
4. Tosun F, Ozkaptan Y. Practical approach to foreign bodies in the frontal sinus. *Otolaryngol Head Neck Surg* 2000; 122: 928-9.
5. Hara A, Kusakari J, Shinohara A, Yamada Y, Sato N. Intrusion of an incisor tooth into the contralateral frontal sinus following trauma. *J Laryngol Otol* 1993; 107: 240-1.
6. Kaplan AS, Green JD Jr, McCaffrey TV. Unsuspected foreign body in the frontal sinus and anterior cranial fossa. *Ann Emerg Med* 1989; 18: 988-90.
7. Lancer JM. Glass in the frontal sinus. *J Laryngol Otol* 1982; 96: 357-60.