

Local Recurrence of Giant Renal Cell Carcinoma without Distant Metastases 25 Years after Radical Nephrectomy

Turgut YAPANOĞLU¹
Yılmaz AKSOY¹
İsa ÖZBEY¹
Cemal GÜNDOĞDU²
Özkan POLAT¹

Abstract: A 64-year-old man underwent a left radical nephrectomy 25 years ago. The pathological examination revealed renal cell carcinoma (RCC) and no lymph node metastasis. He suffered a recurrence in the renal fossa 25 years after the operation. To our knowledge, this is the first report of late (about 25 years) recurrence of RCC without distant metastases after radical nephrectomy. The isolated fossa recurrence of RCC without any distant metastasis is very uncommon. We suggest that the patients with RCC who underwent radical nephrectomy should undergo lifelong follow up.

Key Words: Renal cell carcinoma, radical nephrectomy, late recurrence

Radikal Nefrektomiden 25 Yıl Sonra Görülen Uzak Metastaz Olmaksızın Dev Lokal Nüks

¹ Department of Urology,
Faculty of Medicine,
Atatürk University,
Erzurum - TURKEY

² Department of Pathology,
Faculty of Medicine,
Atatürk University,
Erzurum - TURKEY

Özet: Yirmibeş yıl önce sol radikal nefrektomi ameliyatı olan altmışdört yaşında bir erkek hastanın, patolojik tanısı renal hücreli karsinom olarak rapor edilmiştir ve hastada lenf nodu metastazı saptanmamıştır. Operasyondan 25 yıl sonra renal fossada nüks saptanmıştır. Bizim bilgilerimize göre hasta, 25 yıl sonra uzak metastaz olmaksızın renal fossada metastaz saptanan ilk olgudur. Herhangi bir uzak metastaz olmaksızın izole fossa rekürrensi oldukça nadir görülür. Biz radikal nefrektomi yapılan olguların hayat boyu izlenmelerini önermekteyiz.

Anahtar Sözcükler: Renal hücreli karsinom, radikal nefrektomi, geç rekürrens

Introduction

The isolated fossa recurrence of renal cell carcinoma (RCC) without any distant metastasis is very uncommon. It is not clear whether fossa recurrence is a variant of an advanced disease; however, patients with local early recurrence have a poor prognosis (1). In advanced or focal recurrence of RCC, traditional treatment modalities, such as chemotherapy, immunotherapy, and hormone therapy give disappointing results (2). The treatment of local recurrences without any distant metastasis is mainly surgical, and the purpose is to excise the whole fossa recurrence, if possible.

Case Report

A 64-year-old man was admitted to our clinic in September 2005 with a 1-month history of left lumbar swelling and lumbar pain. Medical history revealed discomfort during the preceding 2 months, but no apparent episodes of paraneoplastic syndromes, such as hypoglycemia or other hormonal abnormalities were observed. His background history included that a left renal mass occurred 25 years ago. A left radical nephrectomy was performed and histopathological examination confirmed RCC in our department (Figure 1). Abdominal sonography and computed tomography (CT) showed a heterogenic mass sized 15 × 13 × 22 cm in the left renal fossa (Figure 2A). No distant metastases were determined with advanced radiological technologies such as CT, magnetic resonance imaging (MRI), and radionuclide studies in lungs, abdominal visceral organs, brain, and bones. Ultrasonography-guided needle biopsy of the left retroperitoneal mass provided evidence of RCC pattern (Figure 2B). The patient refused surgical intervention and was discharged.

Received: April 24, 2008
Accepted: December 03, 2008

Correspondence

Turgut YAPANOĞLU
Department of Urology,
Faculty of Medicine,
Atatürk University,
25240 Erzurum - TURKEY

turgutyapanoglu@mynet.com

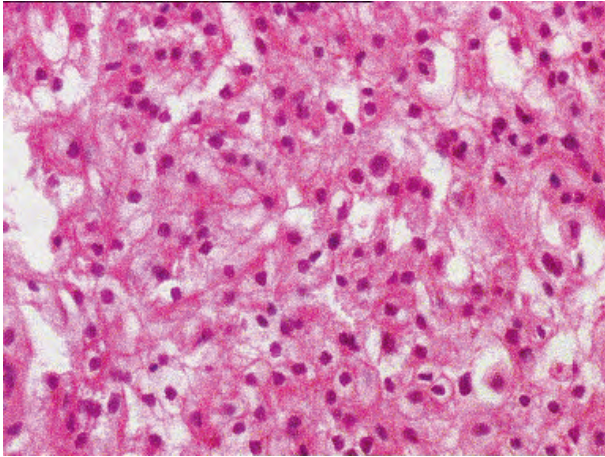


Figure 1. The tumor cells are composed predominantly of dead cells, with fewer granular cells in a tubular pattern (H and E $\times 100$).

Discussion

The incidence of metastatic disease at diagnosis is 25% to 50%, and after nephrectomy metastatic disease will develop in approximately 50% of RCC (3). Delayed recurrence is one of the biological behaviors specific for RCC (4). Reports of renal fossa recurrences include series with widely metastatic disease and anecdotal case reports of isolated RCC recurrences, such as the present report. Recurrence in patients with RCC, who underwent nephrectomy, usually occurs within 5 years after the operation. However, it has been reported that recurrence may occur many years after nephrectomy. Mc Nicols et al. (5) reported that 18 of 158 patients (11%) developed recurrence 10 years after nephrectomy. Nakano et al. (6) reported that among 43 patients who received curative

nephrectomy, 2 patients (4.7%) developed recurrence more than 10 years after the operation. However, the risk factors for such recurrence have not been fully elucidated.

The prognosis in patients with localized RCC after nephrectomy is highly influenced by the pathological tumor stage (7). More than 75% of patients undergoing nephrectomy in Stephenson's study had organ confined lesions (PT_{1-2}), of which an estimated 91% were free of relapse at 5 years. In contrast, an estimated 38% of patients with locally advanced disease (PT_{3A-B}) had relapse within 3 years postoperatively (4).

It is not clear whether isolated fossa recurrence is part of metastatic disease or should be thought of as just like local disease, but it is known that patients with local recurrence after radical nephrectomy have an unfavorable prognosis and show distant metastasis sooner or later. Because other treatment modalities, such as chemotherapy, immunotherapy, and hormonotherapy, in advanced RCC give disappointing results (1), the accepted strategy for isolated fossa recurrences is the removal of the local recurrence surgically.

Despite several case reports about RCC recurrence, to our knowledge, local recurrence of RCC 25 years after radical nephrectomy has not been reported before. We also think that the slow recurrence of our case is due to its low grade. Even though the patients have low grade carcinoma, they should be followed closely for years after radical nephrectomy. Annual clinical assessment is recommended, including biochemical profile, chest x-ray, and abdominal USG.

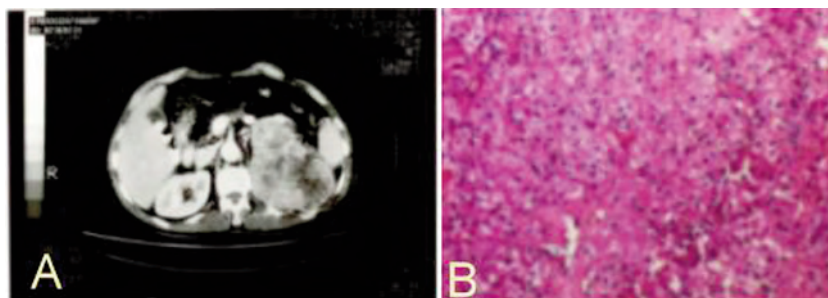


Figure 2. A: Abdominal computed tomography showed a heterogenic mass sized $15 \times 13 \times 12$ cm in the left renal fossa. B: The tumor cells are nest pattern and exclusively of the granular cells (H and E $\times 200$).

References

1. Gogus C, Baltaci S, Beduk Y, Sahinli S, Kupeli S, Gogus O. Isolated local recurrence of renal cell carcinoma after radical nephrectomy: experience with 10 cases. *Urology* 2003; 61: 926-929
2. Swanson A. Surgery for metastases of renal cell carcinoma. *Scand J Surg* 2004; 93: 150-155
3. Uchida K, Miyao N, Masumori N, Takahashi A, Oda T, Yanase M et al. Recurrence of renal cell carcinoma more than 5 years after nephrectomy. *Int J Urol* 2002; 9: 19-23
4. Stephenson AJ, Chetner MP, Rourke K, Gleave ME, Signaevsky M, Palmer B et al. Guidelines for the surveillance of localized renal cell carcinoma based on the patterns of relapse after nephrectomy. *J Urol* 2004; 172: 58-62
5. Mc Nichols DW, Segura JW, Deweerd JH. Renal cell carcinoma: Long-term survival and late recurrence. *J Urol* 1981; 126: 17-23.
6. Nakano E, Fujioka H, Matsuda M, Osafune M, Takaha M, Sonoda T. Late recurrence of renal cell carcinoma after nephrectomy. *Eur Urol* 1984;10: 347-349
7. Itano NB, Blute ML, Spotts B, Zincke H . Outcome of isolated renal cell carcinoma fossa recurrence after nephrectomy. *J Urol* 2000; 164: 322-325.