

Dilek SOYSAL<sup>1</sup>  
Ebru TÜRKKAN<sup>1</sup>  
Volkan KARAKUŞ<sup>1</sup>  
Erhan TATAR<sup>1</sup>  
Özlem Yersal KABAYEĞİT<sup>1</sup>  
Arzu AVCI<sup>2</sup>

## A case of common variable immunodeficiency disease and thyroid amyloidosis

**Abstract:** A 37-year-old male patient with fever, mild respiratory distress, diffuse goiter, and hepatosplenomegaly was admitted to our hospital. Clinical and laboratory findings showed that he had recurrent respiratory tract infections—namely bronchiectasis—due to common variable immunodeficiency disease (CVID) and AA-type amyloid deposition in the thyroid gland. Although recurrent infections as a consequence of inadequate gammaglobulin (IVIG) substitution therapy are regarded as the main cause of the development of amyloidosis, amyloidosis in a patient with hypo/agammaglobulinemia is extremely rare. In this report we discuss the association of CVID and recurrent respiratory tract infections with secondary amyloidosis restricted to one organ, the thyroid gland, which is an uncommon site for amyloid deposition.

Key Words: Common variable immunodeficiency, thyroid, amyloidosis

<sup>1</sup> Department of Internal Medicine,  
Atatürk Research and Training  
Hospital, İzmir - TURKEY

<sup>2</sup> Department of Pathology,  
Atatürk Research and Training  
Hospital, İzmir - TURKEY

### Yaygın değişken immun yetmezlik hastalığı ve tiroid amiloidozu olan bir olgu

**Özet:** Otuzyediyedi yaşında erkek hasta ateş, hafif düzeyde solunum sıkıntısı, difüz guatr ve hepatosplenomegali bulgularıyla hastaneye kabul edildi. Klinik ve laboratuvar bulguları hastanın yaygın değişken immun yetmezlik hastalığına (YDIYH) bağlı tekrarlayan solunum yolu enfeksiyonlarının, bronşektazisinin, ve tiroid bezinde AA tipi amiloid birikiminin olduğunu gösterdi. Tekrarlayan enfeksiyonlarda gammaglobulin (IVIG) ile yetersiz tedavinin amiloidoz gelişmesinin başlıca nedeni olduğu şeklinde görüş bulunsa da, hipo veya agammaglobulinemili hastalarda amiloidoz görülmesi oldukça nadirdir. Bu makalede biz, YDIYH ve tekrarlayan solunum yolu enfeksiyonları ile tek bir organa, tiroid bezine, sınırlı sekonder amiloidozun birlikteliğini amiloid birikiminin nadir görüldüğü bir yer olması nedeni ile tartıştık.

Anahtar Sözcükler: Yaygın değişken immun yetmezlik, tiroid, amiloidoz

Received: December 12, 2007  
Accepted: January 12, 2009

#### Correspondence

Dilek SOYSAL  
Manolya Sokak,  
Töbaş Sitesi, No: 44/4  
Balçova, İzmir - TURKEY

dileksoysal@hotmail.com

#### Introduction

Common variable immunodeficiency (CVID) is a primary immunodeficiency disease characterized by decreased (or absent) immunoglobulin level, and recurrent bacterial infections of the respiratory and gastrointestinal tracts due to highly virulent encapsulated extracellular bacteria, which is most commonly seen in adolescents and young adults (1-5). Patients with CVID may also present with signs and symptoms suggestive of lymphoid malignancy, including fever, weight loss, anemia, thrombocytopenia, splenomegaly, generalized lymphadenopathy, and lymphocytosis (6).

The underlying problem is a failure of B cells to differentiate into plasma cells that secrete Igs. The mechanisms suggested to be responsible for this failure have included an intrinsic defect in B cells resulting in abnormal terminal

differentiation, deranged T-cell regulation with either too much suppressive activity or too little helper activity, or in rare cases the presence of autoantibodies to T or B cells (2,3,5).

Amyloidosis in a patient with hypo/agammaglobulinemia is extremely rare (7). Amyloidosis is a group of diseases, all characterized by deposition of protein fibrils with a  $\beta$ -sheet structure. Amyloid fibrils are derived from different protein precursors and variation in the clinical picture of systemic amyloidosis is related to the type of precursor involved (8,9).

We describe herein a patient with recurrent respiratory tract infections induced by hypogammaglobulinemia and associated with AA-type amyloidosis of the thyroid gland.

### Case Report

A 37-year-old man with a medical history of recurrent respiratory tract infections that began when he was 15 years old was referred to our hospital for the evaluation of his goiter. Upon hospital admission the patient was alert, malnourished, and had mild respiratory distress with fever.

#### Physical examination

On physical examination his BP was 110/70 mmHg, heart rate was 108 beats/min and regular, respiratory rate was 28 breaths/min, oxygen saturation was 92% on room air, and body temperature was 38 °C. The thyroid gland was palpable. Lung examination revealed prolonged expiration with bilateral scattered rhonchi and decreased respiratory sounds in the lower lung fields. Cardiac examination was unremarkable. Abdominal examination revealed hepatosplenomegaly. The patient did not have diarrhea. Bilateral minimal pedal edema was observed.

#### Laboratory findings

The patient's WBC count was  $10.8 \times 10^3$  cells/ $\mu$ l (neutrophils 73%) and hemoglobin level was 11.7 g/dl. Creatinine clearance was 89 ml/min. Plasma albumin concentration was 4.2 g/dl (normal: 3.5-5.0 g/dl), globulin concentration was 1.4 g/dl (normal:

1.1-3.5 g/dl). Protein electrophoresis results were as follows: albumin, 69.1% (normal: 60%-71%); alpha-1 globulin, 4.8% (normal: 1.4%-2.9%); alpha-2 globulin, 15.2% (normal: 7%-11%); beta globulin, 9.9% (normal: 8%-13%); gammaglobulin, 1.0% (normal: 11%-18.6%). Serum IgG level was 0 mg/dl (normal: 540-1822 mg/dl), IgM was 0 mg/dl (normal: 22-240 mg/dl), and IgA was 2 mg/dl (normal: 63-484 mg/dl). Serum and urine immunoelectrophoresis for kappa and lambda light chains were negative. C<sub>3</sub> and C<sub>4</sub> complement levels were normal—95 mg/dl and 25 mg/dl, respectively. Beta-2 microglobulin was negative (normal: < 0.22 mg/dl).

The erythrocyte sedimentation rate (ESR) was 42 mm/h; hsCRP was 12.5 mg/l (normal: 0-5 mg/l); RF was negative. Thyroid function test results were within normal ranges: free T<sub>3</sub>, 2.27 pg/ml; free T<sub>4</sub>, 1.10 ng/dl; TSH, 2.51  $\mu$ IU/ml. Antibodies directed against microsomes (TPO) were 8.3 IU/ml (normal 0-60 IU/ml), against thyroglobulin (anti T) were 54.3 IU/ml (normal 0-60 IU/ml), and against TSH receptor (TRAb) were 8 U/l (normal 0-9 IU/ml).

Antinuclear antibody, cytoplasmic and perinuclear antineutrophilic cytoplasmic antibodies, anti-ds DNA antibody, autoantibodies for autoimmune hepatitis, and antigliadin IgA and IgG were negative.

Fungal serology for aspergillosis and serology for HBV, HCV, HIV, HSV, CMV, EBV, toxoplasma, rubella, *Salmonella typhi*, and *Brucella mellitensis* were negative. Tuberculin skin test was negative (6 mm induration). Acid-fast bacilli in sputum smears and sputum culture for mycobacterium tuberculosis in Lowenstein media were negative. Sputum cultures revealed *Pseudomonas aeruginosa* and *Escherichia coli* on separate occasions. Stool culture was negative for ova and parasites.

Fine needle aspiration biopsy of the thyroid gland showed amorphous eosinophilic material of amyloid deposition within the gland, which stained positive with Congo red. Biopsy samples from the rectum, and subcutaneous tissue of the abdomen and bone marrow were negative for amyloid staining. A bone marrow specimen showed no signs of plasma cell dyscrasias.

### Radiographic findings

High resolution computed tomography (HRCT) of the lungs revealed bilateral bronchiectasis and mediastinal and hilar lymphadenopathy < 10 mm. Abdominopelvic CT showed mild, diffuse hepatosplenomegaly, but no other pathological findings. Both US and scanning of the thyroid showed grade 4 diffuse enlargement of the gland, the former with a heterogeneous parenchyma and the latter with decreased tracer uptake. Echocardiography showed moderate pulmonary hypertension (mean pulmonary artery pressure: 50 mmHg) with mild tricuspid regurgitation and right heart dilatation. The ECG was normal.

### Clinical course

Based on sputum culture results, cefepime (1 g/day, bid, IV) was commenced.

The patient could not perform the pulmonary function tests with a spirometer; therefore, he was followed-up with arterial blood gas analysis. Although his clinical condition did not improve, antibiotic therapy was discontinued after 4 weeks because the repeated cultures were negative. Intravenous immunoglobulin replacement of 400 mg/kg once every 3 weeks was continued during the course.

By the end of the sixth week of hospitalization the patient underwent total thyroidectomy due to pressure exerted on his trachea and esophagus caused by grade 4 diffuse enlargement of the thyroid gland (Figures 1 and 2). Two weeks postsurgery L-thyroxin (25 µg/day, po) was started.

A rise in the patient's body temperature and a recurrent productive cough led to our repeating sputum cultures and HRCT. Bilateral bronchiectasis with minimal pleural effusion on the right lung, and emphysematous bulla on the medial lobe and lingula with secondary fibrotic changes were evident. Sputum cultures revealed methicillin-resistant *Staphylococcus aureus* (MRSA) and vancomycin (1 g/day, bid, IV) was commenced.

By the end of the third month of hospitalization the patient developed severe respiratory failure and was then supported by mechanical ventilation. He also suffered from generalized convulsions and

phenytoin (100 mg/day, tid) was administered through a nasogastric tube. Despite treatment with appropriate therapeutic doses of IVIG and antibiotic regimens based on microbiological findings, the patient died of severe sepsis 3 months after his admission to the hospital.

### Histological findings

The thyroid gland appeared yellowish in macroscopic cross-sectional view. The thyroid gland's follicular structure, with an amorphous, homogeneous pink substance, was established based on H&E staining (Figure 3). Histological findings of the thyroidectomy material stained with Congo red showed that the amorphous eosinophilic material within the subepithelium of the thyroid follicles and walls of the sinusoidal capillaries was amyloid deposition (Figures 4 and 5).

Forward examination with monoclonal antibodies against serum amyloid A protein (SAA) showed that the deposits of amyloid seen in the subepithelial border of the follicles and walls of the sinusoidal capillaries were AA amyloid (Figure 6). Following this finding, mutations of the MEFV gene of M694V and V726A were studied and deemed negative. These mutations are associated with familial Mediterranean fever (FMF) and with AA amyloidosis (10).

### Discussion

Common variable immunodeficiency disease, also known as idiopathic, congenital non-x-linked, acquired, or late-onset hypogammaglobulinemia, is a heterogeneous disorder characterized by low serum levels of IgG, IgA, and IgM, inability to form antibodies to antigen, and the absence of gross defects in cell-mediated immunity (2,3,6). Importantly, more than 50% of patients have T-cell abnormalities, including decreased lymphocyte response to mitogens and microbial antigens (1).

Patients with hypogammaglobulinemia are susceptible to repeated and persistent infections, especially bacterial pneumonia, bronchitis, and sinusitis (2,7). The involved pathogens are typically virulent encapsulated extracellular organisms, such as *Haemophilus influenzae*, *Streptococcus*

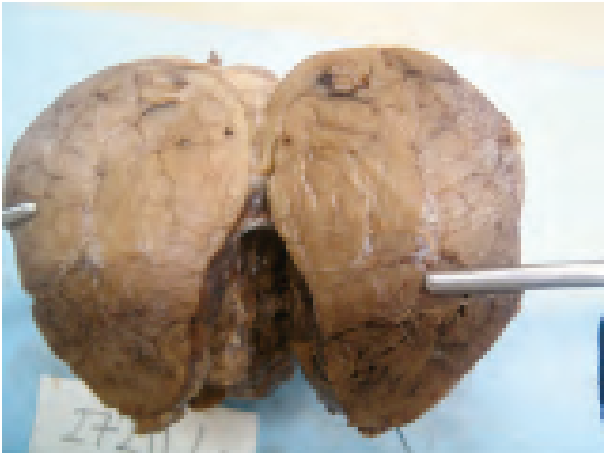

Figure 1. Macroscopic appearance of the thyroid gland after surgery.

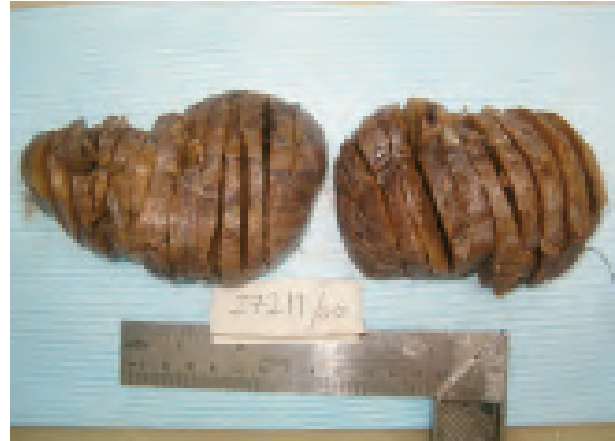

Figure 2. Cross-sectional view of the thyroid gland.

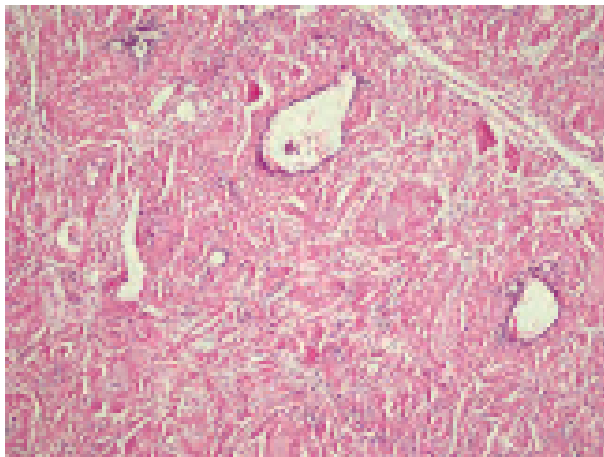


Figure 3. Follicular structure of the thyroid and the amorphous, homogeneous pink substance (H&E stain, 100 $\times$ ).




Figure 4. Thyroid biopsy specimen shows amorphous eosinophilic material (amyloid) deposited within the subepithelium of the thyroid follicles and walls of the sinusoidal capillaries (Congo red, 100 $\times$ ).

*pneumoniae*, and *Staphylococcus aureus*, followed by *Pseudomonas aeruginosa* (2,3,5). Bronchiectasis is also considered a typical feature in patients with B-cell disorders (2,3). In our patient the extent of this abnormality was indicated by HRCT results, and *Pseudomonas aeruginosa* and *Escherichia coli* were determined to be the responsible microorganisms of his respiratory tract infection.

The discrepancy between our patient's low total serum protein and the normal level of albumin raised the suspicion of globulin deficiency; this diagnosis was validated based on serum protein

electrophoresis and quantitative measurement of serum Igs.

The radiographic and laboratory findings of the patient excluded the presence of any type of neoplasia, especially hematological disease. The incidence of malignant lesions increases considerably in patients with primary immunodeficiency disorders (3,6). Autoimmune diseases, such as idiopathic thrombocytopenic purpura, RA, SLE, primary biliary cirrhosis, and thyroid abnormalities, have been reported to occur in 20% of these patients in anecdotal reports (3).




Figure 5. Apple-green birefringence of massive amyloid deposition beneath the follicle cells and within the walls of the blood vessels of the thyroid gland, as seen with polarized light (Congo-red, 100 $\times$ ).

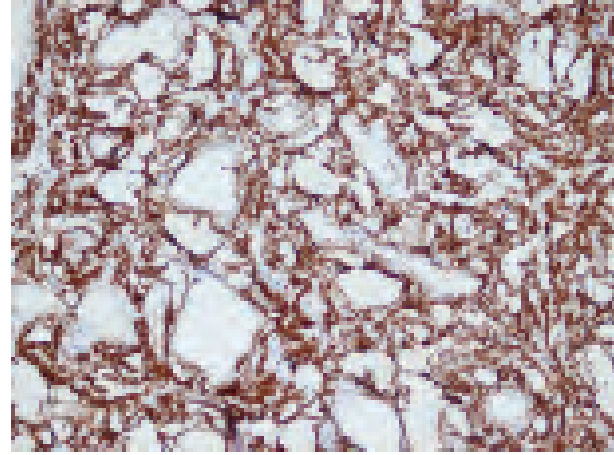


Figure 6. Thyroid biopsy specimen with AA amyloidosis. Deposits of AA amyloid are seen in the subepithelial border of the follicles and walls of the sinusoidal capillaries. Amyloid is brown in the immunoperoxidase stain with monoclonal antibodies against SAA (amyloid A component Ab-1 (clone mcl)  $\times 200$ ).

Underdiagnosis, diagnostic delay, and management with a variety of methods contribute to morbidity and early mortality. There is an average diagnostic delay of 2.5 years in children and 5.5 years in adults (4). Morbidity is most commonly due to acute or chronic respiratory infections that lead to respiratory failure, as in our patient, with a mean age at death of 28.8 years among males (4), although our patient died at the age of 35 years.

To lower the morbidity and mortality rates in CVID early identification of respiratory tract infections, providing logical antibiotic treatment based on microbiological findings, and optimization of IVIG dosage should be considered for each patient. The appropriate therapeutic dosage of IVIG is reported to be 300-400 mg/kg once every 3-4 weeks, although there are still some conflicting results (5). As a case of delayed diagnosis, our patient did not respond to the appropriate IVIG regimen or antibiotics and died of severe sepsis.

Amyloidosis in a patient with hypo/agammaglobulinemia is extremely rare; however, recurrent infections as a consequence of inadequate gammaglobulin substitution therapy, like in our case, are regarded as the main cause of the development of amyloidosis (7). Amyloid fibrils are derived from different protein precursors. The

process by which these fibrils are produced appears to be multifactorial and differs amongst the various types of amyloid. In reactive systemic (secondary AA) amyloidosis, which is related to chronic inflammatory disorders and chronic infection, clinical features depend on the nature of the underlying disorder. AA amyloidosis often presents with renal disease, autonomic neuropathy, hepatomegaly, and splenomegaly. Macroglossia is not a feature and cardiac involvement is rare (8,9,11). In AL amyloidosis (immunoglobulin light chain-associated or primary) there is a clonal dominance of amyloid light (AL) chains—either the dominant  $\kappa$  or  $\lambda$  isotypes—which are excreted in urine (Bence Jones proteins). This type of amyloid is often associated with lymphoproliferative disorders, such as myeloma, Waldenström's macroglobulinemia, or non-Hodgkin's lymphoma. It rarely occurs before the age of 40 years (11). Clinical manifestations are very diverse and include cardiomyopathy, nephrotic syndrome, renal failure, orthostatic hypotension, diarrhea, peripheral and autonomic neuropathy, carpal tunnel syndrome, and macroglossia (about 10%) (8,11). Deposition of amyloid can be localized (restricted to one organ or site of the body) or systemic (in various organs and tissues throughout the body), and diagnosis is based on proof of its presence in tissue (8,9). In our case



amyloidosis was identified after thyroidectomy material was examined by our pathologist and, therefore, we used the other primary biopsy sites—fat, rectum, and bone marrow, which were all negative, for amyloid staining. Serum amyloid A protein (SAA), an acute phase reactant, was the precursor protein in our patient and the case was secondary amyloidosis caused by longstanding inflammation (8,11), most probably due to recurrent bacterial respiratory tract infections during the course of CVID. The behavior of SAA during inflammation was comparable with another acute phase reactant, C-reactive protein (CRP) (8), and test results showed high titers in our patient's sera. The patient was examined for chronic inflammatory disorders, including rheumatoid arthritis, tuberculosis, and familial Mediterranean fever—one of the major causes of secondary amyloidosis in Turkey (7,10). The patient did not have a history of FMF and gene mutations for FMF were negative. RF was negative and no signs or symptoms of tuberculosis were observed.

In the presented case renal manifestations such as proteinuria and loss of renal function, and peripheral and autonomic neuropathy, and gastrointestinal manifestations such as diarrhea were not observed. Cardiomyopathy, especially the restrictive type, was excluded based on echocardiography. In our case echocardiographic findings showed moderate pulmonary hypertension—a chronic pulmonary complication caused by recurrent respiratory tract infections—with mild tricuspid regurgitation and right heart

dilatation, resulting in chronic cor pulmonale, which was consistent with congestive hepatomegaly and pedal edema. Electrocardiography showed no signs of low voltage or pseudo-anteroseptal infarction of restrictive cardiomyopathy (12).

Extracellular deposition of amyloid fibrils in organs and tissues results in loss of organ function and may cause prominent swelling in affected organs or tissues (8). Deposition of SAA protein within the thyroid gland in our patient caused diffuse enlargement of the gland with pressure exerted on the trachea and esophagus, but without loss of function. Immunohistochemistry of the biopsy samples from the thyroid gland helped us characterize the type of amyloid by using specific antibodies.

A stepwise approach to patients with systemic or localized amyloidosis requires histological proof of amyloid, verification of systemic or localized involvement, and assessment of the particular type of amyloid and its precursor to complete the clinical evaluation necessary for assessment of the prognosis and therapeutic course.

Herein we discussed the association between CVID and secondary (AA) amyloidosis restricted to one organ, thyroid gland, which is an uncommon site for amyloid deposition. In AA amyloidosis treatment is aimed at decreasing SAA serum levels to normal basal values (< 3 mg/l). This aim can only be achieved with complete suppression or eradication of the underlying chronic inflammation (8).

## References

1. Di Renzo M, Pasqui AL, Auteri A. Common variable immunodeficiency: a review. *Clin Exp Med* 2004; 3: 211-217.
2. Sacco O, Fregonese B, Picco P, Faraci M, Facchetti P, Pistoia V et al. Common variable immunodeficiency presenting in a girl as lung infiltrates and mediastinal adenopathies leading to severe "superior vena caval" syndrome. *Eur Respir J* 1996; 9: 1958-1961.
3. El-Solh A, Sikka P, Draw A. A 58-year old woman with recurrent productive cough and diarrhea. *Chest* 2000; 118: 1194-1197.
4. Thickett KM, Kumararatne DS, Banerjee AK, Dudley R, Stableforth DE. Common variable immune deficiency: respiratory manifestations, pulmonary function and high-resolution CT scan findings. *QJ Med* 2002; 95: 655-662.
5. Pourpak Z, Aghamohammadi A, Sedighipour L, Farhoudi A, Movahedi M, Gharagozlou M et al. Effect of regular intravenous immunoglobulin therapy on prevention of pneumonia in patients with common variable immunodeficiency. *J Microbiol Immunol Infect* 2006; 39:114-120.

6. Delia M, Liso V, Capalbo S, Napoli A, Ricco R, Semenzato G et al. Common variable immunodeficiency patient with large granular lymphocytosis developing extranodal diffuse large B-cell lymphoma: a case report. *Haematologica* 2006; 91: 13-14.
7. Kotilainen P, Vuori K, Kainulainen L, Aho H, Saario R, Asola M et al. Systemic amyloidosis in a patient with hypogammaglobulinemia. *J Int Med* 1996; 240: 103-106.
8. Hazenberg BPC, Van Gameren II, Bijzet J, Jager PL, van Rijswijk MH. Diagnostic and therapeutic approach of systemic amyloidosis. *Neth J Med* 2004; 62: 121-128.
9. Merlini G, Bellotti V. Molecular mechanisms of amyloidosis. *N Eng J Med* 2003; 349: 583-596.
10. Çelik AF, Altıparmak MR, Pamuk GE, Pamuk ÖN, Tabak F. Association of secondary amyloidosis with common variable immune deficiency and tuberculosis. *Yonsei Med J* 2005; 46: 847-850.
11. Gale EAM, Anderson JV. Diabetes mellitus and other disorders of metabolism. In: Kumar P, Clark M, eds. *Clinical Medicine*. 6th edn. Spain: Elsevier Saunders; 2005. P. 1147-1148.
12. Johnston SL, Hill SJ, Lock RJ, Dwight JF, Unsworth DJ, Gompels MM. Echocardiographic abnormalities in primary antibody deficiency. *Postgrad Med J* 2004; 80: 214-218.