

Cervical spine movement during intubation using the Airtraq® and direct laryngoscopy

İ. Aydın ERDEN¹, A. Gülsün PAMUK¹, Şennur UZUN¹, Serdar GEYİK², Saruhan ÇEKİRGE², Ülkü AYPAR¹

Aim: To compare 2 endotracheal intubation techniques, namely direct laryngoscopy and Airtraq®, according to their influence on cervical spine movement and intubation time and success rates, complications, and hemodynamic responses.

Materials and methods: Thirty three patients without cervical spine problems were enrolled in the study. Patients were randomized into direct laryngoscopy and Airtraq® groups. Assessment of movement of the cervical spine was made by taking 3 lateral cervical spine X-rays. First, when the cervical spine was in the neutral position, second during the greatest excursion of the cervical spine, and finally, after intubation. A reference line was drawn following the dorsal alignment of C2. Two other lines were drawn, one connecting the anterior and posterior arch of the atlas (C1) and the second through the basal plate of C3. The angle with the C1 arch line was called α and with the C3 line was called β .

Results: The duration of intubation was significantly longer in the Airtraq® group. Although there was a statistically borderline significant difference between groups during intubation at the mean change of β angle ($P = 0.054$), within group differences were similar in the 2 groups ($P = 0.4$).

Conclusion: As a result, we do not recommend intubation via Airtraq® as an alternative to the direct laryngoscopy in cervical spine injuries.

Key words: Intubation, laryngoscope, cervical vertebrae

Airtraq® ve direkt laringoskopi kullanılarak yapılan entübasyon sırasında servikal vertebra hareketleri

Amaç: Biz bu çalışmada Airtraq® ve direkt laringoskopi isimli iki endotrakeal entübasyon tekniğini, servikal vertebra hareketleri üzerine etkisi, entübasyon süresi, başarı oranı, komplikasyonlar, ve hemodinamik cevaplar açısından karşılaştırmayı amaçladık.

Yöntem ve gereç: Servikal vertebra problemi olmayan 33 hasta çalışmaya dahil edildi. Hastalar randomize olarak Airtraq® veya direkt laringoskopi gruplarından birisine alındı. Servikal vertebra hareketlerini değerlendirmek için üç tane lateral servikal vertebra filmi çekildi. İlki nötral pozisyonda, ikincisi servikal vertebranın en çok ekskürsiyona geldiğinde ve üçüncüsü entübasyondan sonraydı. C2'nin dorsalinden geçen bir referans çizgi çizildi. Ayrıca atlasın (C1) anterior ve posterior arklarını birleştiren ve C3'ün bazalinden geçen iki ayrı çizgi daha çizildi. C1 ark çizgisiyle olan açı α , C3 çizgisiyle olan açı β olarak adlandırıldı.

Bulgular: Airtraq® grubunda entübasyon süresi anlamlı olarak daha uzundu. Entübasyon sırasında ölçülen β açısındaki değişimin ortalaması açısından istatistiksel olarak sınırda bir fark bulunmasına karşın ($P = 0,054$), grup içi değişim gruplar arasında benzerdi ($P = 0,4$).

Sonuç: Sonuç olarak biz Airtraq®'ı servikal vertebra hasarı olan hastalarda entübasyonda direkt laringoskopiye alternatif olarak önermiyoruz.

Anahtar sözcükler: Entübasyon, laringoskop, servikal vertebra

Received: 12.01.2009 – Accepted: 10.12.2009

¹ Department of Anesthesiology and Reanimation, Faculty of Medicine, Hacettepe University, Ankara - TURKEY

² Department of Radiology, Faculty of Medicine, Hacettepe University, Ankara - TURKEY

Correspondence: İ. Aydın ERDEN, Department of Anesthesiology and Reanimation, Faculty of Medicine, Hacettepe University, Ankara - TURKEY

E-mail: aerden@hacettepe.edu.tr

Introduction

For any patient in whom spine movement is of concern, e.g. in patients sustaining blunt injuries to the head, face, or neck, the method of intubation is of great importance. Cervical spine injuries occur in up to 6% of all major trauma cases (1). Even a normal movement of the vertebrae in an unstable spine may cause neurological deficits (2). Several techniques have been proposed as an intubation method in these patients to minimize cervical spine movement (3-5).

In the normal patient, direct laryngoscopy with Macintosh blade remains the most popular device used to facilitate orotracheal intubation and constitutes the gold standard (6). However, many anesthesiologists are reluctant to use this method in cervical trauma patients because of the potential for neurological injury (3).

Airtraq® (Prodol Meditec S.A., Vizcaya, Spain) is a new, disposable airway device designed to facilitate tracheal intubation in patients both with normal or difficult airways. As a result of an exaggerated blade curvature, an internal arrangement of optical lenses and a mechanism to prevent fogging of the distal lens, a high quality view of the glottis is provided without the need to align the oral, pharyngeal, and tracheal axes. It is an anatomically shaped laryngoscope with 2 side-by-side channels. The optical channel contains a series of lenses, prisms, and mirrors that transfer the image from the illuminated tip to a proximal viewfinder, giving a high quality wide-angle view of the glottis and surrounding structures. The guiding channel acts as a conduit through which a tracheal tube (ETT) can be passed through the vocal cords. A clip-on wireless video system is also available (7). During intubation, minimal extension of the neck seems to be required. Airtraq® may have advantages compared with the Macintosh laryngoscope in simulated difficult intubation scenarios, including reduced cervical spine mobility, in the manikin (8) and when used by both inexperienced (9) and novice (10) users. However, the utility of the Airtraq® in patients with cervical spine injuries remains to be determined.

The aim of this study was to compare 2 endotracheal intubation techniques, namely direct laryngoscopy and Airtraq®, according to their influence on cervical spine movement and intubation time and success rates, complications, and hemodynamic responses.

Materials and methods

Patients and anesthetic management

After obtaining institutional Ethics Committee approval, 33 ASA I and II adult patients (≥ 18 years old) without cervical spine problems or known or suspected difficult airways and scheduled for elective interventional radiology procedures, requiring anesthesia and tracheal intubation, were randomly allocated by a random numbers table into 2 groups: Group D: 16 patients-intubation by direct laryngoscopy; and Group A: 17 patients-intubation by Airtraq®. The hyomental distances and the modified Mallampati test (11) were noted preoperatively. The following data were also collected: age, height, gender, ASA score, intubation time, and airway complications. Assessment of airway complications was made as described by Bilgin and colleagues (12): lip or dental injury, mucosal injury (blood detected on airway device), desaturation ($SpO_2 < 94\%$ for more than 10 s). Exclusion criteria included underlying cervical spine pathology and need for either a rapid sequence induction or an awake intubation. Intubations were performed by the same experienced with direct laryngoscopy and Airtraq® anesthesiologist.

Written informed consent was obtained from all patients before intervention. Each patient was monitored with 3-lead electrocardiograph (ECG), blood pressure and pulse oximetry (Siemens SC 7000; Siemens Medical Systems, Danvers, MA, USA), and capnography (Draeger Primus, Draeger, Germany). The data were recorded before and 0, 2, 4, 6, 8 and 10 min after intubation. After pre-oxygenation, general anesthesia was induced with propofol 2.5 mg kg⁻¹, fentanyl 1 μ g kg⁻¹, and vecuronium bromide 0.1 mg kg⁻¹.

Intubation procedures and measurements

After induction of anesthesia, lateral arm of a bi-plane fluoroscopy device (Axiom Artis bi-plane, Siemens Medical Systems) was set to show the lateral view of the cervical spine with the head in the neutral position in order to record the cervical spine movement. During intubation, cricoid pressure and stabilization of the head and neck were not applied in either group.

In group D, direct laryngoscopy was performed using a conventional laryngoscope with a Macintosh 3 blade (Welch Allyn, USA) in 16 patients. Endotracheal tube (ETT) size was 8.5-9 mm internal diameter in males and 7-7.5 mm in female patients. After obtaining the best possible view of the larynx for tracheal intubation, the anesthetist graded it according to the Cormack and Lehane grading system in both groups (13).

In group A, 17 patients were included. Intubation was performed using a regular size (number 3, blue color) Airtraq® in all patients. Endotracheal tube size was 7-7.5 mm internal diameter in females and 8.5-9 mm in male patients. According to the manufacturer's instructions, intubation was performed with Airtraq® as follows: After turning the light on, eligible ETT size was selected, lubricated, and placed into the Airtraq's guiding channel. Then the Airtraq® was inserted into the midline of the patient's mouth and slid through the oropharynx and larynx, keeping it in the midline. Anesthesiologist looked through the eyepiece, advanced until epiglottis was identified, placed the tip of the Airtraq® at the vallecula, and lifted up the Airtraq® to expose the vocal cords. ETT was advanced down the lateral channel until it passed through the vocal cords. After inflating the cuff, ETT was connected to the breathing circuit and

separated from the Airtraq® by pulling it laterally and then backwards. Failed tracheal intubation was defined as more than 2 intubation attempts.

Assessment of movement of the cervical spine was made by the technique described by Walzl and colleagues (14): 3 lateral cervical spine X-rays were taken. The first radiograph was taken with the head and cervical spine in the neutral position, before any manipulation was performed (Figure 1). The greatest excursion of the cervical spine in both groups was when the best possible view of the larynx was obtained (Figures 2 and 3). Finally, after intubation, the end-position of the head and cervical spine was demonstrated by a 3rd radiograph. Intubation time was defined as the time from the passage of the tip of the intubation device through the lips of the patient to the time the tracheal cuff was inflated.

A reference line was drawn following the dorsal alignment of C2. Two more lines were drawn, one connecting the anterior and posterior arch of the atlas (C1) and the second through the basal plate of C3. The angle with the C1 arch line was called α and with the C3 line was called β . This method is completely independent of any changes of the X-ray tube position and enables direct comparison of angles between positions, since no relative reference line depending, for example, on the

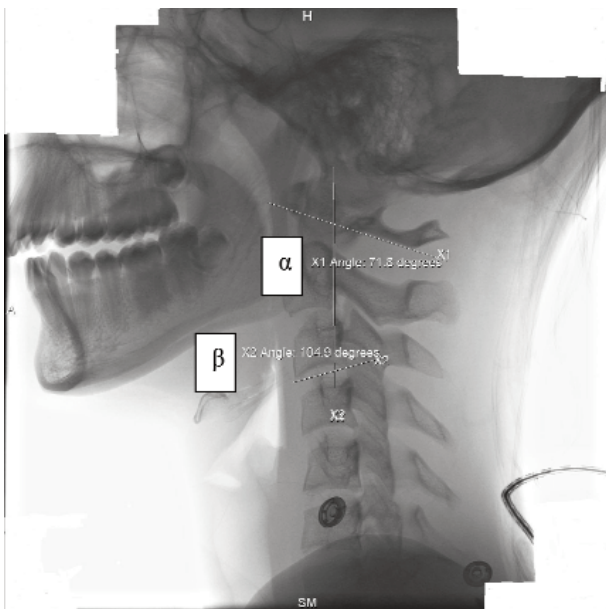


Figure 1. Lateral cervical spine radiograph: reference lines and the angles in the neutral position before intubation.

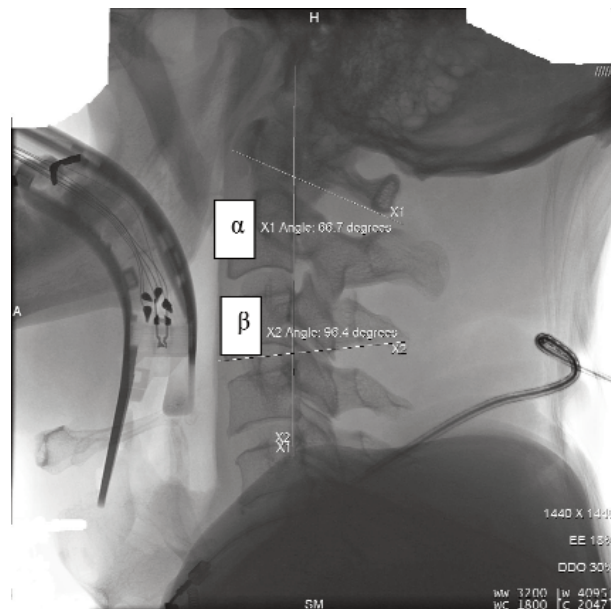


Figure 2. Lateral cervical spine radiograph: maximum cervical spine extension during intubation via the Airtraq®.

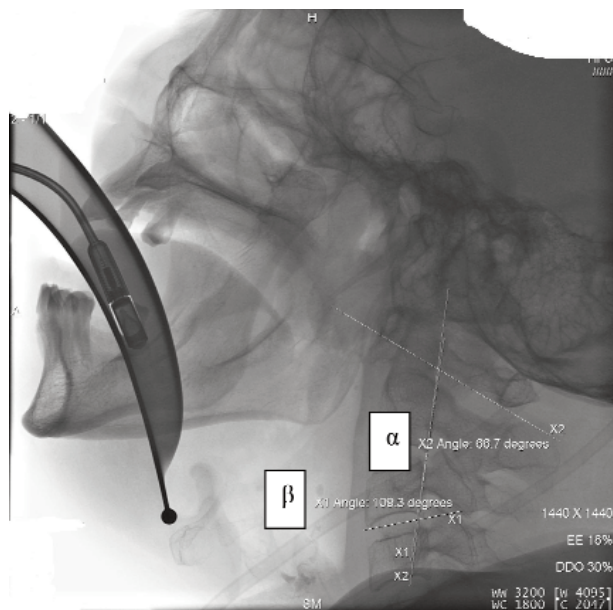


Figure 3. Lateral cervical spine radiograph: Lateral cervical spine radiograph: maximum cervical spine extension during intubation via the direct laryngoscopy.

image field, is involved (14). The radiographs were analyzed in a random order by a radiologist who was unaware of the purpose of the study.

Statistical evaluation

Using the data from Sahin et al. (15) ($10.2 \pm 7.3^\circ$ movement at cervical spine), the sample size was calculated to be 16 patients for each group ($P = 0.05$; power = 0.80). Statistical analysis was carried out using SPSS 11.5 (SPSS Inc., Chicago, IL). The one-sample Kolmogorov-Smirnov test was used for determining whether the data were normally distributed. For parametric variables, t-test on 2 independent samples was used to compare 2 groups. For non-parametric variables, the Mann-Whitney-U-test and chi-square test were used to compare 2 groups where appropriate. Blood pressure and heart rate values were analyzed using repeated measures ANOVA. Unless noted otherwise, data were presented as mean with standard deviation (SD). The results were assumed to be significant at a P-value <0.05.

Results

The groups were similar with respect to age, weight, gender, hyomental distance, Cormack Lehane, Mallampati values, and ASA physical status (Table 1). The duration of intubation was significantly longer in

group A (Table 2). The cervical angles of the patients before, during, and after intubation are shown in Table 2. Although, there was a statistically borderline significant difference between groups during intubation at the mean change of β angle (Table 3), within group differences were similar in the 2 groups ($P = 0.4$). Oxygen saturation, arterial blood pressure, heart rate, and end-tidal CO₂ remained stable in both groups. Although, compared with the baseline, both groups showed increased blood pressure and heart rate during intubation, this was not statistically significant.

Although mucosal injury was more frequent in Airtraq®, lip and dental injury was observed more frequently in the direct laryngoscopy group. In group A, one patient could not be intubated despite adequate manipulation. In this patient, all 3 attempts resulted in esophageal intubation but thereafter the trachea was intubated successfully with the direct laryngoscope and it was excluded from angle measurements. The remainders of the patients in both groups were

Table 1. Patient data expressed as mean \pm SD.

	Direct laryngoscopy	Airtraq®
Age (yr)	51.6 \pm 15	42.3 \pm 13.1
Weight (kg)	70.5 \pm 10.4	69.2 \pm 12.1
Gender (male/female)	6/10	7/9
Hyomental distance (cm)	5 \pm 0.7	5.5 \pm 0.7
ASA (I/II)	4/12	9/7
Cormack Lehane, 1,2,3,4; n	9/4/3/0	11/4/1/0
Mallampati score, 1,2,3,4; n	6/7/3/0	8/6/2/0

Table 2. Duration of intubation (in seconds) and cervical angles (mean \pm SD) (in degrees) before, during, and after intubation.

	Direct laryngoscopy	Airtraq®
Duration of intubation	31.5 \pm 7.8	45.4 \pm 8.7*
C1/C2 baseline	74.1 \pm 5.1	71.2 \pm 5.6
C1/C2 intubation	65.2 \pm 5.4	63.7 \pm 3.9
C1/C2 post-intubation	69.2 \pm 5.2	67.9 \pm 5.5
C2/C3 baseline	102.8 \pm 6.2	99.3 \pm 3.8
C2/C3 intubation	104.9 \pm 8.0	98.5 \pm 2.6†
C2/C3 post-intubation	102.6 \pm 5.5	100.1 \pm 3.0

* Significantly different from direct laryngoscopy group ($P = 0.01$)

† Significantly different from direct laryngoscopy group ($P = 0.007$)

Table 3. Absolute changes in cervical angles during intubation. Difference between absolute values of baseline and intubation measurements in degrees, mean ± SD.

Angle	Direct laryngoscopy	Airtraq®	P
C1/C2 (range)	8.9 ± 5.1 (2.6, 19.4)	7.4 ± 4.1 (0.4, 16.9)	0.61
C2/C3 (range)	4.6 ± 2.7 (0.2, 9.8)	2.8 ± 2.5 (0.2, 8.3)	0.054

intubated at the first attempt. Desaturation was observed in one patient in group D (Table 4).

Discussion

The main finding of our study is that there is no statistically significant difference at the cervical spine movement during intubation using the Airtraq® and direct laryngoscopy.

Extreme cervical vertebral movement might be hazardous during intubation. The importance of clinically significant movement was stressed by Lennarson and colleagues as opposed to statistically significant movement (16). As yet, the ideal technique for emergency or elective endotracheal intubation in a patient with cervical injury remains the subject of debate. Fiberoptic intubation can be the preferred technique, but it may not be available many ambulances and emergency rooms and it also needs an experienced user. There have been several reports of neurological deficits in patients with unstable spines after intubation (17,18). Panjabi and colleagues stated that a rotation of over 20° in the sagittal plane exceeds the upper limits of the physiological motion

(19). The maximum cervical motion in our study was observed in the direct laryngoscopy group who had a 19.4° change in α angle during intubation, i.e. close to the instability limits defined by Panjabi and colleagues. The maximum cervical motion with Airtraq® (16.9°) is similar to laryngeal mask airway (16.7°) but still higher than fiberoptic (8.1°) (15).

Previous studies have shown that the greatest cervical movement takes place in the upper cervical vertebrae during intubation (3,20). Thus we decided to evaluate the excursion movement of C1/C2 and C2/C3 vertebrae during intubation using 2 different techniques. It was decided not to carry out dynamic recording of spine motion under fluoroscopy in order to reduce the patients’ exposure to radiation. A shortcoming of this study is the lack of measurement of atlantooccipital movement, which has been shown to be prominent by Lennarson and colleagues (20).

The duration of intubations in our study with the direct laryngoscopy and Airtraq® are longer than Maharaj and colleagues study (7). This might be due to the radiological examination in our study during intubation. Moreover, the duration of intubation in the direct laryngoscopy in our study was shorter than the Airtraq® group. The reason for the difference might be that we are more experienced with direct laryngoscopy. In our study, lip and dental injury with Airtraq® is less than direct laryngoscopy, which is similar with the study performed by Maharaj and colleagues (9). However, mucosal injury was observed more frequently in Airtraq®, which is also in accordance with Ndoko’s study (21).

Maharaj et al. (9) showed in their study that Airtraq® resulted in less stimulation of heart rate following tracheal intubation in comparison with the Macintosh laryngoscope. In contrast to their study, we did not find any statistical difference at the hemodynamic findings. Our results reflect that both techniques require same force to be applied, which is observed through angular changes during intubation.

One important difficulty with Airtraq® was that the tube may pass posterior as it leaves its guide, and further manipulation of the handle of the Airtraq® may be needed to allow the endotracheal tube to be successfully passed through the vocal cords. This was the reason why we could not intubate one patient with Airtraq®.

Table 4. Airway complications. Data are reported as numbers (percent).

Complications	Direct laryngoscopy (n = 16)	Airtraq® (n = 16)
Airway complications:		
Mucosal injury; n	1 (6.2%)	3 (18.7%)
Lip and dental injury; n	2 (12.4%)	1 (6.2%)
Desaturation; n	1 (6.2%)	0 (0%)
Esophageal intubation; n	0 (0%)	1 (6.2%)

The major limitation was conducting the study on cervically stable patients in an operating room under ideal conditions. Although the aim of this study was to compare these methods with regard to their effect on cervical vertebral movement, it would not be ethical to perform a clinical study in patients with cervical instability. However, Sawin et al. (3) showed that relaxation of the muscles may reduce the motion of the cervical spine during laryngoscopy. Furthermore, there were also certain limitations to our protocol as the person performing the intubation could not be blinded to the type of laryngoscope in use. However, these problems are inherent in studies of this nature.

In conclusion, although the Airtraq® laryngoscope offers a new approach for the intubation in patients with cervical spine injury, we do not recommend the Airtraq® as an alternative to direct laryngoscopy in cervical spine injuries.

Acknowledgement

The authors would like to thank Fatih Erdal, Nuri Cavlı, and Fevziye Bilasa for keeping records and Atilla Topaloğlu, Halil Uğurlu, and Mevlut Çoban for using the fluoroscopy machine.

References

1. Ajani AE, Cooper DJ, Scheinkestel CD, Laidlaw J, Tuxen DV. Optimal assessment of cervical spine trauma in critically ill patients: a prospective evaluation. *Anaesth Intensive Care* 1998; 26: 487-491.
2. Hastings RH, Marks JD. Airway management for trauma patients with potential cervical spine injuries. *Anesth Analg* 1991; 73: 471-482.
3. Sawin PD, Todd MM, Traynelis VC, Farrell SB, Nader A, Sato Y et al. Cervical spine motion with direct laryngoscopy and orotracheal intubation. An in vivo cinefluoroscopic study of subjects without cervical abnormality. *Anesthesiology* 1996; 85: 26-36.
4. Hastings RH, Vigil AC, Hanna R, Yang BY, Sartoris DJ. Cervical spine movement during laryngoscopy with Bullard, Macintosh, and Miller Laryngoscopes. *Anesthesiology* 1995; 82: 859-869.
5. Wood PR, Lawler PG. Managing the airway in cervical spine injury. A review of the Advanced Trauma Life Support protocol. *Anaesthesia* 1992; 47: 792-797.
6. Macintosh RR. A new laryngoscope. *Lancet* 1943; i: 205.
7. Maharaj CH, O'Croinin D, Curley G, Harte BH, Laffey JG. A comparison of tracheal intubation using the Airtraq® or the Macintosh laryngoscope in routine airway management: a randomized, clinical trial. *Anaesthesia* 2006; 61: 1093-1099.
8. Maharaj CH, Higgins B, Harte BH, Laffey JG. Evaluation of intubation using Airtraq® or Macintosh laryngoscope by anaesthetists in easy and simulated difficult laryngoscopy: A manikin study. *Anaesthesia* 2006; 61: 469-77.
9. Maharaj CH, Chonghaile MN, Higgins BD, Harte BH, Laffey JG. Tracheal intubation by inexperienced medical residents using the Airtraq and Macintosh laryngoscopes—a manikin study. *Am J Emerg Med* 2006; 24: 769-774.
10. Maharaj CH, Costello J, Higgins B, Harte BH, Laffey JG. Learning and performance of tracheal intubation by novice personnel: A comparison of the Airtraq® and Macintosh laryngoscope. *Anaesthesia* 2006; 61: 671-7.
11. Samsoun GL, Young JR. Difficult tracheal intubation: a retrospective study. *Anaesthesia* 1987; 42: 487-490.
12. Bilgin H, Bozkurt M. Tracheal intubation using the ILMA, C-Trach™ or McCoy laryngoscope in patients with simulated cervical spine injury. *Anaesthesia* 2006; 61: 685-691.
13. Cormack RS, Lehane J. Difficult tracheal intubation in obstetrics. *Anaesthesia* 1984; 39: 1105-11.
14. Waltl B, Melischek M, Schuschnig C, Kabon B, Erlacher W, Nasel C, et al. Tracheal intubation and cervical spine excursion: direct laryngoscopy vs. intubating laryngeal mask. *Anaesthesia* 2001; 56: 221-226.
15. Sahin A, Salman MA, Erden IA, Aypar U. Upper cervical vertebrae movement during intubating laryngeal mask, fiberoptic and direct laryngoscopy: a video-fluoroscopic study. *Eur J Anaesthesiol* 2004; 21: 819-823.
16. Lennarson PJ, Smith DW, Sawin PD, Todd MM, Sato Y, Traynelis VC. Cervical spine motion during intubation: efficacy of stabilization maneuvers in the setting of complete segmental instability. *J Neurosurg (Spine 2)* 2001; 94: 265-270.
17. Talucci RC, Shaikh KA, Schwab CW. Rapid sequence induction with oral endotracheal intubation in the multiply injured patient. *Am Surg* 1988; 54: 185-187.
18. Wright SW, Robinson GG, Wright MB. Cervical spine injuries in blunt trauma patients requiring emergent endotracheal intubation. *Am J Emerg Med* 1992; 10: 104-109.
19. Panjabi MM, Thibodeau LL, Crisco JJ 3rd, White AA 3rd. What constitutes spinal instability? *Clin Neurosurg* 1988; 34: 313-339.
20. Lennarson PJ, Smith D, Todd MM, Carras D, Sawin PD, Brayton J, et al. Segmental cervical spine motion during orotracheal intubation of the intact and injured spine with and without external stabilization. *J Neurosurg (Spine 2)* 2000; 92: 201-206.
21. Ndoko SK, Amathieu R, Tual L, Polliand C, Kamoun W, El Housseini L, et al. Tracheal intubation of morbidly obese patients: a randomized trial comparing performance of Macintosh and Airtraq™ laryngoscopes. *Br J Anaesth* 2008; 100 (2): 263-8.