

Insertions of the lateral pterygoid muscle to the disc-capsule complex of the temporomandibular joint and condyle

Cenk KILIÇ¹, Gühan DERGİN², Fatih YAZAR¹, Bülent KURT³, Tunç KUTOĞLU⁴,
Hasan OZAN¹, Hüseyin Avni BALCIOĞLU⁵

Aim: To investigate the disc-capsule complex and condyle attachments of the lateral pterygoid muscle and its variations.

Materials and methods: Forty-nine temporomandibular joint (TMJ) specimens were used, obtained from 26 human cadavers. The insertion point of each muscle head was determined. The widths and lengths of the heads were measured.

Results: In 32 specimens, 2-headed muscles were present, while 3 heads were observed in 17 specimens. We defined 4 different types of attachments of muscle heads. In the most common type of attachment, the upper head inserted into the disc-capsule complex and condyle, and the lower head inserted into the condyle (36.7%). In the second type, the upper head inserted into the disc-capsule complex and the lower head inserted into the condyle. In the third type, both heads inserted into the condyle. In the fourth type, the upper head inserted into the disc-capsule complex and the lower head inserted into the complex and condyle.

Conclusion: Detailed knowledge of the morphology of the lateral pterygoid muscle will provide great benefit in addressing temporomandibular joint problems. The results of the present study will be helpful for further clinical, radiological, and anatomical research.

Key words: Temporomandibular joint, pterygoid muscles, temporomandibular joint disc, mandibular condyle

Lateral pterigoid kasın temporomandibuler eklemin disk-kapsül kompleksine ve kondile tutunmaları

Amaç: Bu diseksiyon çalışmasının amacı lateral pterigoid kasın disk-kapsül kompleksine ve kondile tutunmalarını ve kasın varyasyonlarını araştırmaktır.

Yöntem ve gereç: 49 temporomandibular eklem örneğini içeren 26 insan kadavrası kullanıldı. Her bir kas başının sonlanma yerleri belirlendi. Başların genişlikleri ve uzunlukları ölçüldü.

Bulgular: 32 örnekte kaslar iki başa sahipti. Diğer 17 örnekte üç baş gözlemlendi. Kasın başlarının tutunmaları için 4 farklı tip tanımladık. Kasın en sık görülen tutunma tipinde üst baş disk-kapsül kompleksinde ve kondilde, alt baş kondilde sonlanıyordu (% 36,7). İkinci tipte üst baş komplekste, alt baş kondilde sonlanıyordu. Üçüncü tipte iki baş da kondilde sonlanıyordu. Dördüncü tipte üst baş komplekste, alt baş komplekste ve kondilde sonlanıyordu.

Sonuç: Bu kasın morfolojisi hakkında bilgi sahibi olmak temporomandibular eklem problemlerini belirlemede büyük fayda sağlayacaktır. Bu çalışmanın bulguları gelecekteki klinik, radyolojik ve anatomik araştırmalar için yararlı olacaktır.

Anahtar sözcükler: Temporomandibular eklem, pterigoid kaslar, temporomandibular eklem diski, mandibular kondil

Received: 07.08.2008 – Accepted: 09.12.2009

¹ Department of Anatomy, Faculty of Medicine, Gülhane Military Medical Academy, Ankara - TURKEY

² Department of Oral and Maxillofacial Surgery, Faculty of Dentistry, Marmara University, Istanbul - TURKEY

³ Department of Pathology, Faculty of Medicine, Gülhane Military Medical Academy, Ankara - TURKEY

⁴ Department of Anatomy, Faculty of Medicine, Trakya University, Edirne - TURKEY

⁵ Department of Anatomy, Faculty of Dentistry, Istanbul University, Istanbul - TURKEY

Correspondence: Cenk KILIÇ, Department of Anatomy, Faculty of Medicine, Gülhane Military Medical Academy (GATA), 06018 Etlik-Ankara - TURKEY

E-mail: ckilicmd@yahoo.com

Introduction

The lateral pterygoid muscle (LPM) plays a principal function in the movement of the mandible. The LPM arises from 2 muscle heads, 1 superior (upper) and 1 inferior (lower). The upper head originates from the infratemporal surface and the infratemporal crest of the greater wing of the sphenoid bone, and the lower head originates from the lateral surface of the lateral pterygoid plate. The upper head is inserted into the disc-capsule complex (DCC). The lower head is attached to the condyle (1-3). The LPM is innervated by the lateral and medial pterygoid nerves (3,4). Morphological studies of the LPM and the temporomandibular joint (TMJ) have been performed using various techniques. Nevertheless, the anatomy of the TMJ and its relationship to the LPM remains poorly described. In addition, the causes of disc displacement have not yet been fully identified. The LPM contributes to the apposition of the disc and condyle.

Furthermore, the LPM is important in the closing of the jaw. The function of the upper head in influencing rotation and translation of the disc and condyle and the relationship with inner irregularity and temporomandibular function deficiency has been considered (5). The purpose of this study was to determine, via anatomical study, the DCC and condyle attachments of the LPM and their variations.

Methods

Forty-nine TMJ specimens (23 paired, in addition to 2 right and 1 left) obtained from 26 human cadavers (16 male and 10 female) were studied under a dissecting microscope to determine the DCC and condyle attachments of the LPM. The median age was 54 years (range: 23-76 years). During the dissection, the skin, the superficial fascia, the parotid gland, the temporal and masseter muscles, the posterior half of the zygomatic bone, the zygomatic arch, and the coronoid process of the mandible were removed. This approach allowed free access to the LPM.

Each head of the muscles and their attachments were determined, and the specimens were photographed. All specimens were examined for muscular atrophy, and those in which it was present were excluded from the study. The following measurements were made on the muscles using a

calliper (Ningbo Everest Imp. & Exp. Co., Zhejiang, China; accuracy = 0.01 mm). For each head of the LPM, the widths of the muscle fibres were measured from the midpoint between its origin and insertion. The lengths of the heads were also measured from their anterior-most fibres at their origin in the infratemporal crest to their posterior lateral insertion points. Data acquisition followed an identical protocol for all specimens, with the same person taking all measurements on all muscles. Data were analysed with SPSS 15.0 software (SPSSFW, SPSS Inc., Chicago, IL, USA). Descriptives of the parameters were given with the mean \pm SD notation. Findings according to gender and sides were compared with a test of significance of difference between pairs. Relationships among the parameters were investigated by calculating the Pearson coefficient of correlation. $\alpha = 0.05$ was selected as the confidence level. U-values less than or equal to P-values were evaluated as significantly different.

One of the specimens with 3 heads was examined microscopically. The muscle was removed en bloc from the cadaver and further fixed in a 10% formalin solution for 10 days. Serial sections were cut at 3 mm intervals in the middle of the muscle and were then embedded in paraffin wax. The serial sections (8 μ m) were prepared using a Reichert Ultracut E microtome (Reichert, Wien, Austria) and mounted on poly-L-lysine coated slides. Care was taken to orient the muscle fibres of the LPM heads perpendicularly to the anticipated coronal plane of sectioning.

Results

In 32 specimens, an upper and a lower head of the LPM were present, whereas the remaining 17 specimens were observed to have 3 heads (Figure 1). The inner head of the LPM was also shown in a histological section (Figure 2). The inner heads originated on the surface of the greater wing of the sphenoid bone and were sometimes difficult to differentiate from the origin of other heads. We found that all inner heads coursed together with fibres from upper heads.

The LPM attachment points were categorised into 4 different types. In Type 1 (36.7% of cases, 18 sides), the upper head inserted into the DCC and condyle,

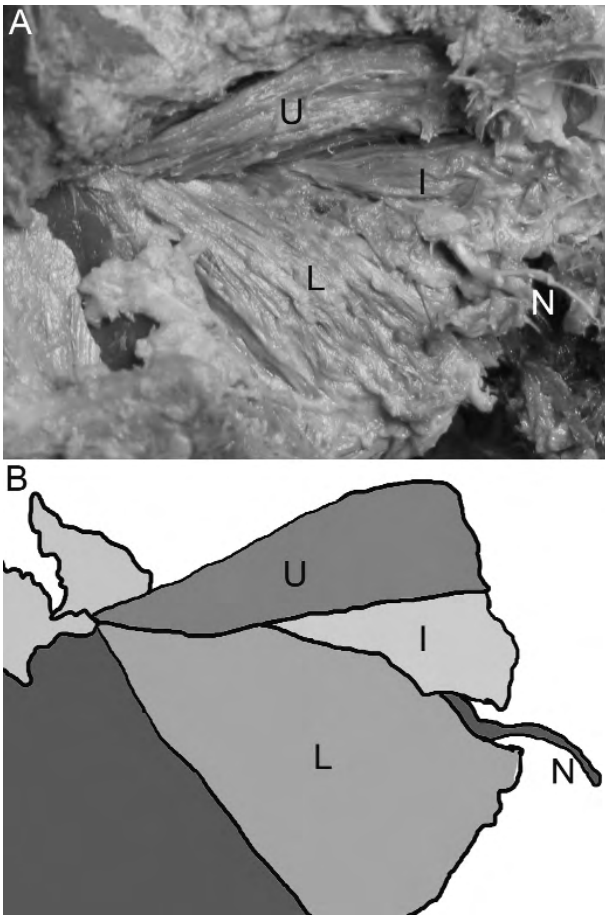


Figure 1. A: A dissection of the LPM on the right side. B: Schematic drawing of the dissection showing the upper head (U), the inner head (I), the lower head (L), and the buccal nerve (N).

and the lower head inserted into the condyle (Figure 3). In Type 2 (28.6% of cases, 14 sides), the upper head inserted into the DCC and the lower head inserted into the condyle (Figure 4). In Type 3 (26.5% of cases, 13 sides), the upper and lower heads inserted into the condyle (Figure 5). In Type 4 (8.2% of cases, 4 sides), the upper head inserted into the DCC and the lower head inserted into the DCC and condyle (Figure 6). In 45 specimens, the lower head linked only to the condyle. Muscular atrophy was seen in 10 specimens (20.41%). Table 1 presents the widths and lengths of the heads according to gender and side groups. The mean widths of the upper, lower, and inner parts of the LPM were found to measure 15.19 ± 2.7 mm, 8.42 ± 1.4 mm, and 6.05 ± 1.6 mm, respectively. The mean

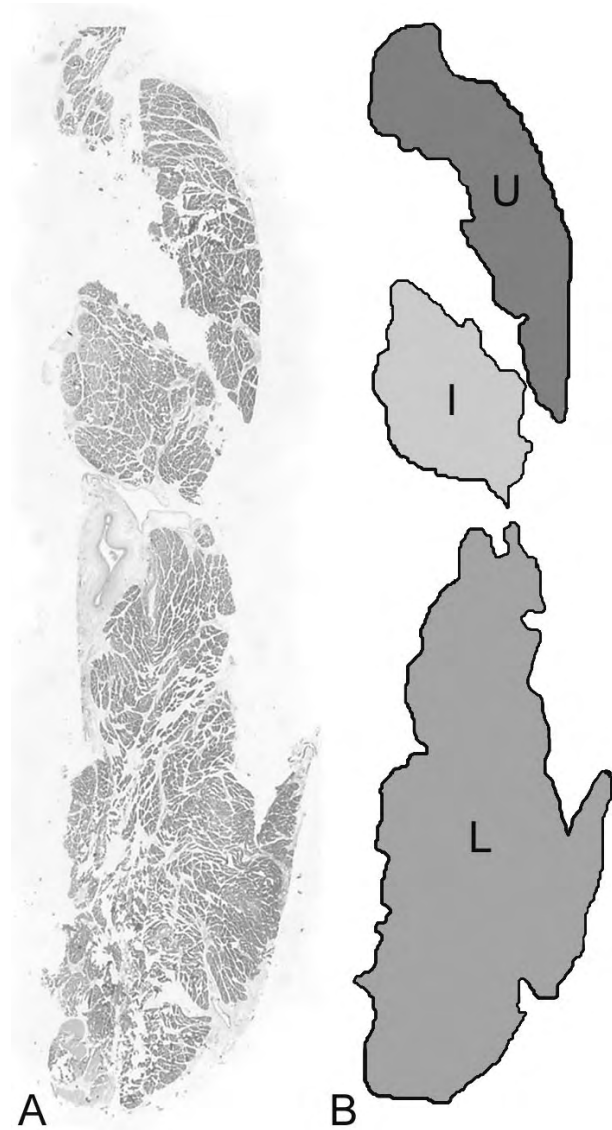


Figure 2. A: A histological section of the LPM on the right side. Original magnification $\times 1$. B: Schematic drawing of the histological section showing the upper head (U), the inner head (I), and the lower head (L).

lengths of the upper, lower, and inner parts of LPM were found to measure 32.91 ± 2.4 mm, 33.41 ± 2.5 mm, and 23.25 ± 2.3 mm, respectively. The mean LPM lengths of males were longer than those of females; however, no significant statistical difference was found between the groups based on gender ($t = -1.380$, $P = 0.189$). No statistically significant difference was observed between the left and right sides ($t = 0.564$, $P = 0.581$).

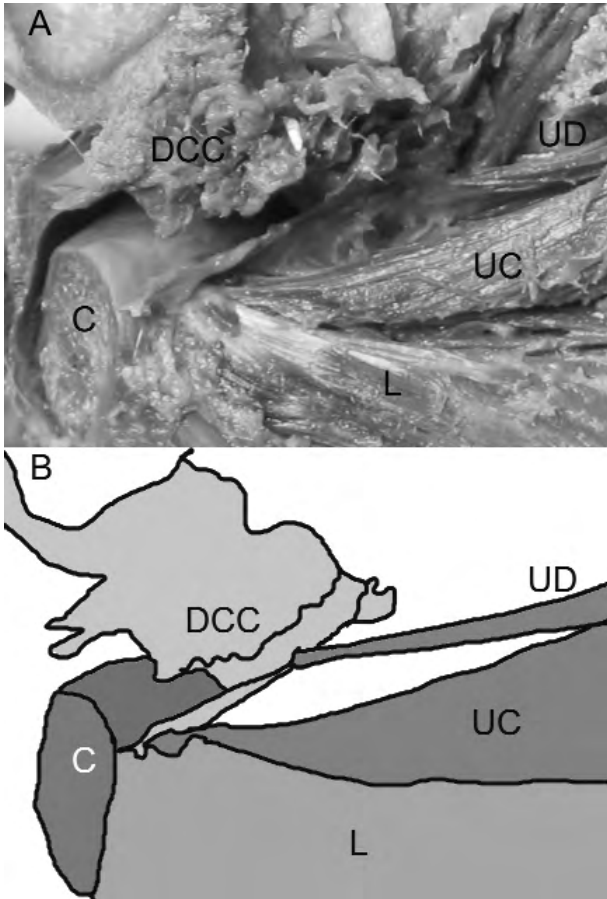


Figure 3. A: A dissection of the LPM on the right side. B: Schematic drawing of the dissection showing fibres inserted into the condyle of the upper head (UC), fibres inserted into the DCC of the upper head (UD), the lower head (L), the disc-capsule complex (DCC), and the condyle (C).

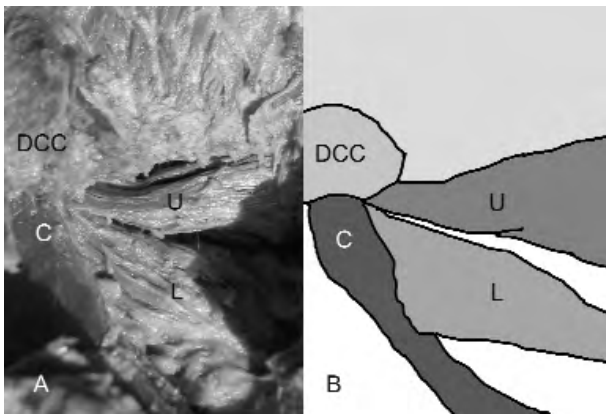


Figure 4. A: A dissection of the LPM on the right side. B: Schematic drawing of the dissection showing the upper head (U), the lower head (L), the disc-capsule complex (DCC), and the condyle (C).

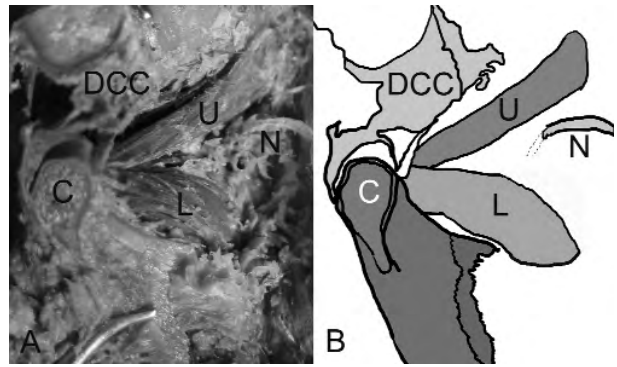


Figure 5. A: A dissection of the LPM on the right side. B: Schematic drawing of the dissection showing the upper head (U), the lower head (L), the disc-capsule complex (DCC), the condyle (C), and the buccal nerve (N).

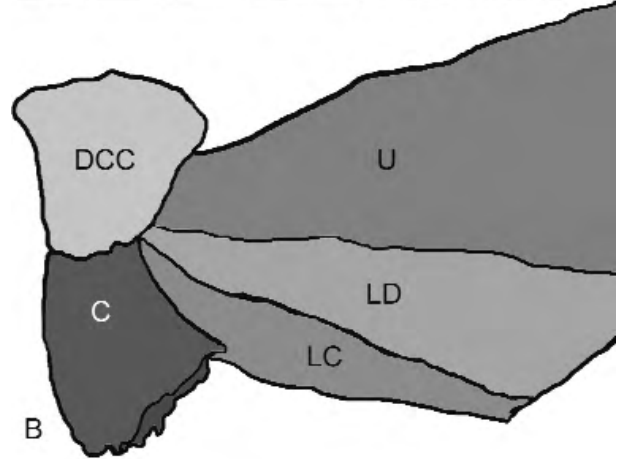
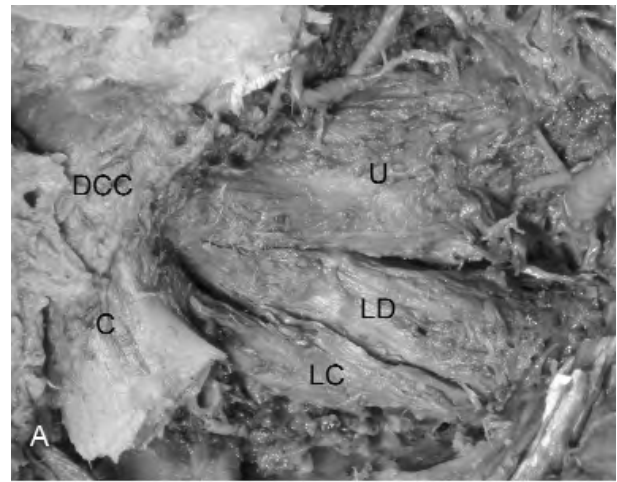


Figure 6. A: A dissection of the LPM on the right side. B: Schematic drawing of the dissection showing the upper head (U), fibres inserted into the condyle of the lower head (LC), fibres inserted into the DCC of the lower head (LD), the disc-capsule complex (DCC), and the condyle (C).

Table 1. Mean widths and lengths (mm) of LPMs' upper, lower, and inner heads according to gender and side. Standard deviation not presented.

	Upper head			Lower head			Inner head		
	n	width	length	n	width	length	n	width	length
Male left	13	15.31	32.94	13	8.58	33.51	4	6.26	23.26
Male right	13	15.32	33.06	13	8.46	33.55	5	6.24	23.40
Female left	6	14.96	32.81	6	8.24	33.23	4	5.75	23.18
Female right	7	15.03	32.73	7	8.28	33.21	3	5.80	23.07
Both left	19	15.18	32.89	19	8.45	33.40	8	6.04	23.22
Both right	20	15.20	32.93	20	8.39	33.42	8	6.08	23.28
All male	26	15.32	33.00	26	8.52	33.53	9	6.25	23.33
All female	13	15.00	32.77	13	8.26	33.22	7	5.77	23.13
Total	39	15.19	32.91	39	8.42	33.41	16	6.05	23.25

Discussion

The majority of researchers and textbooks indicate that the LPM is a 2-headed muscle (2,3,6-13). However, this differs from the few articles stating that it is 1-headed (14-16) and from many previous studies that have indicated that it is 3-headed (13-15,17-19). In our research, we mostly observed 2-headed cases, while cases with 3 heads were less common. Naohara (14) and Abe et al. (15) found that rates of 3 heads (upper, lower, and inner) were 20% and 6.33%, respectively. The rate of 3-headed LPMs recorded in our study is higher than the rates observed by these authors. Fujita et al. (13) reported that the rate of 3-headed LPMs was 35%, which is in close accordance with our results showing that 34.69% of cases were 3-headed.

With regard to the rate of 2-headed muscles, our data (65.31%) closely agree with the findings of Naohara, 65% (14); Abe et al., 67.09% (15); and Fujita et al., 65% (13). Naohara (14) and Abe et al. (15) found that rates of 1-headed muscles were 15% and 26.58%, respectively, while neither Fujita et al. (13) nor our own study found a specimen with 1 head.

The LPM inserts at the condyle and DCC and plays a central role in mandibular movement via the TMJ (20). The majority of the upper heads insert into the condyle, and the contraction of the smaller part of the upper head, which inserts into the DCC, should

not result in anterior disc displacement (2,5,14,16,21-24).

Many authors have previously identified the insertion points of the LPM (2,3,5-8,10-14,16,21-27). Most studies have reported that the lower head was connected to the condyle, but they have been in disagreement about the engagement of the upper head. Some researchers have reported that the upper head was inserted into the DCC and condyle, while the lower head was attached to the condyle (8,13,25), which conforms to our Type 1 classification. Several investigators have reported that the upper head was inserted into the DCC and the lower head was attached to the condyle (2,6-8), which is in accordance with our Type 2 classification. We found that LPM attachments presented 4 different types, described differently by several authors (5,10,13,14,27). The observations of these researchers were classified according to our types of configuration and compared with the frequency of LPM attachment types in Table 2. Naohara (14) and Fujita et al. (13) described the frequency of Type 4, but not the other types described in our study.

The present study confirms that the LPM has a variable attachment pattern to the condyle or the DCC. The role of this muscle in the displacement of the articular disc is still unknown and further research into temporomandibular disorders should involve the

Table 2. Comparison of frequencies of LPM attachment types.

	Naidoo	Zhang et al.	Naohara et al.	Fujita et al.	Taskaya-Yilmaz et al.	Present study
Type 1	65%	52%	-	-	33.1% 3	6.7%
Type 2	7.5%	48%	-	-	66.9%	28.6%
Type 3	27.5%	-	-	-	-	26.5%
Type 4	-	-	10%	10%	-	8.2%

investigation of other structures in the craniomandibular complex.

Van Eijden et al. (9) and Naidoo and Juniper (11) claimed that the median length of the upper head of the LPM was 31.3 mm and 33.3 mm, respectively. The results of our study support the observations of these authors (9,11). Honée (28) determined this length to be 40 mm, which is higher than in our observations.

Although TMJ problems are most clearly identified by the help of MRI radiological evaluation, some detailed morphologies and variations such as inner heads and microstructural attachments can be determined by cadaver dissections and histological sections.

Hyperactive LPM contraction is a major problem of TMJ disorders. One of the recent treatments for severe clicking of the TMJ associated with anterior

disc displacement is the use of botulinum toxin injections in the LPM (29,30). The present study may be useful for the application of botulinum toxin to the LPM, which should be applied carefully to desired anatomical points.

Determining the tendency for TMJ dysfunction may be significant in identifying high-risk patients. The type of LPM attachment may determine the tendency for TMJ disorders and may guide clinicians to use preventive treatment methods in those patients who are identified as being at risk.

Detailed and precise knowledge of LPM morphology will enable surgeons to determine TMJ problems and tendencies and to ensure an accurate diagnosis in order to apply the most suitable treatment and surgical approaches in clinical practice. We are planning a further study to investigate the insertion types using magnetic resonance images.

References

1. Juniper RP. The superior pterygoid muscle? Br J Oral Surg 1981; 19: 121-8.
2. Carpentier P, Yung JP, Marguelles-Bonnet R, Meunissier M. Insertions of the lateral pterygoid muscle: an anatomic study of the human temporomandibular joint. J Oral Maxillofac Surg 1988; 46: 477-82.
3. Salmon S. Muscle. In: Williams PL, Bannister LH, Berry MM, Collins P, Dyson M, Dussek JE, Ferguson MWJ, editors. Gray's anatomy. 38th ed. New York: Churchill Livingstone; 1995. p.799-802.
4. Foucart JM, Girin JP, Carpentier P. Innervation of the human lateral pterygoid muscle. Surg Radiol Anat 1998; 20: 185-9.
5. Zhang L, Sun L, Ma X. A macroscopic and microscopic study of the relationship between the superior lateral pterygoid muscle and the disc of the temporomandibular joint. Zhonghua Kou Qiang Yi Xue Za Zhi 1998; 33: 267-9.
6. Troiano MF. New concept of the insertion of the lateral pterygoid muscle. J Oral Surg 1967; 25: 337-40.
7. Porter MR. The attachment of the lateral pterygoid muscle to the meniscus. J Prosthet Dent 1970; 24: 555-62.
8. Widmalm SE, Lillie JH, Ash MM Jr. Anatomical and electromyographic studies of the lateral pterygoid muscle. J Oral Rehabil 1987; 14: 429-46.
9. Van Eijden TM, Koolstra JH, Brugman P. Architecture of the human pterygoid muscles. J Dent Res 1995; 74: 1489-95.
10. Naidoo LCD. Lateral pterygoid muscle and its relationship to the meniscus of the temporomandibular joint. Oral Surg Oral Med Oral Pathol Oral Radiol Endod 1996; 82: 4-9.
11. Naidoo LCD, Juniper RP. Morphometric analysis of the insertion of the upper head of the lateral pterygoid muscle. Oral Surg Oral Med Oral Pathol Oral Radiol Endod 1997; 83: 441-6.
12. Aziz MA, Cowie RJ, Skinner CE, Abdi TS, Orzame G. Are the two heads of the human lateral pterygoid separate muscles? A perspective based on their nerve supply. J Orofac Pain 1998; 12: 226-38.

13. Fujita S, Iizuka T, Dauber W. Variation of heads of lateral pterygoid muscle and morphology of articular disc of human temporomandibular joint - anatomical and histological analysis. *J Oral Rehabil* 2001; 28: 560-71.
14. Naohara H. The macroscopic and microscopic study of the human lateral pterygoid muscle. *Tsurumi Shigaku* 1989; 15: 1-26.
15. Abe S, Takasaki I, Ichikawa K, Ide Y. Investigations of the run and the attachment of the lateral pterygoid muscle. *Bull Tokyo Dent Coll* 1993; 34: 135-9.
16. Bertilsson O, Stom D. The anatomical relationship of the insertion of the superior lateral pterygoid muscle to the articular disc in the temporomandibular joint of human cadavers. *J Orofac Pain* 1995; 8: 17-23.
17. Cho H, Lee VS. A variety of heads of external pterygoid muscle. *Journal of Korean Dental Association* 1972; 10: 305-6.
18. Sugizaki M, Komori E, Nakazawa M. Anatomical studies of the lateral pterygoid muscle by the superior approach and a view of the literature. *Jpn J Oral Maxillofac Surg* 1986; 32: 718-30.
19. Dauber W. The adjacent structural relationships of the articular disk of the temporomandibular joint and its functional importance. *Schweiz Monatsschr Zahnmed* 1987; 97: 427-37.
20. Carranza ML, Carda C, Simbron A, Quevedo MC, Celaya G, de Ferraris ME. Morphology of the lateral pterygoid muscle associated to the mandibular condyle in the human prenatal stage. *Acta Odontol Latinoam* 2006; 19: 29-36.
21. Rees JA. Structure and function of the mandibular joint. *Brit Dent J* 1954; 96: 125-33.
22. McNamara JA. The independent functions of the two heads of the lateral pterygoid muscle. *Am J Anat* 1973; 138: 197-205.
23. Wilkinson T. The relationship between the disk and the lateral pterygoid muscle in the human temporomandibular joint. *J Prosthet Dent* 1988; 60: 715-24.
24. Wilkinson T, Chan EK. The anatomic relationship of the insertion of the superior lateral pterygoid muscle to the articular disc in the temporomandibular joint of human cadavers. *Aust Dent J* 1989; 34: 315-22.
25. Choukas NC, Sicher H. The structure of the temporomandibular joint. *Oral Surg Oral Med Oral Pathol* 1960; 13: 1203-13.
26. Meyenberg K, Kubik S, Palla S. Relationships of the muscles of mastication to the articular disc of the temporomandibular joint. *Schweiz Monatsschr Zahnmed* 1986; 96: 815-34.
27. Taskaya-Yılmaz N, Ceylan G, Incesu L, Muğlali M. A possible etiology of the internal derangement of the temporomandibular joint based on the MRI observations of the lateral pterygoid muscle. *Surg Radiol Anat* 2005; 27: 19-24.
28. Honée GL. The anatomy of the lateral pterygoid muscle. *Acta Morphol Neerl Scand* 1972; 10: 331-40.
29. Bakke M, Møller E, Werdelin LM, Dalager T, Kitai N, Kreiborg S. Treatment of severe temporomandibular joint clicking with botulinum toxin in the lateral pterygoid muscle in two cases of anterior disc displacement. *Oral Surg Oral Med Oral Pathol Oral Radiol Endod* 2005; 100: 693-700.
30. Yoshida K, Iizuka T. Botulinum toxin treatment for upper airway collapse resulting from temporomandibular joint dislocation due to jaw-opening dystonia. *Cranio* 2006; 24: 217-22.