

## Penile Mondor's disease can be effectively treated with the use of an acetyl salicylic acid and pentoxifylline combination

Mürsel DAVARCI, Eşref Oğuz GÜVEN, Ahmet GÖKÇE, Fatih Rüştü YALÇINKAYA, Ahmet Namık KİPER,  
Mevlana Derya BALBAY

**Aim:** Since penile Mondor's disease is a rare condition, different treatment choices are used. Herein we recommend a new treatment strategy with acetylsalicylic acid and pentoxifylline, which was tested in 14 patients with penile Mondor's disease.

**Materials and methods:** Fourteen patients with the clinical presentation of penile Mondor's disease were included. Patients were given acetylsalicylic acid (ASA) 500 mg qid and pentoxifylline 600 mg bid for 14 days. Physical examinations were performed in all patients. In addition, ultrasonic examinations were done before the treatment and on days 7 and 14 of treatment to evaluate dorsal vein thrombosis.

**Results:** Physical examinations revealed lesions parallel to the coronal sulcus in 9 patients and in the dorsal aspect of the proximal penis in 5 patients. All patients had painful induration of the penis. On day 7, hyperechoic structures were still observed in 8 patients and no thrombus was seen in 6 patients. Ultrasonographic measurements were repeated 14 days after treatment and a hyperechoic structure was observed in 4 patients. No side effects were encountered during the follow-up period.

**Conclusion:** We think that the ASA and pentoxifylline protocol, which is also used for the treatment of thrombotic events in other parts of the body, helps to resolve penile Mondor's disease in a shorter time compared to previous treatment protocols. Further randomized controlled studies are needed for a definitive decision.

**Key words:** Mondor's disease, thrombophlebitis, dorsal vein thrombosis, penis

### Penil Mondor hastalığı asetilsalisilik asit ve pentoksifilin kombinasyonu kullanarak etkili olarak tedavi edilebilir

**Amaç:** Penil Mondor hastalığı nadir bir durum olduğundan, bugüne değin farklı tedavi yöntemleri kullanılmıştır. Bu nedenle biz de bu çalışmamızda Penil Mondor hastalığı olan 14 hastada asetil salisilik asit (ASA) ve pentoksifilin ile yeni bir tedavi stratejisi önerdik.

**Yöntem ve gereç:** Bu çalışmaya penil Mondor hastalığı olan 14 hasta dahil edildi. Hastalara 14 gün boyunca ağız yoluyla ASA günde dört kez 500 mg ve pentoksifilin günde 2 kez 600 mg verildi. Fizik muayeneleri yapıldı. Tüm hastalara tedaviye başlamadan önce ve tedavinin 7. ve 14. günlerinde dorsal vendeki trombozisi değerlendirmek için ultrason yapıldı.

**Bulgular:** Fizik muayenede 9 hastada koronal sulkusa paralel ve 5 hastada proksimal penisin dorsal yüzünde lezyonlar gözlemlendi. Tüm hastalarda peniste ağrılı endurasyon vardı. 7. Gün ultrasonlarında 8 hastada penil dorsal veninde trombüsle uyumlu hiperekoik yapılar gözlemlendi. 6 hastada ise trombus izlenmedi. 14. gün yapılan ultrasonlarında ise, 4 hastada penil dorsal vende trombüsle uyumlu hiperekoik yapılar tekrar gözlemlendi. Takip süresince hiçbir yan etkiyle karşılaşılmadı.

**Sonuç:** Penil Mondor Hastalığının, vücudun diğer bölgelerinde gelişen trombotik olayların tedavisinde de kullanılan ASA ve pentoksifilin protokolüyle, önceki tedavi protokollerine oranla daha kısa sürede tedavi edilebileceğine inanıyoruz. Ancak kesin yargıya varmak için randomize kontrollü çalışmalara ihtiyaç vardır.

**Anahtar sözcükler:** Mondor hastalığı, tromboflebit, dorsal ven trombozu, penis

Received: 25.12.2009 – Accepted: 16.03.2010

Department of Urology, Faculty of Medicine, Mustafa Kemal University, Hatay - TURKEY

**Correspondence:** Mürsel DAVARCI, Department of Urology, Faculty of Medicine, Mustafa Kemal University, Hatay - TURKEY

E-mail: mdavarci1970@hotmail.com

## Introduction

Superficial vein thrombosis was initially described by Mondor in 1939 in the subcutaneous veins of the anterolateral thoraco-abdominal wall (1). Penile Mondor's disease was first described in the 1950s by Braun-Falco and then Helm and Hodge. Its incidence has recently been estimated as 1.39% (2). The underlying pathology is not completely understood yet, but stretching and torsion of penile veins due to prolonged and vigorous sexual intercourse is the most frequently blamed etiology. Previously, it has been treated with antibiotics, antiinflammatory drugs and local dressings containing heparin in most cases (3-5). Since the thrombi triggered mainly by trauma in the superficial vein of the penis are blamed for the symptoms in penile Mondor's disease, we decided to treat them with acetylsalicylic acid (ASA) and pentoxifylline for the first time. To the best of our knowledge, this is the first study that presents a series of penile Mondor's patients treated with ASA and pentoxifylline in the English literature.

## Materials and methods

Between January 2004 and December 2009, we treated 14 patients with the clinical presentation of a superficial penile vein thrombosis (SPVT) after obtaining their informed consent. All patients were admitted in the acute period. The interval between the onset of the patients' symptoms and their admittance to the clinic was a mean of 2.4 days (1-5 days). Additionally no fever increases were reported in the patients' histories. All patients had instantaneous and painful subcutaneous induration of the dorsal penile surface. For all patients, after a detailed anamnesis, ultrasonography (Doppler ultrasonography of penile vessels) and routine laboratory analysis (blood count, electrolytes, and coagulation tests) were performed. Primary therapy was medical, with oral application of ASA 500 mg qid and pentoxifylline 600 mg bid for 14 days. Follow-up examinations were done on days 7 and 15 of the treatment. Clinical improvement was judged by improvement in the pain and induration.

All of the patients were reassured of the benign nature of their conditions and were instructed to refrain from sexual activity until the problem resolved.

## Results

The median age of the patients with the combined treatment was  $40.5 \pm 10.5$  and the time to treatment

response was  $12.6 \pm 1.5$  (10-15) days. The standard laboratory tests before treatment were all normal in 14 patients. In the anamnesis thrombosis occurred after exaggerated sexual intercourse in 4 patients, in the remaining group 5 patients reported that they had had at least 10 days of sexual abstinence. The 5 remaining patients had no specific anamnesis before the development of their painful superficial thrombosis of the penis. Physical examinations revealed in 9 patients that the lesions were parallel to the coronal sulcus (giving the appearance of a double coronal sulcus) and 5 other patients had lesions in the dorsal aspect of the proximal penis. The length of the thrombotic vein was between 0.5 and 3 cm. The ultrasonographic findings were similar in all patients. A hyperechoic structure was found in the superficial dorsal vein. No venous flow signals were detected in this area of the blood vessel in Doppler ultrasonography. The diameter of the obstructed veins was  $3.24 \pm 0.07$  mm; range 2.8-3.8. Seven days after their first visit, 10 patients reported a decrease in the intensity of their pain and 4 patients continued to report palpable swellings. After a week on ASA and pentoxifylline treatment ultrasonographic measurements were repeated. The diameters of the involved veins did not change:  $3.19 \pm 0.07$  mm, range 2.8-3.6; hyperechoic structures were still observed in 8 patients; and no thrombus was seen in 6 patients. Venous diameters were measured 14 days after treatment and found to be  $2.97 \pm 0.06$  mm, range 2.8-3.6; and hyperechoic structure was observed in 4 patients. Those patients with persisting thrombi on ultrasound at 14 days were lost to follow up. No side effects were encountered during the follow-up period (Tables 1 and 2, Figure).

## Discussion

Since its first description by Braun-Falco in the 1950s, several treatment strategies were used to treat penile Mondor's disease. Previously, it was treated with antibiotics, antiinflammatory drugs, and local dressings containing heparin in most cases (3-5). The penile venous system can be influenced by inflammatory processes under certain conditions, such as sexual trauma in the dorsal region and thrombophlebitis of the ventral portion (5). Thrombosis of the dorsal vein of the penis is an unusual condition that tends to influence males between 21 and 70 years of age (6,7). In our study, the average age was 40 years, with the youngest and oldest patients being 25 and 65, respectively.

Table 1. Findings in patients' histories and physical examinations.

	Patients (n)	Percent (%)	
Anamnesis	Exaggerated sexual intercourse	4	28
	At least 10 days of sexual abstinence	5	36
	No specific anamnesis	5	36
	TOTAL	14	100
Location of Thrombus on Physical Examination	Parallel to the coronal sulcus	9	64
	The dorsal aspect of proximal penis	5	36
	TOTAL	14	100

Table 2. Evolution of Doppler penile ultrasound findings on treatment.

			Mean ± SEM
VEINS' DIAMETERS	Day 0	Thrombosis (+) (n = 14, 100%)	3.24±0.07
		Thrombosis (-) (n = 0, 0%)	—
		TOTAL (n = 14, 100%)	3.24 ± 0.07
	DAY 7	Thrombosis (+) (n = 8, 53%)	3.33 ± 0.09
		Thrombosis (-) (n = 6, 47%)	3.00 ± 0.06
		TOTAL (n = 14, 100%)	3.19 ± 0.07
	DAY 14	Thrombosis (+) (n = 4, 29%)	3.18 ± 0.14
		Thrombosis (-) (n = 10, 71%)	2.9 ± 0.05
		TOTAL (n = 14, 100%)	2.97 ± 0.06

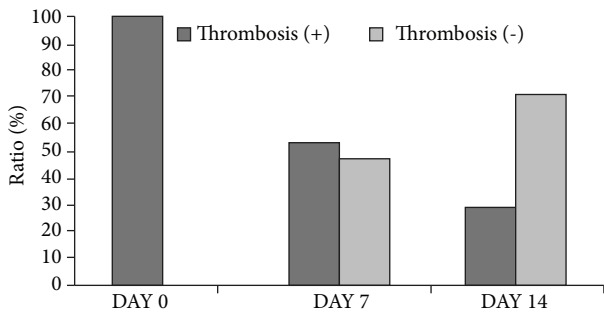


Figure. Decrease in the visible thrombosis in superficial penile veins on ultrasound.

Published data on superficial penile vein thrombosis are unusual and mostly reported as single-case studies, except a few with 5 patients and more (3,4,6,8). The largest study has been performed by Al-Mwalad with 25 patients (8). Our study is the second largest study in literature, with 14 patients.

Mondor's disease is a benign and generally a self-limited procedure. Patients complain of a cord-like induration, which is often painful, in the dorsal facet of the penis, and this pain can be continuous or episodic. All of the patients in our study had painful sexual intercourse.

The etiology of this condition is commonly unfamiliar, but several causative factors have been reported, e.g., idiopathic (9), penile trauma,

immoderate sexual activity, extended sexual avoidance, infection, pelvic tumors, and constrictive elements used during certain sexual practices; of these, the trauma caused by sexual intercourse appears to be the principal etiologic factor (10,11). In our study thrombosis occurred after exaggerated sexual intercourse in 4 patients; in the remaining group 5 patients reported that they had had at least 10 days of sexual abstinence. The 5 remaining patients had no specific anamnesis before the development of their painful superficial thrombosis of the penis.

Ultrasound and Doppler ultrasound investigations were adequate to evaluate the extent of the thrombosis (6). According to the results of our study and previous published studies, extra invasive diagnostic protocols do not provide more information on the management of the thrombosis (3-7). However, a recent published article focused on the usefulness of MR-angiography to deepen the diagnostic pathway whenever a complex pathogenesis was suspected (12).

A sequence of treatment choices is available, in accordance with the clinical stage of the disorder. In principle the best approach seems to be conservative management, assuring the patient about the benign nature of their condition and recommending sexual abstinence until full healing has occurred. Treatments include antiinflammatory drugs, antibiotics, and local heparin-containing creams (8,11,13). Pentoxifylline

(Trental, Aventis Pharmaceuticals Inc. Kansas City, MO, USA), a trisubstituted xanthine derivative, is a hemorheologic agent that has been in use since the 1970s. The primary indication for its use was for the treatment of intermittent claudication due to arterial occlusive disease in the lower extremities. Pentoxifylline has also been used to treat other diseases, including venous stasis leg ulcers, sepsis, and hepatic fibrosis (14-16). The mechanism of the effect of pentoxifylline is poorly understood. Pentoxifylline reduces blood viscosity by increasing erythrocyte flexibility, reduces platelet aggregation, increases leukocyte migration, and reduces plasma viscosity (17). Since the thrombi triggered mainly by trauma in the superficial vein of the penis are blamed for the symptoms in penile Mondor's disease, it would be reasonable to use an agent that has multiple effects on blood viscosity. Therefore, we administered pentoxifylline and ASA for the first time in penile Mondor's disease in our study. The acute presentations in all cases were treated very effectively with ASA and pentoxifylline. Before the treatment,

thrombi were detected in 100% of the patients, ultrasonographically. The detection rates of thrombi were 53% and 29% after 7 and 14 days of treatment, respectively. To our knowledge this is the first presentation of a series of Mondor's patients treated with ASA and pentoxifylline in the English literature. In advanced stages, antiinflammatory drugs and local heparin-containing creams can be prescribed. Local anesthetic infiltration around the affected venous segment can be useful for treating the pain, though it proves ineffective in cases of infection; antiinflammatory drugs and antibiotics are indicated in such situations. In tenacious cases surgery may be necessary, with thrombectomy or resection of the superficial dorsal vein (11).

In conclusion, penile Mondor's disease can be effectively treated with ASA 500 mg qid and pentoxifylline 600 mg bid for 14 days, a treatment method also used for thrombotic events in other parts of the body. We think that this treatment protocol helps to resolve thrombotic penile disease conservatively and in a shorter time than previous treatment protocols.

## References

- 1 Nachmann MM, Jaffe JS, Ginsberg PC, Horrow MM, Harkaway RC. Sickle cell episode manifesting as superficial thrombophlebitis of the penis. *J Am Osteopath Assoc* 2003; 103: 102-4.
- 2 Kumar B, Narang T, Radotra BD, Gupta S. Mondor's disease of penis: A forgotten disease. *Sex Transm Infect* 2005; 81: 480-2.
- 3 Kraus S, Ludecke G, Weidner W. Mondor's disease of the penis. *Urol Int* 2000; 64: 99-100.
- 4 Lilas LA, Mumtaz FH, Madders DJ, McNicholas TA. Phimosis after penile Mondor's phlebitis. *BJU Int* 1999; 83: 520-1.
- 5 Sasso F, Gulino G, Basar M, Carbone A, Torricelli P, Alcini E. Penile Mondor's disease: An underestimated pathology. *Br J Urol* 1996; 77: 729-32.
- 6 Ozkara H, Akkus E, Alici B, Akpınar H, Hattat H. Superficial dorsal penile vein thrombosis (penile Mondor's disease). *Int Urol Nephrol* 1996; 28: 387-91.
- 7 Swierzewski SJ, Denil J, Ohl DA. The management of penile Mondor's phlebitis - superficial dorsal penile vein-thrombosis - reply. *J Urol* 1994;152: 492.
- 8 Al-Mwalad M, Loertzer H, Wicht A, Fornara P. Subcutaneous penile vein thrombosis (penile Mondor's disease): Pathogenesis, diagnosis, and therapy. *Urology* 2006; 67: 586-8.
- 9 Atan A, Gungor S, Ozergin O, Aslan Y, Vural M. Idiopathic penile Mondor's disease: A case report. *Int Urol Nephrol* 2002; 34: 97-9.
- 10 Koh JS, Suh HJ, Choe HS, Jung JH, Kim YS, Kim JA. Superficial thrombophlebitis of the dorsal vein of the penis (penile Mondor's disease) *Korean J Urol* 2004; 45: 399-401.
- 11 Rodriguez Faba O, Parra Muntaner L, Gomez Cisnerros SC, Martin Benito JL, Escaf Barmadah S: [thrombosis of the dorsal penis vein (of Mondor's phlebitis). Presentation of a new case]. *Actas Urol Esp* 2006; 30: 80-2.
- 12 Boscolo-Berto R, Iafrate M, Casarrubea G, Ficarra V. Magnetic resonance angiography findings of penile mondor's disease. *J Magn Reson Imaging* 2009; 30: 407-10.
- 13 Kartsaklis P, Konstantinidis C, Thomas C, Tsimara M, Andreadakis S, Gekas A. Penile Mondor's disease: A case report. *Cases J* 2008; 1: 411.
- 14 Jull A, Waters J, Arroll B. Pentoxifylline for treatment of venous leg ulcers: A systematic review. *Lancet* 2002; 359: 1550-4.
- 15 Reynolds H. Pentoxifylline—more evidence that it improves host defenses during sepsis. *Crit Care Med* 1999; 27: 1-683.
- 16 Schuppan D, Strobel D, Hahn EG. Hepatic fibrosis - therapeutic strategies. *Digestion* 1998; 59: 385-90.
- 17 Ward A, Clissold SP. Pentoxifylline. A review of its pharmacodynamic and pharmacokinetic properties, and its therapeutic efficacy. *Drugs* 1987; 34: 50-97.