

## The effect of alkali burn on corneal glutathione peroxidase activities in rabbits

İlknur AKYOL SALMAN<sup>1</sup>, Ahmet KIZILTUNÇ<sup>2</sup>, Orhan BAYKAL<sup>1</sup>

**Aim:** Glutathione peroxidase (GPx) is an important corneal defense enzyme for protecting against hydrogen peroxides and lipid peroxides. In the present study, corneal GPx activities after alkali burn of the cornea were evaluated in rabbits.

**Materials and methods:** Corneal alkali burn was created in the right eye of 10 rabbits by applying a 6 mm round filter paper soaked in 1 N NaOH onto the central cornea for 60 s. The right eyes of 10 healthy rabbits served as controls. The corneal GPx activities were determined by the method of Paglia and Valentina, 10 days after the burn.

**Results:** GPx activities were reduced significantly in alkali burned corneas compared to the normal controls ( $P < 0.05$ ).

**Conclusion:** The data suggest that decreased GPx activities predispose the cornea to injury from reactive oxygen radicals, besides the initial chemical damage of alkali burn.

**Key words:** Corneal alkali burn, free oxygen radicals, glutathione peroxidase, hydrogen peroxide, reactive oxygen species

### Tavşanlarda alkali yanığın korneal glutatyon peroksidaz aktivitesi üzerine etkisi

**Amaç:** Glutatyon peroksidaz (GPx), korneada hidrojen peroksit ve lipid peroksitlere karşı önemli bir savunma enzimidir. Bu çalışmada, tavşanlarda korneadaki GPx aktivitesi, korneal alkali yanık sonrası değerlendirildi.

**Yöntem ve gereç:** Korneal alkali yanık, 10 tavşanın sağ göz kornea merkezine, 1 N NaOH emdirilmiş 6 mm çaplı filtre kağıdı 60 saniye tatbik edilerek oluşturuldu. 10 sağlıklı tavşanın sağ gözü kontrol olarak kullanıldı. Yanık sonrası 10 günde, Paglia ve Valentina yöntemi ile korneal GPx aktivitesi değerlendirildi.

**Bulgular:** Alkali yanıklı kornealarda GPx aktivitesi, normal kontrollere göre anlamlı derecede azaldı ( $P < 0,05$ ).

**Sonuç:** Alkalinin başlangıçtaki kimyasal hasarının yanı sıra, azalmış GPx aktivitesi, korneayı reaktif oksijen radikallerinin hasarına da maruz bırakmaktadır.

**Anahtar sözcükler:** Korneal alkali yanık, serbest oksijen radikalleri, glutatyon peroksidaz, hidrojen peroksit, reaktif oksijen partikülleri

Received: 04.11.2009 – Accepted: 17.08.2010

<sup>1</sup> Department of Ophthalmology, Faculty of Medicine, Atatürk University, Erzurum - TURKEY

<sup>2</sup> Department of Biochemistry, Faculty of Medicine, Atatürk University, Erzurum - TURKEY

**Correspondence:** İlknur AKYOL SALMAN, Atatürk Üniversitesi Posta İşletme Merkez Md., Posta Kutusu 19, 25240 Erzurum - TURKEY

E-mail: ilkakyol@atauni.edu.tr

## Introduction

Although alkali agents are independently toxic to the cornea, to a large extent their injury to living cells is also mediated by the generation of reactive oxygen radicals (1-3). To deal with the damage by reactive oxygen radicals, the cornea possesses integrated enzymatic and non-enzymatic antioxidant and repair systems (4-6). The antioxidant defense enzymes react with reactive oxygen radicals and cellular products of free radical chain reactions to convert them to nontoxic products. An important corneal antioxidative enzyme, glutathione peroxidase (GPx), has the ability to detoxify hydrogen peroxide and lipid peroxides in cells, and protects the cell protein and membrane against oxidation (7). Thus, the current work was undertaken to study the corneal GPx activities of the cornea after an alkali burn.

## Materials and methods

Ten New Zealand white rabbits weighing 2.5-3.0 kg were anesthetized by i.m. ketamine hydrochloride at 25 mg/kg body wt. Additional local anesthesia was achieved by instillation of 0.5% proparacaine hydrochloride solution. Corneal alkali burn was created in the right eye of each rabbit by applying a 6 mm round filter paper soaked in 1 N NaOH onto the central cornea for 60 s. After the standardized exposure to alkali agent, the eyes were rinsed by dropping 2 mL of physiological saline for 2 min (8). Ofloxacin 0.3% (Exocin; Allergan, Westport, Co. Mayo, Ireland) was applied daily to prevent corneal infection. The right eyes of 10 healthy rabbits served as controls. Ten days after the burn, the animals were killed by intravenous injection of 100 mg/kg pentobarbital. Then the entire corneal tissues in each rabbit were removed for GPx analysis.

Each corneal tissue was homogenized in 3 mL of 0.1 M Tris-HCl buffer (pH 7.2), containing 154 mM NaCl. It was performed on ice by a mechanical homogenizer (OMNI TH International, model TH 220 Warrenton, VA, USA). The homogenate was centrifuged at 10,000  $\times$ g for 15 min at 4 °C. The

supernatant was stored at -80 °C in aliquots. The protein concentration of supernatant was determined by Bradford's method (9).

GPx activity was measured by the method of Paglia and Valentina (10). Briefly, 100  $\mu$ L of corneal supernatant in 1 mL of reaction mixture, containing 50 mM potassium phosphate buffer (pH 7.0), 3.6 mM sodium azide, 5 mM GSH, 0.3 mM NADPH, and 10  $\mu$ L of glutathione reductase, was incubated at 37 °C for 10 min. After the addition of 50  $\mu$ L of tert-butyl hydroperoxide (tBH), the reduction in the absorbance of NADPH at 340 nm was measured. By measuring the absorbance change per minute and by using the molar extinction coefficient of NADPH, GPx activity was calculated. The activity was expressed in units per gram of wet tissue (U/g.wet.tissue).

The animals were treated under the Guidelines for Animal Research at Atatürk University Faculty of Medicine, and the ARVO resolution on the Care and Use of Animals in Vision Research.

Normality of the data was tested with the Shapiro-Wilk test. The difference between the 2 groups was evaluated by independent samples t test and P values less than 0.05 were considered statistically significant. Data were analyzed using SPSS 15.0 for Windows (SPSS Inc., Chicago, USA).

## Results

The cornea was resurfaced completely by epithelium by 7-10 days postburn. Infiltration, corneal perforation, and neovascularization of the corneas and redness of the eyes were not observed. Immediately after the corneal alkali injury the stroma turned very opaque, producing a sharp demarcation from the surrounding transparent non-injured area. The size of the opacity was maintained during the 1 week of observation.

The mean corneal GPx activities of the groups are presented in the Table. After alkali burn of the cornea, the corneal GPx activities were significantly reduced compared to the normal control values ( $P < 0.05$ ) (Figure).

Table. Corneal GPx activities in the groups (mean  $\pm$  SD).

Group	GPx activities (U/g.wet.tissue)
Group 1 (alkali burned)	1743.78 $\pm$ 487.45
Group 2 (control)	2311.09 $\pm$ 598.30

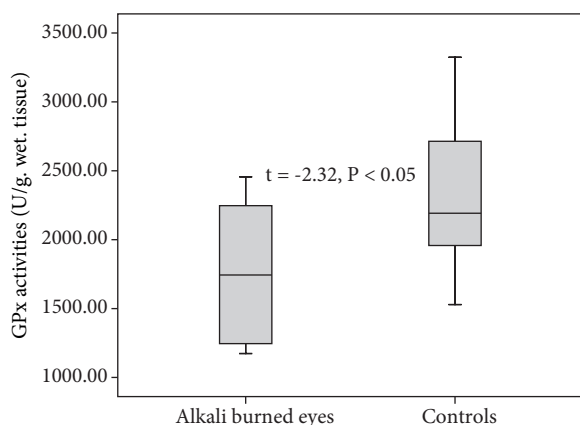


Figure. Corneal GPx activities in the groups.

## Discussion

Hydrogen peroxide ( $H_2O_2$ ), superoxide ( $O_2^-$ ), and hydroxyl radical (OH) are oxygen-containing compounds that are highly reactive free radicals, or compounds that damage cellular lipids, proteins, carbohydrates, and DNA (7). Recent years have witnessed an explosion of knowledge implicating free radicals and oxidative stress in virtually every aspect of biology and medicine (11). Oxidative stress is not just being recognized as a pivotal common pathway for cellular death and dysfunction, but also as an important target for therapeutic intervention (11). Intense exposure to light, robust metabolic activity, and high oxygen tension render the human eye particularly vulnerable to oxidative damage and the list of ophthalmological conditions potentially involving reactive oxygen radicals is rapidly expanding (6,7,11,12).

Although alkali agents are independently toxic to the cornea, to a large extent their injury to living cells is also mediated by the generation of reactive oxygen radicals (1-3,8,13). Increased malondialdehyde levels, the final product of lipid peroxidation, and decreased superoxide dismutase activities, an

enzymatic scavenger of the superoxide free radical, have been reported in aqueous humor after the severe alkali burn of the cornea (13). Reactive oxygen radicals could be released from the burnt cells of the necrotic tissue (3) and be generated by the infiltrating polymorphonuclear cells at the site of tissue damage after the alkali burn (1,7).

It was reported that hydrogen peroxide is the primary damaging agent in the corneal scavenging system (4). Hydrogen peroxide can generate highly reactive hydroxyl radicals through the nonenzymatic Fenton reaction. Because hydrogen peroxide is lipid soluble, it can diffuse through membranes and generate hydroxyl radical at localised  $Fe^{2+}$ - or  $Cu^+$  containing sites, such as the mitochondria. The highly toxic hydroxyl radicals initiate chain reactions that form lipid peroxides and lipid free radicals in membranes, causing lipid degradation. Hydrogen peroxide is also the precursor of hypochlorous acid, a powerful oxidizing agent that is produced endogenously and enzymatically by phagocytic cells. The superoxide anion is also highly reactive, but has limited lipid solubility and cannot diffuse far. However, it can generate the more reactive hydroxyl and hydroperoxy radicals by reacting nonenzymatically with hydrogen peroxide in the Haber-Weiss reaction (7,12).

GPx is an important corneal defense enzyme for protecting against hydrogen peroxides and lipid peroxides (5). After alkali burns the corneal GPx activities were reduced significantly compared to the normal controls in the present investigation. Our results suggested that, even after the mild alkali burn, the corneal scavenging systems for hydrogen peroxides and lipid peroxides were reduced. Thus, the cornea becomes more susceptible to the harmful effects of reactive oxygen radicals after the alkali burn.

Pharmacological treatments to reduce oxidative damage in corneal tissue after alkali burns are still under investigation (1,2,14-18). The use of antioxidants, such as ascorbic acid, and superoxide dismutase, has been observed to improve corneal wound healing (2,15-17).

In the previous experimental investigation by Nirankari et al., the use of glutathione as an antioxidant was not effective in the treatment of

alkali burned corneas (2). Our finding, the decrease in corneal GPx activity after the alkali burn, may be one of the reasons for the inefficiency of the external supplementation of glutathione, because glutathione acts as a cofactor with the enzyme GPx to detoxify hydrogen peroxide and lipid peroxides in cells and tissues. For that reason, an external supplementation of glutathione and GPx together may be required to

provide optimum protection against alkali induced damage in the cornea.

In conclusion, the present study demonstrates that corneal GPx activity was significantly reduced after alkali burn injury of the cornea. The data suggest that decreased GPx activities predispose the cornea to injury from reactive oxygen radicals, besides the initial chemical damage of the alkali burn.

## References

1. Pfister RR, Pfister DR. Alkali injuries of the eye. In: Krachmer JH, Mannis MJ, Holland EJ, editors. *Cornea*. Philadelphia: Elsevier Mosby; 2005. p.1285-1293.
2. Nirankari VS, Varma SD, Lakhanpal V, Richards RD. Superoxide radical scavenging agents in treatment of alkali burns. An experimental study. *Arch Ophthalmol* 1981; 99: 886-7.
3. Kuckelkorn R, Schrage N, Keller G, Redbrake C. Emergency treatment of chemical and thermal eye burns. *Acta Ophthalmol Scand* 2002; 80: 4-10.
4. Crouch R, Ling Z, Hayden BJ. Corneal oxygen scavenging systems: lysis of corneal epithelial cells by superoxide anions. *Basic Life Sci* 1988; 49:1043-6.
5. Atalla LR, Sevenian A, Rao NA. Immunohistochemical localization of glutathione peroxidase in ocular tissue. *Curr Eye Res* 1988; 7:1023-7. Erratum in: *Curr Eye Res* 1989; 8: 229.
6. Kuo IC. Corneal wound healing. *Curr Opin Ophthalmol* 2004; 15: 311-5.
7. Smith C, Marks AD, Liberman M. Oxygen toxicity and free radical injury. In: Marks' *Basic Medical Biochemistry A Clinical Approach*. Philadelphia: Lippincott Williams & Wilkins; 2005. p. 439-457.
8. Chung JH. Experimental corneal alkali wound healing. *Acta Ophthalmologica Suppl* 1988; 187: 4-35.
9. Bradford MM. A rapid and sensitive method for the quantitation of microgram quantities of protein utilizing the principle of protein-dye binding. *Anal Biochem* 1976; 72: 248-54.
10. Paglia DE, Valentina WN. Studies on the quantitative and qualitative characterization of erythrocyte glutathione peroxidase. *J Lab Clin Med* 1967; 70: 158-69.
11. Shoham A, Hadziahmetovic M, Dunaief JL, Mydlarski MB, Schipper HM. Oxidative stress in diseases of the human cornea. *Free Radic Biol Med* 2008; 45: 1047-55.
12. Carubelli R, Nordquist RE, Rowsey JJ. Role of active oxygen species in corneal ulceration. Effect of hydrogen peroxide generated in situ. *Cornea* 1990; 9: 161-9.
13. Yuan HP, Lu SR, Wang BL. An experimental study of treatment with superoxide dismutase for alkali burn in the anterior segment of the rabbit eye. *Zhonghua Yan Ke Za Zhi* 1994; 30: 50-2.
14. Alio JL, Avala MJ, Mulet ME, Artola A, Ruiz JM, Bellot J. Antioxidant therapy in the treatment of experimental acute corneal inflammation. *Ophthalmic Res* 1995; 27: 136-43.
15. Levinson RA, Paterson CA, Pfister RR. Ascorbic acid prevents corneal ulceration and perforation following experimental alkali burns. *Invest Ophthalmol Vis Sci* 1976; 15: 986-93.
16. Pfister RR, Paterson CA. Additional clinical and morphological observations of the favorable effect of ascorbate in experimental ocular burns. *Invest Ophthalmol Vis Sci* 1972; 16: 478-87.
17. Pfister RR, Paterson CA, Hayes CA. Topical ascorbate decreases the incidence of corneal ulceration after experimental alkali burns. *Invest Ophthalmol Vis Sci* 1978; 17: 1019-24.
18. Makarov PV, Titkova SM, Anurov MV, Mikhal'chik EV, Chesnokova NB, Beznos OV et al. Examination of the local antioxidative system of the eye in experimental corneal burn injury and the prospects for pharmacological correction of its parameters. *Vestn Oftalmol* 2005; 121: 40-3.