

## The prenatal diagnosis of familial satellited Yq chromosomes

Sezin YAKUT<sup>1</sup>, Saffet ÖZTÜRK<sup>2</sup>, Mehmet ŞİMŞEK<sup>3</sup>, İbrahim İnanç MENDİLCİOĞLU<sup>3</sup>, Güven LÜLECI<sup>1</sup>

**Aim:** To report a rare chromosomal abnormality, familial satellited Y chromosome (Yqs), in 3 Turkish prenatal cases.

**Material and methods:** Metaphase chromosomes were prepared from amniocytes for prenatal cases and from lymphocytes for their fathers according to the standard methods.

**Results:** In all cases, the analysis of all GTG-banded metaphases showed satellites on the long arms of chromosome Y as 46, XYqs karyotype. The indications for cytogenetic study were advanced maternal age and abnormal ultrasonographic findings with increased risk in the first trimester screening test. Cytogenetic studies of the fathers revealed that the Yqs were inherited. The satellites were positively stained by the silver-NOR technique, suggesting that the NORs were active for all cases. In accordance with the literature and the finding of paternal inheritance in all cases, genetic counselling was given to the families. The families decided to continue the pregnancies and all 3 babies were born at term without any dysmorphic features.

**Conclusion:** Proper genetic counseling requires the accumulation of detailed information about the clinical follow-up evaluations and determination of whether the satellited Yqs is de novo or familial.

**Key words:** Prenatal diagnosis, satellited Y chromosome, Yqs

### Ailesel Yq kromozomlarının prenatal tanısı

**Amaç:** Bu çalışmanın amacı, nadir bir kromozomal abnormalite olan ailesel satellitli Yq kromozomunun 3 Türk prenatal hastasında rapor etmektir.

**Yöntem ve gereç:** Metafaz kromozomları prenatal hastaları için amniyositlerden ve olguların babaları için ise lenfositlerden standart metodlara uygun olarak hazırlanmıştır.

**Bulgular:** Tüm hastalarda, GTG bantlama ile bantlanan metafazların analizi sonucunda, 46, XYqs karyotipi olarak tanımlanan Y kromozomunun uzun kolunda satellit gözlenmiştir. Sitogenetik analiz için endikasyonlar, ileri anne yaşı, ultrasonografide anormal bulgular ve bununla birlikte ilk trimester tarama testinde risktir. Olguların babalarının sitogenetik analizleri sonucunda Yqs'in ailesel olduğu belirlenmiştir. Satellitlerin gümüş-NOR tekniği ile pozitif boyanması, satellitlerin tüm olgularda aktif olduğunu göstermiştir. Literatüre göre ve tüm olgulardaki ailesel geçiş de göz önüne alınarak, ailelere genetik danışma verilmiştir. Aileler hamilelikleri devam ettirme kararı almışlardır. 3 bebek zamanında, hiçbir dismorfik belirti göstermeksizin doğmuştur.

**Sonuç:** Klinik takip ile ilişkili detaylı bilgi birikimi ve satellitli Yqs'lerin de novo mı yoksa ailesel mi olup olmadığının belirlenmesi, uygun bir genetik danışma için gereklidir.

**Anahtar sözcükler:** Prenatal tanı, satellitli Y kromozomu, Yqs

Received: 16.06.2010 – Accepted: 02.08.2010

<sup>1</sup> Department of Medical Biology and Genetics, Faculty of Medicine, Akdeniz University, 07070, Antalya - TURKEY

<sup>2</sup> Department of Histology and Embryology, Faculty of Medicine, Akdeniz University, 07070, Antalya - TURKEY

<sup>3</sup> Department of Obstetrics and Gynecology, Faculty of Medicine, Akdeniz University, 07070, Antalya - TURKEY

**Correspondence:** Sezin YAKUT, Department of Medical Biology and Genetics, Faculty of Medicine, Akdeniz University, 07070, Antalya - TURKEY

E-mail: seziinyakut@yahoo.com

## Introduction

The satellited Y chromosome (Yqs) was first described by Genest et al. (1967) and belongs to the category of very rare structural variations in the human karyotype (1). Several reports have stated that most satellited Y chromosomes occurred on the long arm of the Y chromosome and in a family line (2,3). Differences in the position of the breaks within the heterochromatin band, Yq12, and the structure of the satellite region in Yqs chromosomes show interfamilial differences (2).

It is generally accepted that the Yqs chromosome is the product of a translocation of part of the NOR-bearing short arm of an acrocentric chromosome to the long arm of the Y chromosome, causing its satellited appearance (4). Breakpoints map within the Yq and the proximal short arm of an acrocentric chromosome, resulting in the gain of a nucleolus organizer region (NOR) including the telomere repeat (TTAGGG)<sub>n</sub> combined with the loss of the pseudoautosomal region 2 (PAR2) at the long arm of the recipient Y chromosome. PAR2 is discovered near the Xq and Yq telomeres which are necessary for pairing, chiasma formation, and the correct subsequent segregation during male meiosis. There are 4 genes in the PAR2 region: SYB1 and HSPRY3 located in the proximal side and IL9R and CXY in the distal side. The phenotype, including infertility, depends on the amount of the region that is deleted during translocation between the Y chromosome and the acrocentric chromosomes (4).

In this study, we report the results of the detection of the satellited Y chromosome (accepted as a rare structural Y chromosome aberration) during prenatal diagnosis in 3 familial cases and the importance of giving genetic counseling to the families.

### Case 1

A 36-year old Turkish woman was referred for prenatal diagnosis in her fourth pregnancy because of advanced maternal age. An amniocentesis was performed at 17 weeks' gestation. Her first pregnancy ended in curettage due to unwillingness on the part of the family; her 11 and 5 year-old daughters were healthy. There were no known diseases found in either the patient or her husband. Moreover, there was no history of mental retardation, physical malformation, or any other disease caused by chromosomal abnormalities.

### Case 2

A 31-year old Turkish woman was referred for prenatal diagnosis in her second pregnancy because of an abnormal ultrasound which found a single umbilical artery. An amniocentesis was performed at 25 weeks' gestation. Her 11 year-old boy was healthy. The previous medical history was unremarkable for both parents and there was no history of mental retardation, physical malformation, or any other disease caused by chromosomal abnormalities.

### Case 3

A 39-year old Turkish woman was referred for prenatal diagnosis in her fifth pregnancy due to an increased risk in the first trimester screening test and the patient's advanced age. An amniocentesis was performed at 23 weeks' gestation. Although she had a previous history of 2 missed abortions, both of her children were healthy. There were no known diseases in either the patient or her husband. Additionally, there was no history of mental retardation, physical malformation, or any other disease caused by chromosomal abnormalities.

### Conventional cytogenetic analysis

The proband's amniotic fluid samples were cultivated in a long-term cell culture with 2 different media in order to show the possible culturation artefacts, at 37 °C in a CO<sub>2</sub> incubator and harvested using the standard methods. Short term PHA-stimulated peripheral blood lymphocyte cultures of the proband's fathers and grandfathers were performed according to standard procedures. We analyzed 20 metaphase plates at 550 band level after GTG banding. Karyotyping was performed using the Applied Biosystem system. Silver-NOR staining was performed according to standard protocols (5).

## Results

In all cases, the analysis of GTG-banded metaphases in amniotic cells showed satellites on the long arms of chromosome Y (Figure 1a, b, c). In order to confirm this observation, the silver-NOR staining technique was used. The satellites were positively stained by the silver-NOR technique, suggesting that the NORs were active (Figure 2a, b).

In case 1, the chromosomes of the father and the grandfather of the fetus were studied after culturing

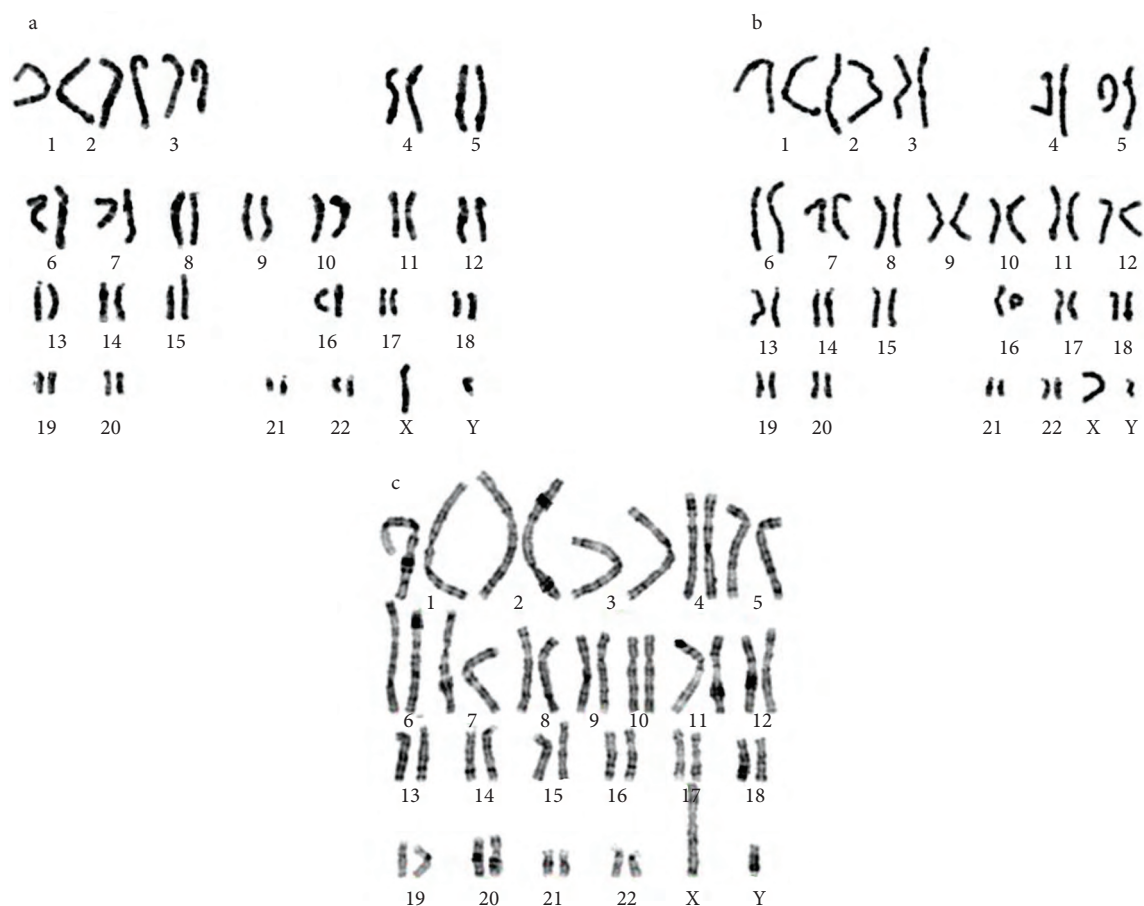

Figure 1. GTG banded karyotypes showing a) case 1; b) case 2; and c) case 3.

their lymphocytes. Silver-NOR banding showed the Yqs chromosome in both the father and the grandfather. Double satellites on the short arm of chromosome 15 were also observed in both father and grandfather.

In cases 2 and 3, the Yqs chromosomes were also demonstrated in the father with GTG and silver-NOR banding. Conventional cytogenetic analyses were not performed on the grandfathers.

In light of the fact that the satellited Y chromosomes were inherited from the fathers, genetic counseling was given to the families. It was expressed that this was a normal variant of the Y chromosome and no phenotypical abnormalities were anticipated after the pregnancy. The families decided to continue the pregnancies and all 3 babies were born at term without any dysmorphic features.

## Discussion

The presence of satellites on the Y chromosome is rare and such satellites are usually localized on the long arm of the Y chromosome. It is generally accepted that Yqs is derived from a translocation between the short arms of an acrocentric chromosome of the D or G groups and the terminal end of the long arm of the chromosome Y (3).

As known, the presence of a Yqs chromosome causes no phenotypic abnormalities in the carriers (2). That the extra satellite's genetic material causes no phenotypic abnormalities could be explained by the fact that the satellite's genes that code for the 18S and 28S ribosomal RNA are multiple copies distributed over the nucleolar organizer regions (NOR) and since these regions are rarely active at any one time, the presence of additional copies has no deleterious

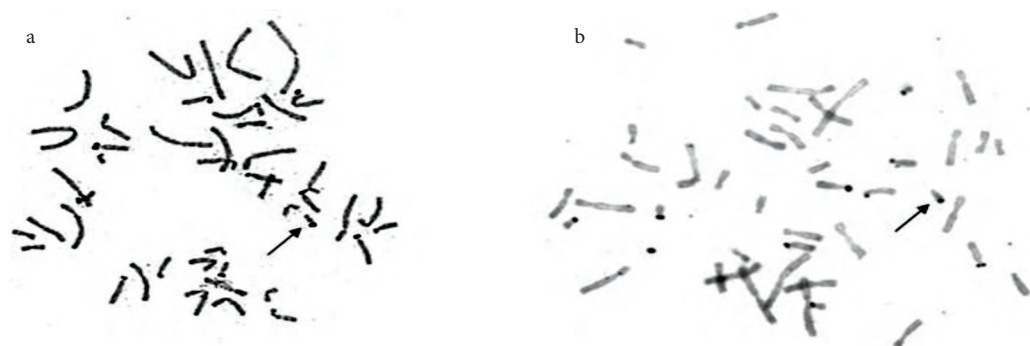


Figure 2. AgNOR banded metaphase plates showing a) case 2 and b) case 3.

effect. This theory is supported by the fact that silver-NOR never stains the satellites of all acrocentric chromosomes in the same metaphase (6).

The amount of the deleted region of Y chromosome has a great effect on the clinical consequences (4). Chandly et al. reported a case of infertility in a patient with deletions in the Yq11 region, including azoospermia factor (AZF). The father and a fertile brother of the patient showed satellited Y chromosome (Yqs) in their karyotypes (7). Stella et al. suggested that large satellites lead to the nonrandom segregation of homologous chromosomes during meiosis, a process which may possibly encourage a predisposition to nondisjunction and which might be associated with the carriers of Yqs (8). Even if the satellited Y chromosome is familial, however, the clinical outcome is generally normal (2).

The satellites are derived from acrocentric chromosomes mostly from chromosome 15 or, less

frequently, from chromosomes 21, 13, or 14 (2). In our cases, silver-NOR staining patterns indicated that the satellites on the Y chromosome might have been derived from chromosome 15. We believe that silver-NOR staining might be the first step to discovering the origin of the satellites but the other molecular techniques are needed to confirm the exact results.

In conclusion, it appears the presence of an extra NOR or NOR-associated heterochromatin in the Yqs chromosome does not cause any phenotypic abnormalities as long as the Y euchromatin is intact. In order to provide proper genetic counseling, it should be determined whether the incidence of the satellited Yqs is de novo or familial.

### Acknowledgements

This study was supported by the Scientific Research Projects Unit of Akdeniz University in Antalya, Turkey.

### References

1. Genest P, Bouchard M, Bouchard J. A satellited human Y chromosome: an evidence of autosome gonosome translocation. *Can J Genet Cytol* 1967; 9: 589-595.
2. Schmid M, Haaf T, Solleder E, Schempp W, Leipoldt M, Heilbronner H. Satellited Y chromosomes: structure, origin, and clinical significance. *Hum Genet* 1984; 67: 72-85.
3. Verma RS, Gogineni SK, Kleyman SM, Conte RA. Characterisation of a satellited non-fluorescent Y chromosome (Y[*nfqs*]) by FISH. *J Med Genet* 1997; 34: 817-818.
4. Kühl H, Röttger S, Heilbronner H, Enders H, Schempp W. Loss of the Y chromosomal PAR2-region in four familial cases of satellited Y chromosomes (Yqs). *Chromosome Res* 2001; 9: 215-22.
5. Verma RA, Babu A. Human chromosomes: principles and techniques. New York: McGraw Hill, 1995.
6. Henderson AS, Warburton D, Atwood KC. Ribosomal DNA connectives between human acrocentric chromosomes. *Nature* 1973; 245: 95-97.
7. Chandley AC, Gosden JR, Hargreave TB, Spowart G, Speed RM, McBeath S. Deleted Yq in the sterile son of a man with satellited Y chromosome. *J Med Genet*. 1989; 26: 145-153.
8. Stella M, Rossi R, Bonfante A & Rossi G. A new case of human Y chromosome with satellites on the long arm. *J Génét Hum* 1980; 28: 39-45.