

## A case with type IV dual left anterior descending coronary artery detected by multidetector computed tomography

Tahir DURMAZ<sup>1</sup>, Melike Ruşen METİN<sup>3</sup>, Telat KELEŞ<sup>1</sup>, Hüseyin AYHAN<sup>2</sup>, Engin BOZKURT<sup>1</sup>

**Abstract:** Coronary artery anomaly is a rare but important condition, especially when an intervention is required. If the observer does not consider the possible presence of a coronary artery anomaly during coronary angiography or cardiac multislice/multidetector-row computed tomography (MDCT), these anomalies can be overlooked. Herein, we present a case with a type IV dual left anterior descending coronary artery anomaly detected with MDCT.

**Key words:** Dual left anterior descending coronary artery, multidetector computed tomography

### Çok kesitli bilgisayarlı tomografi ile saptanan tip 4 çift sol ön inen koroner arter vakası

**Özet:** Koroner arter anomalisi nadir fakat, özellikle girişim gerektiğinde, önemli bir durumdur. Koroner anjiyografi veya çok kesitli bilgisayarlı tomografi (ÇKBT) sırasında eğer gözlemci muhtemel koroner arter anomalisi varlığını düşünmezse bu anomalileri gözden kaçırabilir. Biz burada ÇKBT ile saptanan tip 4 çift sol ön inen koroner arterli bir vakayı sunduk.

**Anahtar sözcükler:** Çift sol ön inen koroner arter, çok kesitli bilgisayarlı tomografi

### Introduction

Dual left anterior descending coronary artery (or dual anterior interventricular artery) is a rare coronary artery anomaly. It is important to know the anatomical variants of this anomaly in patients with coronary artery disease who are undergoing either surgical myocardial revascularization or coronary angioplasty. Herein, we report a case with both a native left anterior descending (LAD) coronary artery and an anomalous LAD coronary artery originating from the right sinus of Valsalva.

### Case

A 42-year-old male patient was referred to our hospital with left leg pain after walking about 100 m. The arterial pulse was diminished in the left femoral artery. Laboratory findings were unremarkable for the risk of coronary artery disease. Only smoking was a risk factor in

Received: 27.02.2011 – Accepted: 24.04.2011

<sup>1</sup> Department of Cardiology, Faculty of Medicine, Yıldırım Beyazıt University, Ankara - TURKEY

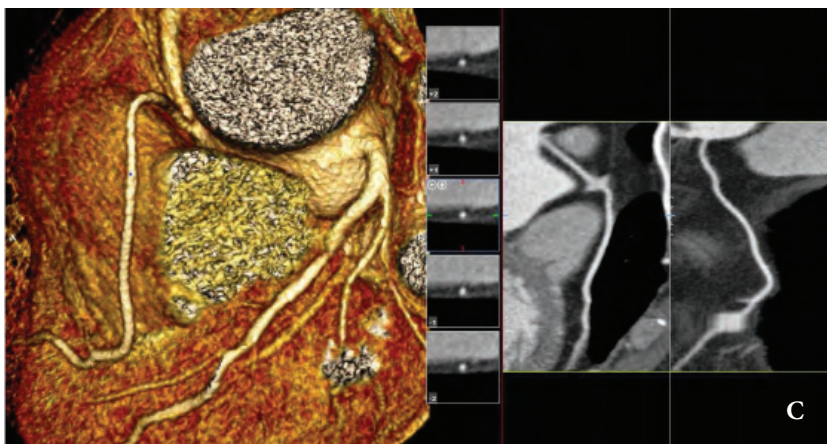
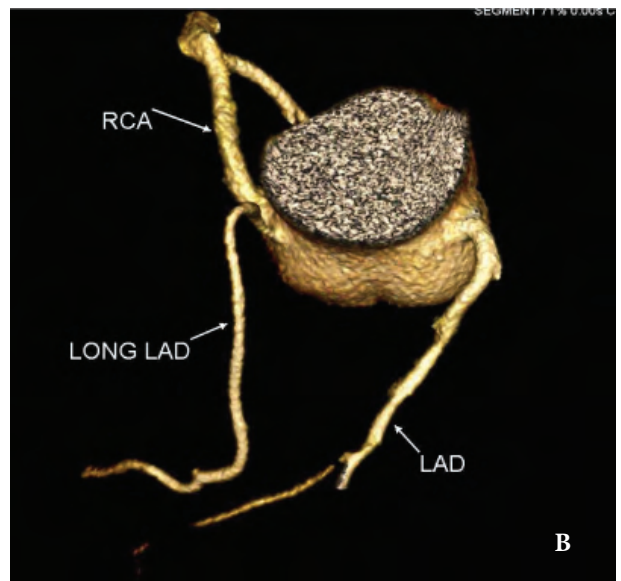
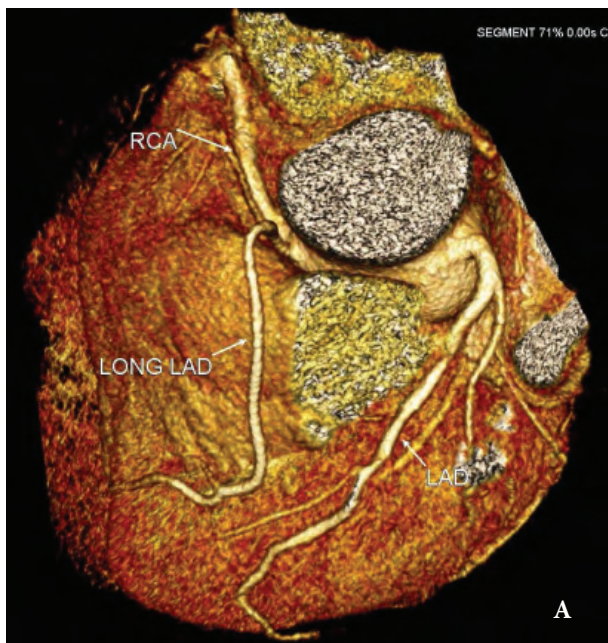
<sup>2</sup> Department of Cardiology, Atatürk Education and Research Hospital, Ankara - TURKEY

<sup>3</sup> Department of Radiology, Atatürk Education and Research Hospital, Ankara - TURKEY

**Correspondence:** Hüseyin AYHAN, Department of Cardiology, Atatürk Education and Research Hospital, Ankara - TURKEY  
E-mail: huseyinayhan44@yahoo.com

his history (1 pack a day for 20 years). Doppler ultrasound revealed advanced stenosis (>70%) with irregularity of the arterial walls of the bilateral iliac arteries. Digital subtraction angiography (DSA) showed significant stenosis (90%) in the left common iliac artery. We planned a cardiac 64-slice multidetector-row computed tomography (MDCT) study prior to the stenting of the left common iliac artery. The MDCT showed a normally appearing but shortly ending LAD artery originating from the left main coronary artery and an anomalous long

LAD arising from the right sinus of Valsalva. Upon reviewing the literature, we saw that the MDCT findings were consistent with a dual LAD artery, one of the branches of which arose from the right sinus of Valsalva (Figures 1A-1C). There was no additional pathological finding and the coronary calcium score was 0. A self-expandable stent was then implanted successfully into the left common iliac artery. The stent was patent after a 4-month follow-up with digital subtraction angiography.



Figures 1A-1C. Cardiac 64-slice multidetector-row computed tomography showing a normal short LAD artery originating from the left main coronary artery and an anomalous long LAD artery arising from the right sinus of Valsalva.

## Discussion

The most common coronary artery anomaly, constituting approximately one-third of all major coronary artery anomalies, is the origin of the left circumflex artery from the right coronary artery. Another coronary artery anomaly is the origin of the left main coronary artery from the right sinus of Valsalva. This is a life-threatening and less common situation, accounting for 1%-2% of the major coronary artery anomalies. Duplication of the LAD artery has been reported at rates of 0.13%-1% in the general population. However, it is found in 4%-5% of cases with tetralogy of Fallot (1,2). These anomalies are often determined during coronary angiography. They may, however, be more often encountered during MDCT. The LAD artery normally originates from the left main coronary artery, coursing in the anterior interventricular groove toward the cardiac apex. It gives diagonal branches to the anterior wall of the left ventricle and septal perforators to the interventricular septum. A dual LAD artery is characterized by a short LAD artery that terminates prematurely in the anterior interventricular groove and a long LAD artery with a proximal course outside the anterior interventricular groove, returning to the groove at the end of its distal course. In the largest series of cases with dual LAD arteries (3), the prevalence was estimated to be 1% (23 cases in 2140 subjects). A total of 4 subtypes have been described (3). In types 1 and 2, a long LAD artery originates as a branch from the proper LAD artery, follows a course parallel to the short LAD artery in its proximal course on either the left (type 1) or the right (type 2) ventricle, and reenters the end of anterior interventricular groove. Type 3 dual LAD arteries are extremely rare and were detected in only 1 of the 23 cases of dual LAD arteries in an angiographic series described by Spindola-Franco et al. (3). A type 3 dual LAD artery is characterized by a proximal intramyocardial course

of the long LAD artery. A type 4 dual LAD artery is a distinct type in which the long LAD artery originates from the right coronary artery and enters the anterior interventricular groove. In our case, we observed a normally appearing LAD artery originating from the left main coronary artery. It traveled through the interventricular groove toward the cardiac apex. The other anomalous LAD artery originated from the right sinus of Valsalva (type 4 dual LAD artery).

The LAD artery is the most important coronary artery in coronary artery bypass graft surgery. MDCT is a relatively noninvasive method for evaluating coronary arteries. It is also very useful for detecting coronary artery anomalies. Before an operation or intervention, coronary arterial anatomy may be shown using MDCT for mild-to-moderate risk patients for atherosclerosis. Radiologists should be aware of the possibility of duplication of the LAD artery during interpretation of coronary MDCTs. Therefore, the interpreter can warn the cardiac surgeon about the importance of achieving successful myocardial revascularization by avoiding the risk of incorrect placement of the arteriotomy (4). Duplication of the LAD artery, an LAD artery with a diagonal branch running parallel to it, should not be confused with a dual LAD artery. Such a parallel diagonal branch does not reenter the anterior interventricular groove and takes over the course of the distal LAD artery, as does the long anterior LAD artery (5).

## Conclusion

In the case reported here, we detected a rare coronary anomaly without atherosclerotic involvement. Invasive coronary angiography was not performed for determining coronary artery disease before intervention. Both cardiologists and radiologists should be aware of these coronary artery anomalies, and, if there is suspicion of a coronary anomaly, they should evaluate the situation together.

## References

1. Sajja LR, Farooqi A, Shaik MS, Yarlagadda RB, Baruah DK, Pothineni RB. Dual left anterior descending coronary artery: surgical revascularization in 4 patients. *Tex Heart Inst J* 2000; 27: 292-6.
2. Dilawar M. Dual left anterior descending coronary artery. *Heart Views* 2010; 11: 67.
3. Spindola-Franco H, Grose R, Solomon N. Dual left anterior descending coronary artery: angiographic description of important variants and surgical implications. *Am Heart J* 1983; 105: 445-55.
4. Yoshikai M, Kamohara K, Fumoto H, Kawasaki H. Dual left anterior descending coronary artery: report of a case. *Surg Today* 2004; 34: 453-5.
5. Paulin S. Coronary angiography: a technical, anatomic and clinical study. Chap VI. The left coronary artery. *Acta Radiol Diagn (Stockh)* 1964; 54 (Suppl. 233): L+.