

## Outcomes in 12 gynecologic cancer patients with brain metastasis: a single center's experience

Esra ÇABUK CÖMERT<sup>1</sup>, Tevfik Berk BİLDACI<sup>1</sup>, Burcu KISA KARAKAYA<sup>1</sup>, Nefise Çağla TARHAN<sup>2</sup>,  
Özlem ÖZEN<sup>3</sup>, Salih GÜLŞEN<sup>4</sup>, Polat DURSUN<sup>1</sup>, Ali AYHAN<sup>1</sup>

**Aim:** To present 12 gynecologic cancer cases with brain metastasis and a discussion of the relevant literature. Gynecologic malignancy is the second most common cancer in elderly women, following breast cancer. These cancers usually spread locally at first, and common distant metastatic sites are the lungs, liver, spleen, and distant lymph nodes. The brain is not a usual site of metastatic involvement.

**Materials and methods:** The study included 12 cases with various gynecologic malignancies that were retrospectively analyzed. Therapeutic modalities, survival, and time between initial surgery and brain metastasis were recorded.

**Results:** The mean survival was 41.4 months in 6 patients with ovarian cancer versus 27.7 months in those with other gynecological cancers. At the time of brain metastasis, the CA-125 level was elevated in all of the patients, except one that had cervical cancer. The mean CA-125 level was 202 IU mL<sup>-1</sup>. There were no differences in the mean overall survival between the patients that underwent surgical resection and those that received medical treatment.

**Conclusion:** Brain metastasis can occur in all gynecologic cancers and has a poor prognosis, despite multimodal treatment.

**Key words:** Gynecologic cancers, brain metastasis, ovarian carcinoma, cervical carcinoma, endometrial carcinoma

### Kranial metastazı olan 12 jinekolojik onkoloji hastasının klinik gidişatı: Tek merkez deneyimi

**Amaç:** İleri yaş bayan hastalarda, jinekolojik malignansiler; meme kanserinden sonra en sık gözüken ikinci kanserlerdir. Bu kanserler ilk olarak lokal yayılmaktadır ancak uzak metastazı akciğer, karaciğer, dalak ve lenf nodlarıdır. Beyin olağan metastaz yeri değildir. Bu çalışmadaki amacımız jinekolojik kanserle takip edilen 12 hastanın beyin metastazını literatür bilgisiyle beraber değerlendirmektir.

**Yöntem ve gereç:** Farklı jinekolojik kanser tanısı alan 12 hasta retrospektif olarak araştırıldı. Terapötik modaliteler, yaşam süreleri, başlangıç cerrahisi zamanından; beyin metastazı olana kadar süredeki klinik gidişatları, CA-125 düzeyleri değerlendirildi.

**Bulgular:** Over kanseri ile takip edilen 6 hastanın ortalama yaşam süresi 41,4 aydı. Diğer jinekolojik kanserlerdeki ortalama yaşam süresi ise 27,7 aydı. Servikal kanserler hariç CA-125 değeri beyin metastazı olduğu zaman yüksek seyretmekteydi. CA-125: 202 IU mL<sup>-1</sup> idi. Beyin metastazı olduktan sonra yapılan cerrahi girişim veya verilen medikal tedavi arasında fark olmadığı saptanmıştır.

**Sonuç:** Beyin metastazı tüm jinekolojik onkoloji kanserlerinde gözükebilir ve de yapılan multimodal tedavi yaklaşımlarına rağmen kötü prognoza sahiptir.

**Anahtar sözcükler:** Jinekolojik kanserler, beyin metastazı, over kanseri, servikal kanser, endometrial kanser

Received: 06.01.2011 – Accepted: 15.04.2011

<sup>1</sup> Department of Obstetrics and Gynecology, Faculty of Medicine, Başkent University, Ankara - TURKEY

<sup>2</sup> Department of Radiology, Faculty of Medicine, Başkent University, Ankara - TURKEY

<sup>3</sup> Department of Pathology, Faculty of Medicine, Başkent University, Ankara - TURKEY

<sup>4</sup> Department of Neurosurgery, Faculty of Medicine, Başkent University, Ankara - TURKEY

**Correspondence:** Esra ÇABUK CÖMERT, Department of Obstetrics and Gynecology, Faculty of Medicine, Başkent University, Ankara - TURKEY  
E-mail: esracab@hotmail.com

## Introduction

Brain metastasis is common in patients with leukemia, lymphoma, lung cancer, and breast cancer; however, metastasis to the brain in patients with gynecologic malignancies is uncommon, except in choriocarcinoma (1,2). Epithelial ovarian carcinoma (EOC), which is one of the most common gynecologic malignancies, has clinical characteristics similar to those of primary peritoneal carcinoma (PPC) (3). Brain metastasis in EOC and PPC cases is rare, usually present as a late manifestation in patients with prolonged survival. The incidence of brain metastasis in EOC ranges from 0.29% to 5% (4-7). Only 2 cases of primary peritoneal adenocarcinoma metastasis to the brain have been published (8,9). Endometrial adenocarcinoma is the most common gynecologic malignancy and has a low incidence of metastasis to the brain, ranging from 0.3% to 1.4% (10,11).

Metastatic disease to the central nervous system (CNS) from other gynecological malignancies, such as cervical cancer, uterine sarcomas, and vulvar cancer, is extremely rare. For example, only a few reports of brain metastasis in vulvar carcinoma patients have been published in the English-language literature (12,13). Herein, we report the radiological findings, treatment modalities, outcomes, and survival of 12 gynecological cancer patients with metastasis to the brain that were treated between 2007 and 2010 at the Başkent University Department of Gynecologic Oncology.

## Materials and methods

This retrospective study included gynecological cancer patients with metastasis to the brain that were treated at Başkent University between January 2007 and January 2010. The retrospective design of the study eliminated the necessity of ethical committee approval. Pathologic classification of the cancers, treatment regimens, time from onset of disease to detection of brain metastasis, extracranial metastasis and time of occurrence, changes in the CA-125 level, and overall survival (OS) are provided, along with brain imaging findings. Additionally, survival and factors involved in prognosis are discussed. SPSS 17 was used for statistical analysis. Dichotomous variables were analyzed using the chi-square test and numeric variables were analyzed using the t-test.  $P < 0.05$  was considered statistically significant.

## Results

### Ovarian carcinoma

Among 435 patients with EOC, 6 (1.4%) (mean age: 60 years; range: 45-74 years) developed brain metastasis. In all, 5 of these 6 patients had serous adenocarcinoma and 1 had clear cell adenocarcinoma. All 6 patients underwent cytoreductive surgery, performed by an experienced gynecologic oncology team. All 5 patients with serous adenocarcinoma had stage IV cancer, and they received paclitaxel and carboplatin as first-line chemotherapy. Only 1 of the serous adenocarcinoma patients achieved remission without recurrence during the 12 months of follow-up; the 5 other patients had disease-free survival (DFS) of 6 months. Other chemotherapeutic agents, including liposomal doxorubicin, gemcitabine, topotecan, weekly paclitaxel, and oral tamoxifen, were used one by one in the mentioned order until recurrence occurred or an increase in CA-125 was observed.

The mean Ca-125 level was 249 IU mL<sup>-1</sup> (range: 2-735 IU mL<sup>-1</sup>) at the time that CNS metastasis was noted. The mean survival after cytoreduction in the stage IV cancer patients was 41.9 months (range: 27-79 months); following brain metastasis, the mean survival was limited to 2.92 months (range: 0-6 months), regardless of the therapy used. Three patients that underwent surgical resection due to cranial metastasis had OS of 3.3 months following surgery. The other 3 patients opted for medical treatment and had OS of 2.2 months. Among the 3 patients that were surgically treated, 1 had cranial recurrence and again underwent surgery. The difference between treatment regimens was not significant ( $P = 0.605$ ). Results in the patients with stage III cancer were similar; OS was 39 and 2 months following diagnosis and surgical resection, respectively (Table).

### Other gynecologic malignancies

In all, 247 patients with endometrial cancer underwent various surgical and medical treatments during the study period, and 2 developed brain metastasis (0.8%); histopathological types were endometrioid and serous papillary adenocarcinoma. Both patients underwent initial staging and cytoreductive surgery. The patient with serous papillary cancer was stage IB, grade 3, and the patient with an endometrioid

Table. Features of patients with gynecological cancers that metastasized to brain.

Type of gynecological malignancies	Number of sites involved in CNS	Operation status	Radiotherapy status for brain metastasis	Interval between initial and second diagnosis / Survival after brain metastasis
Patient A: Ovarian serous carcinoma	2 sites	NA	NA	34 m / 4 m
Patient B: Ovarian serous carcinoma	1 site	Operated	RT	26 m / 9 m (alive)
Patient C: Ovarian serous carcinoma	2 sites	Operated	RT	72 m / 6 m
Patient D: Ovarian serous carcinoma	2 sites	Operated	RT	28 m / 4 m
Patient E: Ovarian serous carcinoma	1 site	NA	NA	36 m / 7 d
Patient F: Ovarian clear cell carcinoma	4 sites	NA	NA	35 m / 2 m
Malignant mixed müllerian tumor	2 sites	NA	NA	5 m / 2 m
Endometrial carcinoma (endometrioid)	2 sites	Only biopsy	RT	29 m / 30 m (alive)
Endometrial carcinoma (serous)	1 site	NA	NA	2 m / 5 m
Primary peritoneal carcinoma	3 sites	NA	NA	13 m / 2 m
Cervical carcinoma	1 site	Operated	RT	4 m / 1 m
Vulvar carcinoma	4 sites	NA	NA	36 m / 12 d

\*NA: not applicable, RT: radiotherapy, m: months, d: days

tumor was stage IIIA, grade 3. Both patients received 6 cycles of paclitaxel and carboplatin (175 mg m<sup>-2</sup> dose for paclitaxel and AUC 5 dose for carboplatin) following cytoreduction. Metastatic disease to the brain occurred with synchronous disseminated abdominal spread in both patients. Elevated CA-125 was observed in these 2 patients (163 IU mL<sup>-1</sup>) at the time that CNS involvement was noted.

During the study period, we treated 10 malignant mixed müllerian tumor (MMMT) patients; 1 patient had stage 4 disease and developed brain metastasis 4 months after initiation of cisplatin and liposomal doxorubicin. Imaging methods, including abdominal and thoracic tomography, showed concomitant lung metastasis and disseminated abdominal spread. Survival following brain metastasis was only 3 months (Table).

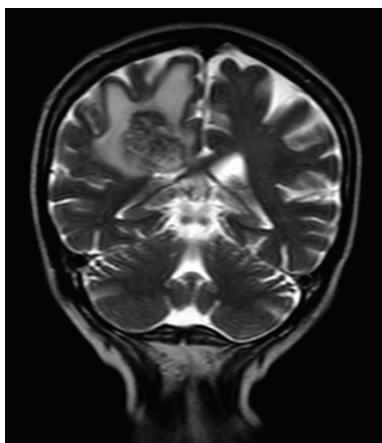
Of the 172 patients with cervical carcinoma treated during the study period, 1 developed cranial metastasis; the patient underwent type-3 hysterectomy and bilateral pelvic and paraaortic lymph node dissection following 28 days of chemoradiation with 6 cycles of platin-based chemotherapy. Histopathological evaluation showed both pelvic and paraaortic lymph nodes consistent with clear cell adenocarcinoma. DFS was 24 months prior to the occurrence of brain metastasis, after which time the patient survived for 1 month (Table).

Of the 28 patients with PPC, 1 had brain metastasis during the study period. The treatment administered to this patient was similar to that given to EOC patients; following cytoreductive surgery, chemotherapy consisting of paclitaxel and carboplatin was administered. DFS was 6 months

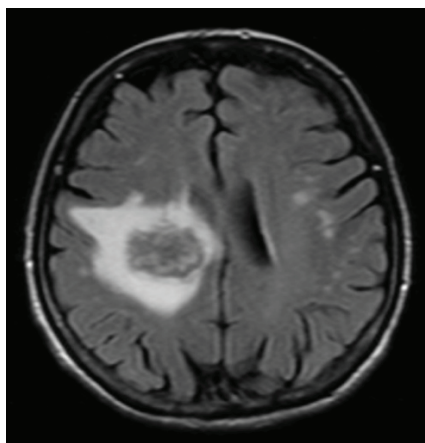
prior to recurrence. Although the time between the initiation of the therapy and brain metastasis was 13 months, survival after brain metastasis was 1.5 months. Among the 37 patients with vulvar carcinoma, 1 had brain metastasis (squamous cell adenocarcinoma). The patient first underwent surgery at another hospital in 2006, but following recurrence in 2007, vulvectomy and bilateral inguinal lymph node dissection were performed at our hospital. This patient was stage III (FIGO). She received 5000 cGy of pelvic radiotherapy concomitant with 3 cycles of cisplatin and doxorubicin. DFS before brain metastasis was 2.3 months; survival after brain metastasis was less than 1 month.

### Clinical imaging

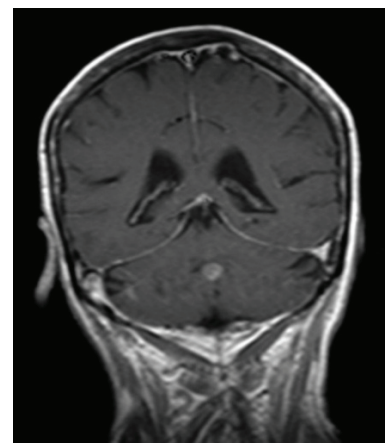
The brain metastases observed in the present study were associated with such clinical manifestations as headache, nausea, vomiting, tinnitus, unconsciousness, dizziness, loss of extremity movement, and ptosis. In most of the patients, metastatic disease was diagnosed via magnetic resonance imaging (MRI). Figures 1 and 2 show different brain metastasis sites of the patients. Figures 3 shows histopathologic images of brain metastasis from different patients. Figures 1 and 2 clearly show that the location of metastatic spread varied (temporal, parietal, frontal lobe, and cerebellum).



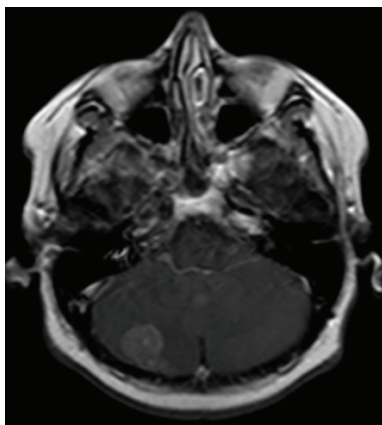
i) Right parietal lobe involvement on coronal section of patient A.



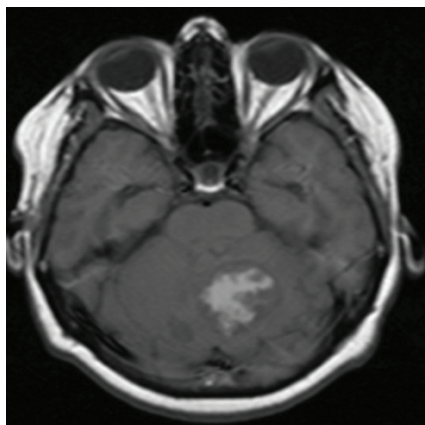
ii) Right parietal lobe involvement on transverse section of patient A.



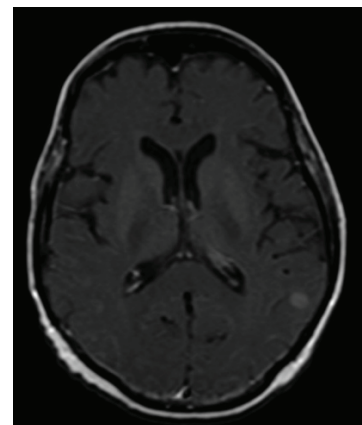
iii) Cerebellar involvement on coronal section of patient B.



iv) Cerebellar infiltration on transverse section of patient C.

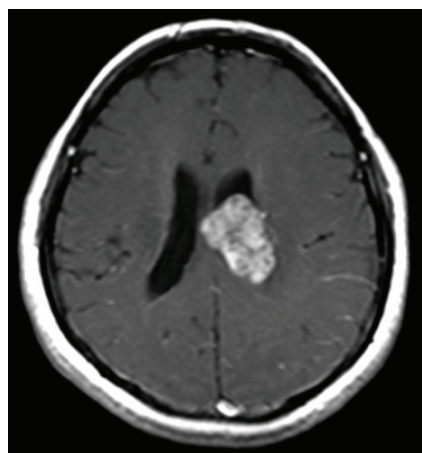


v) Occipital lobe involvement on transverse section of patient C.

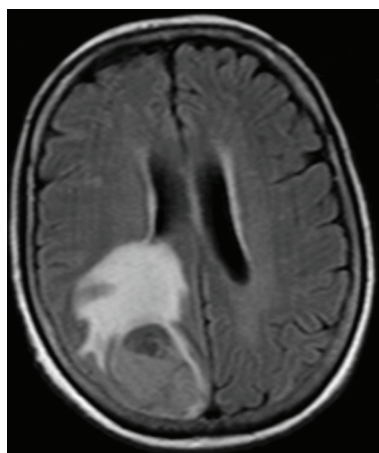


vi) Left temporoparietal lobe involvement of patient D.

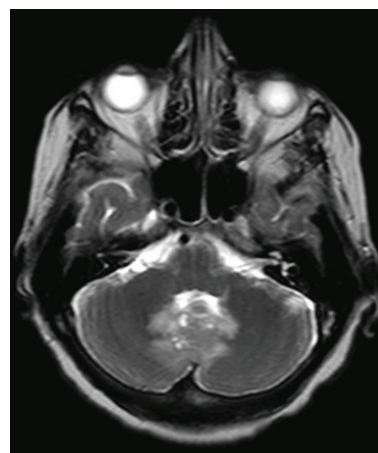
Figure 1. Metastasis at different sites with different (coronal and transverse) sections from ovarian cancer patients.



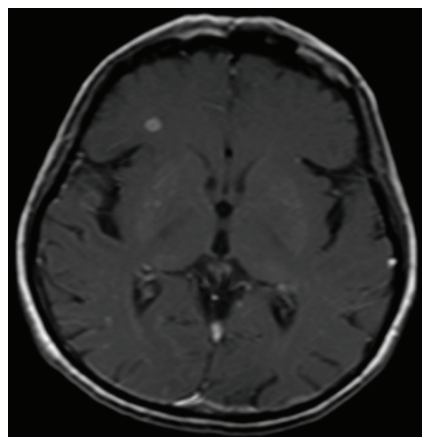
i) Left lateral ventricle involvement on transverse section MMMT.



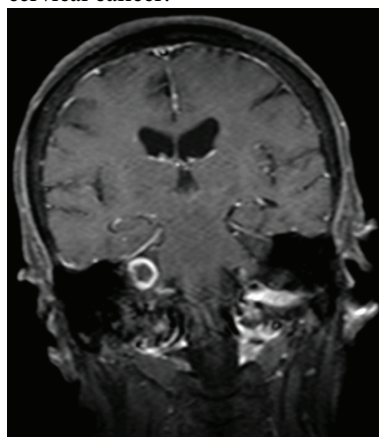
ii) Right occipito parietal lobe involvement on transverse section, cervical cancer.



iii) Cerebellar involvement on coronal section, vulvar carcinoma.



iv) Right frontal, left parietal lobe involvement on transverse section, primary peritoneal cancer.



v) Cerebellar involvement on coronal section, endometrial cancer.

Figure 2. Imaging of brain metastasis in other gynecologic malignancies.

While single intracranial metastasis occurred in 3 patients, multiple intracranial metastases occurred in 9 patients. In 2 patients with ovarian cancer, 1 with cervical cancer, and 1 with endometrial cancer, there was no recurrence other than brain involvement based on abdominal and thoracic screening. The other patients had multiple abdominal metastases. In all, 1 patient with single metastasis and 4 with multiple intracranial metastases underwent intracranial focus resection followed by radiotherapy. Among the 5 patients that received radiation treatment, only 1 also received chemotherapy. There were no differences in the mean OS between the patients with brain metastases that underwent surgical resection,

medical therapy, and radiotherapy ( $P = 0.859$ ), which was 2.2 months for all of the 12 patients. The patient with endometrial cancer and multiple intracranial metastases underwent stereotaxic biopsy following gamma-knife radiotherapy and was still alive 19 months after treatment. In total, 4 patients with multiple intracranial metastases and 3 with single intracranial metastasis were given palliative therapy.

### Discussion

The incidence of brain metastasis in clinical series of gynecological cancers is approximately 1% (14,15). In the present study, 6 of 435 patients with EOC developed

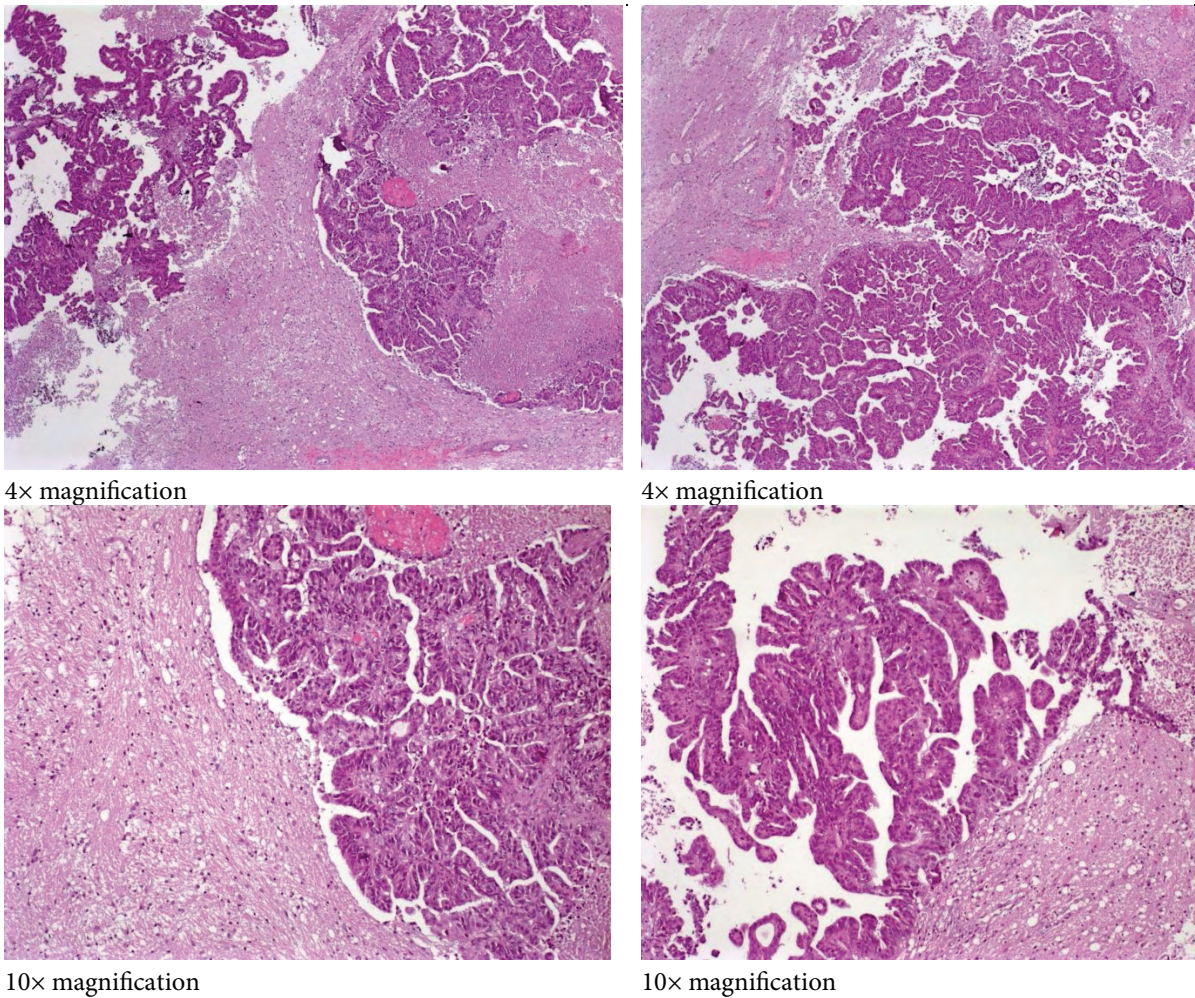


Figure 3. Histopathologic images of brain metastasis from different types of patients with different magnification values.

brain metastasis (1.3%). The mean age of patients with EOC and brain metastasis varied from 50.4 to 59.3 years (range: 19-77 years) in different studies, and 3% of these patients were stage III and IV (16). In the present study, 6 patients with EOC had serous adenocarcinoma, the most frequently encountered type, which is similar to previous findings (16). The mean age of these 6 patients was 60 years (range: 45-74 year); all but 1 had advanced-stage disease (stage III and IV), 5 had serous adenocarcinoma, and 1 had clear cell adenocarcinoma.

The current standard treatment for EOC of all histological subtypes involves primary optimal debulking surgery followed by cisplatin-based chemotherapy. It is well known that almost all

patients with EOC receive chemotherapy after initial diagnosis. Some researchers have suggested that the increased incidence of brain metastasis in EOC is related to the effectiveness of chemotherapy (15) or that cisplatin-based chemotherapy may contribute to an increase in the incidence of CNS involvement (4,14,17). The blood-brain barrier (BBB) is thought to limit delivery of large-in-size hydrophilic drugs to the brain, determining which agents and doses will be used (14). Additionally, some researchers think that improvement in the efficacy of chemotherapy delays recurrence in the abdominal and pelvic cavity, but that the BBB blocks water-soluble cisplatin and lowers the concentration in the CNS, increasing the incidence of brain metastasis (18).

Brain metastasis usually occurs in patients with longer survivals. The maximum time from diagnosis of EOC to brain metastasis was 98 months, and the longest survival period after brain metastasis was 7 years (19,20). Tay and Rajesh reported that median survival after brain metastasis was 19.5 months, whereas Chen et al. reported that the mean time from initial diagnosis of EOC to brain metastasis was 24.3 months and median survival after the discovery of CNS involvement was 3 months (21,22). In the present study, the mean survival after cytoreduction in stage III-IV cancer patients was 41.9 months (range: 27-79 months), and after brain metastasis was detected, mean survival was limited to 2.92 months (range: 0-6 months), regardless of treatment. Tay et al. suggested that monitoring tumor recurrence based on the serum CA-125 level does not predict metastasis to the brain, as only 1 of 4 cases had elevated CA-125 at the time brain metastasis was diagnosed (21). All of the EOC patients with brain metastasis in the present study had elevated CA-125 (mean: 249 IU mL<sup>-1</sup>; range: 44-735 IU mL<sup>-1</sup>), as might occur in cases of recurrence in other regions of the body.

The prognosis of patients with brain metastasis is generally very poor without adjuvant treatment, ranging from none to a few months of survival (20-23). The aim of treatment in patients with brain metastasis should be the control of neurological symptoms and improvement of the quality of life. There are various treatment strategies, including corticosteroids, whole-brain radiotherapy (WBRT), surgery, radiosurgery, and chemotherapy. WBRT is the treatment of choice for most patients with brain metastasis of various malignancies; however, it can cause acute toxicity, such as skin irritation, alopecia, and otitis media. Single metastasis occurs in 43% of patients with EOC; approximately 50% of these patients are not surgical candidates because of extracranial disease or tumor inaccessibility (24). Treating single brain metastasis with surgical resection (with or without WBRT) improves OS (25). Patchell et al. reported that cases of solitary brain metastasis of any histological type treated with surgical excision plus WBRT had longer DFS, longer OS, and longer duration of functional independence compared to those treated with WBRT alone (26). In patients with limited intracranial tumors, focal therapeutic modalities such as gamma-knife

radiosurgery (GKS) may replace WBRT or surgery, which delivers high-dose focal radiation and induces tumor necrosis while delivering minimal radiation to the surrounding normal brain tissue (23,25). In all, 3 patients in the present study underwent surgical resection following WBRT. Patients that were not treated for metastatic disease because of their medical condition had 2 months of OS, whereas those that underwent surgical resection and radiotherapy had 5 months of OS, and 1 patient was still alive 8 months after the detection of CNS involvement.

### Other types of gynecologic malignancies

Few case reports and studies describe patients with endometrial carcinoma and brain metastasis (11). The incidence of brain metastasis from endometrial carcinoma ranges from 0.3% to 1.4% (10,11). The primary mechanism of spread was suggested to be dissemination to the lungs and to the brain via the pulmonary vasculature (27,28). Many studies report that brain metastasis in endometrial cancer is usually associated with widespread disease, as in 2 patients in the present study (29,30). Advanced stage, high grade, invasion of the lymphovascular space, and deep myometrial invasion are associated with brain metastasis (10,27,30,31). Tumor grade and deep myometrial invasion were correlated in the present study. The mean interval between diagnosis of primary tumor and CNS involvement ranges from 0 to 52 months (10,28,32,33). These results seem to be compatible with our study, as 15.5 months was our time interval for CNS involvement to be found. In the present study, the mean OS after the diagnosis of brain metastasis was 17.5 months (1 patient was still alive when this report was written). In contrast, 2 patients treated with surgical resection following radiotherapy had long-term OS (82 and 83 months) after the development of brain metastasis (10,33). In the present study, 1 of the patients was still alive (at the time this report was written) 30 months after stereotaxic biopsy following GKS. Chura et al. (34) reported that survival in patients treated with multimodal therapy (WBRT plus surgery, WBRT plus chemotherapy, or WBRT plus surgery and chemotherapy) was longer than in patients treated with WBRT only ( $P = 0.0001$ ) and in patients that received no treatment ( $P = 0.009$ ); no difference in OS was observed between the patients treated with

WBRT only and those not treated. Other studies also support the survival advantage associated with multimodal therapy (10,32).

Brain metastasis from a MMMT of the uterus is very rare. To date, 4 cases of CNS involvement with MMMT metastasis have been reported (35,36). The pathological stage at diagnosis seems to be the most reliable predictor of prognosis in MMMTs of uterine origin (36). Surgical excision is considered the most effective treatment, whereas radiotherapy and various combinations of chemotherapy have achieved inconsistent results. However, Wong et al. observed that patients with MMMT of the uterus that received sequential adjuvant therapy, namely cisplatin and ifosfamide chemotherapy and radiotherapy, had longer survival compared with the control group without any adjuvant therapy (37). The 4 cases mentioned above had mean survival times of 2 months after the detection of brain metastasis; complete tumor resection or cranial radiotherapy alone did not provide a good prognosis (35,36,38). Even though surgical resection or other mentioned therapies were not an option for the patient with MMMT in the present study because of her poor medical condition, OS after CNS involvement was 2 months. Based on the limited data in the literature, it is thought that a poor prognosis in MMMT patients with brain metastasis is unavoidable.

Brain metastasis from cervical cancer occurs in 0.4%-1.2% of patients (39,40). The mean OS after initial diagnosis of cervical cancer was 19.2 months and the mean survival after diagnosis of brain metastasis ranged from 3 to 8 months (39-41). The treatment of brain metastasis usually involves radiation therapy, surgery, or both, depending on each patient's clinical picture. Generally, surgical excision is used in cases with a solitary lesion or adjacent multiple metastases. Patients with nonadjacent, multiple, or inoperable lesions are usually treated with palliative WBRT

(39,41). In the present study's patient, the time from initial diagnosis to multiple metastatic CNS involvement was 4 months; nevertheless, survival was only 1 month after the discovery of brain metastasis. Though WBRT was planned, due to the patient's poor medical condition she was given paclitaxel and carboplatin combination chemotherapy.

Brain metastasis from EOC and PPC is considered a rare occurrence. In a series of 24 patients (23 with EOC and 1 with PPC), Ratner et al. reported that OS was 37 months (42). In the present study, there was a significant difference in survival between EOC and PPC patients; OS in the EOC patients was 41.9 months versus 15 months in the PPC patients. On the other hand, there was a small difference in survival after brain metastasis between the EOC and PPC patients (2.92 and 2 months, respectively), which was also reported by Ratner et al. (42). Surgical resection of cranial mass was not performed due to the patient's medical condition. As in EOC, survival following brain metastasis in PPC is limited.

Distant spread occurs in 8%-12% of patients with vulvar carcinomas. To date, brain metastasis from vulvar carcinoma has been reported in only 4 cases with different histopathological features. Our patient had squamous cell carcinoma and DFS of 36 months from initial diagnosis to secondary brain metastasis; following brain metastasis, the patient survived for 12 days.

Although gynecologic cancers rarely metastasize to the brain, brain metastasis in such cases has a poor prognosis despite combined treatment modalities. Radiation therapy and surgery are effective in only partially removing masses. Unfortunately, on the basis of the known facts and our experience, chemotherapy, especially paclitaxel and carboplatin, functions only as palliation in such patients. Additional research on other chemotherapy regimens and targeted therapies in such patients with brain metastasis is warranted.

## References

1. Graf AH, Buchberger W, Langmayr H, Schmid KW. Site preference of metastatic tumours of the brain. *Virchows Arch A Pathol Anat* 1988; 412: 493-8.
2. DeAngelis LM. Management of brain metastasis. *Cancer Invest* 1994; 12: 156-65.
3. Killackey MA, Davis AR. Papillary serous carcinoma of the peritoneal surface: matched-case comparison with papillary serous ovarian carcinoma. *Gynecol Oncol* 1993; 51: 171-4.
4. Buzzone M, Campore E, Chiara S, Giudici S, Merlini L, Simoni C et al. Cerebral metastases secondary to ovarian cancer still unusual event. *Gynecol Oncol* 1993; 49: 37-40.



5. Pectasides D, Aravantinos G, Fountzilas G, Kalofonos C, Efstathiou E, Karina M et al. Brain metastases from epithelial ovarian cancer. The Hellenic Cooperative Oncology Group (HeCOG) experience and review of the literature. *Anticancer Res* 2005; 25: 3553-8.
6. Cohen ZR, Suki D, Weinberg JS, Marmor E, Lang FF, Gershenson DM et al. Brain metastases in patients with ovarian carcinoma: prognostic factors and outcomes. *J Neurooncol* 2004; 66: 313-25.
7. Geiser JP, Geiser HE. Brain metastases in epithelial ovarian carcinoma. *Gynecol Oncol* 1995; 57: 246-9.
8. Eltabbakh GH, Piver MS, Werness BA. Primer peritoneal adenocarcinoma metastatic to brain. *Gynecol Oncol* 1997; 66: 160-3.
9. Nalesnik SW, Kost ER, Hines JF, Hall KL. Solitary brain metastasis indicating recurrent primary peritoneal carcinoma. *Obstet Gynecol* 1999; 93: 844.
10. Cormio G, Lissoni A, Losa G, Zanetta G, Pellegrino A, Mangioni C. Brain metastases from endometrial carcinoma. *Gynecol Oncol* 1996; 61: 40-3.
11. Orru S, Lay G, Dessi M, Murtas R, Deidda MA, Amichetti M. Brain metastases from endometrial carcinoma: report of three cases and review of the literature. *Tumori* 2007; 93: 112-7.
12. Dursun P, Ayhan A, Tarhan NC, Coban G, Kuscü E. Cerebellar metastasis in squamous cell vulvar carcinoma. *Arch Gynecol Obstet* 2009; 279: 69-71.
13. Vazques JP, Cobo SL, Anton PM, Asado AC, Vidart JA, Coronado P et al. Brain metastasis and carcinomatous meningitis from vulvar squamous cell carcinoma: case report. *Eur J Gynaecol Oncol* 2007; 28: 154-8.
14. Lassman AB, DeAngelis LM. Brain metastases. *Neurol Clin* 2003; 21: 1-23.
15. Barker GH, Orledge J, Wiltshaw E. Involvement of the central nervous system in patients with ovarian carcinoma. *Br J Obstet Gynaecol* 1981; 88: 690-4.
16. Yang JX, Shen K, Shan Y, Lang JH, Wu M, Guo LN et al. Seven cases of epithelial ovarian carcinoma with brain metastasis. *Chinese Medical Sciences Journal* 2008; 23: 19-22.
17. Lesser GJ. Chemotherapy of cerebral metastases from solid tumors. *Neurosurg Clin N Am* 1996; 7: 527-36.
18. Larson DM, Copeland LJ, Mose RP, Malone JM Jr, Gershenson DM, Wharton JT. Central nervous system metastases in epithelial ovarian carcinoma. *Obstet Gynecol* 1986; 68: 746-50.
19. Smith SC, Koh WJ. Palliative radiation therapy for gynaecological malignancies. *Best Pract Res Clin Obstet Gynaecol* 2001; 15: 265-78.
20. Wen PY, Black PM, Loeffler JS. Treatment of metastatic brain cancer. In: Devita VT Jr, Hellman S, Rosenberg SA, editors. *Principles and practice of oncology*. 6th ed. Philadelphia: Lippincott Williams and Wilkins; 2001. p.2655-70.
21. Tay SK, Rajesh H. Brain metastases from epithelial ovarian cancer. *Int J Gynecol Cancer* 2005; 15: 824-9.
22. Chen YL, Cheng WF, Hsieh CY, Chen CA. Brain metastasis as a late manifestation of ovarian carcinoma. *Eur J Cancer Care* 2011; 20: 44-9.
23. Amita M, Sudeep G, Rekha W, Yogesh K, Hermant T. Brain metastasis from cervical carcinoma – a case report. *Med Gen Med* 2005; 14: 7-26.
24. Mahmoud-Ahmed AS, Suh JH, Barnett GH. Tumor distribution and survival in six patients with brain metastases from cervical carcinoma. *Gynecol Oncol* 2001; 81: 196-99.
25. Buckner J. Surgery, radiation therapy, and chemotherapy for metastatic tumors to the brain. *Curr Opin Oncol* 1992; 4: 518-24.
26. Patchell RA, Tibbs PA, Walsh JW, Dempsey RJ, Maruyama Y, Kryscio RJ et al. A randomized trial of surgery in the treatment of single metastases to the brain. *N Engl J Med* 1990; 322: 494-500.
27. Gien LT, Kwon JS, D'Souza DP, Radwan JS, Hammond JA, Sugimoto AK et al. Brain metastases from endometrial carcinoma: a retrospective study. *Gynecol Oncol* 2004; 93: 524-8.
28. Monaco E 3rd, Kondziolka D, Mongia S, Niranjana A, Flickinger JC, Lunsford LD. Management of brain metastases from ovarian and endometrial carcinoma with stereotactic radiosurgery. *Cancer* 2008; 113: 2610-4.
29. Aalders JC, Abeler V, Kolstand P. Recurrent adenocarcinoma of the endometrium: a clinical and histopathological study of 379 patients. *Gynecol Oncol* 1984; 17: 85-103.
30. Wronski M, Zakowski M, Arbit E, Hoskins WJ, Galicich JH. Endometrial cancer metastasis to brain: report of two cases and a review of the literature. *Surg Neurol* 1993; 39: 355-9.
31. Ruelle A, Zuccarello M, Andrioli G. Brain metastasis from endometrial carcinoma: report of two cases. *Neurosurg Rev* 1994; 17: 83-7.
32. Sewak S, Muggia FM, Zagzag D. Endometrial carcinoma with cerebellar metastasis: a case report and review of the literature. *J Neurooncol* 2002; 58: 137-40.
33. Mariani A, Webb MJ, Keeney GL. Hematogenous dissemination in corpus cancer. *Gynecol Oncol* 2001; 80: 223-8.
34. Chura JC, Marushin R, Boyd A, Ghebre R, Geller MA, Argenta PA. Multimodal therapy improves survival in patients with CNS metastasis from uterine cancers: a retrospective analysis and literature review. *Gynecol Oncol* 2007; 107: 79-85.
35. Mahmoud-Ahmed AS, Suh JH, Barnett GH, Webster KD, Belinson JL, Kennedy AW. The effect of radiation therapy on brain metastases from endometrial carcinoma: a retrospective study. *Gynecol Oncol* 2001; 83: 30-9.
36. N'Kanza AL, Jobanputra S, Farmer P, Lovecchio J, Yelon JA, Rudloff U. Central nervous system involvement from malignant mixed Müllerian tumor (MMMT) of the uterus. *Arch Gynecol Obstet* 2005; 273: 63-8.

37. Wong L, Seen HT, Khootan HS, Low JS, Ng WT, Low JJ. Combined adjuvant cisplatin and ifosfamide chemotherapy and radiotherapy for malignant mixed müllerian tumors of the uterus. *Int J Gynecol Cancer* 2006; 16: 1364-9.
38. Kim JK, Lee SK, Myong HN, Kang YD. Biopsy-proven cerebellar metastasis from a malignant mixed mullerian tumor (MMMT) of the uterus. *Eur J Gynaecol Oncol* 2009; 30: 196-8.
39. Cormio G, Pellegrino A, Landoni F, Regallo M, Zanetta G, Colombo A et al. Brain metastases from cervical carcinoma. *Tumori* 1996; 82: 394-6.
40. Ikeda S, Yamada T, Katsumata N, Hida K, Tanemura K, Tsunematu R et al. Cerebral metastasis in patients with uterine cervical cancer. *Jpn J Clin Oncol* 1998; 28: 27-30.
41. Chura JC, Shukla K, Argenta PA. Brain metastasis from cervical carcinoma. *Int J Gynecol Cancer* 2007; 17: 141-6.
42. Ratner ES, Toy E, O'Malley DM, McAlpine J, Rutherford TJ, Azodi M et al. Brain metastases in epithelial ovarian and primary peritoneal carcinoma. *Int J Gynecol Cancer* 2009; 19: 856-9.