

## Salter innominate osteotomy or Pemberton pericapsular osteotomy in treatment of developmental dysplasia of hip

Naci EZİRMİK<sup>1</sup>, Kadri YILDIZ<sup>2</sup>

**Aim:** We aimed to compare the clinical and radiological results of the Salter innominate osteotomy (SIO) and Pemberton pericapsular osteotomy (PPO) in children with bilateral developmental hip dysplasia who had undergone PPO for 1 side and SIO for the other side in a 1-stage operation.

**Materials and methods:** Children with bilateral hip dysplasia who had undergone PPO for 1 side and SIO for the other side in a 1-stage operation were included in this study, and 126 hips of 63 patients were evaluated. Clinical and radiological results were evaluated and compared using the Sutherland Pain Scale, Modified McKay Grading System, and Trevor Clinical Scoring System.

**Results:** PPO had statistically significantly better femoral head covering than SIO ( $P < 0.05$ ). SIO resulted in better outcomes with respect to range of motion, cervico-diaphyseal angle, and Sharp angle, but the difference between the 2 techniques was not statistically significant ( $P > 0.05$ ).

**Conclusion:** PPO had better outcomes and a lower complication rate than SIO in the treatment of bilateral congenital dysplasia of the hip.

**Key words:** Comparing osteotomies, osteotomy techniques, innominate osteotomy, pericapsular osteotomy

### Introduction

The Salter innominate osteotomy (SIO) and the Pemberton pericapsular osteotomy (PPO) are the 2 most favored techniques for the treatment of developmental dysplasia of the hip (DDH) in patients who are between 2 and 6 years of age. SIO is a complete pelvic osteotomy that can be performed on patients with acetabular indexes (AIs) between 30° and 40° (1,2). PPO is an incomplete osteotomy that can also be performed on patients with anterolateral insufficiencies, patients 2-4 years old with AIs over 40°, or patients 4-6 years old with AIs over 35° (3).

Few articles have been published about the one-stage operation of bilateral DDH (4-7). A single-stage procedure has advantages over 2 consecutive operations, such as reducing overall costs, reducing

the cast duration, and providing a better recovery period. In this study, evaluation of both hips of the same patients operated on with different procedures provided a better comparison of the SIO and PPO procedures.

### Material and methods

This study included 63 patients with bilateral DDH that had undergone PPO for one hip and SIO for the other (Figure 1). All subjects had been operated on by the same senior surgeon between 1993 and 2009 at the Department of Orthopedics and Traumatology of Atatürk University's Medical Faculty. Six of 63 patients were male. Thirty-three patients had undergone PPO for the left hip and 30 for the right. The mean age at the time of surgery was 21.6 months

Received: 16.09.2011 – Accepted: 29.09.2011

<sup>1</sup> Department of Orthopedics and Traumatology, Faculty of Medicine, Atatürk University, Erzurum - TURKEY

<sup>2</sup> Department of Orthopedics and Traumatology, Regional Education and Research Hospital, Erzurum - TURKEY

**Correspondence:** Kadri YILDIZ, Department of Orthopedics and Traumatology, Regional Education and Research Hospital, Erzurum - TURKEY  
E-mail: drkadri1980@hotmail.com

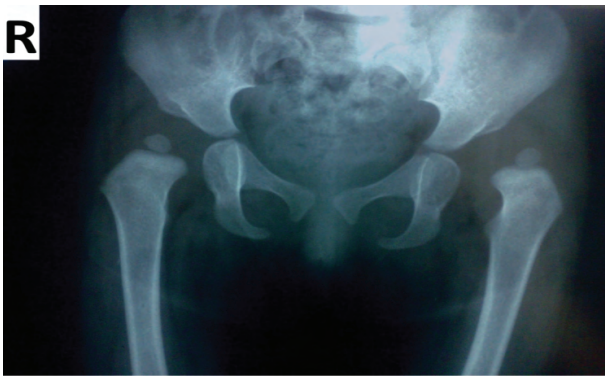

Figure 1. Bilateral developmental dysplasia of the hip: 21-month-old female, 1-stage surgical treatment (right hip: SIO, left hip: PIO).

(range: 15-23 months). The mean follow-up duration was 71.5 months (range: 12 months to 17 years). The mean age at the last follow-up was 7.5 years (range: 23 months to 19 years).

Closed reduction and spica casting had failed for sufficient development of the hip for all patients. Hips with AIs greater than 40° and with anterolateral insufficiencies were operated on with PPO.

The Sutherland Pain Scale, the Modified McKay Grading System, and the Trevor Clinical Scoring System were used for clinical evaluation of the patients. Ranges of motion (ROMs) were evaluated and the presence of limping, superficial infections, and lower limb discrepancies were noted. Presence of avascular necrosis was evaluated according to the Severin Grading System and Kalamchi-McEwen Grading Scale. Direct pelvic X-ray images were taken in order to evaluate the AI, the center-edge (CE) angle, the cervico-diaphyseal angle (CDA), and the Sharp angle.

The mean values, frequencies, and standard deviations were calculated. Chi-square tests and independent samples t-tests were used to compare ordinals; the Mann-Whitney U test and Student's t-test were used to compare nominals. P-values were accepted as significant if less than 0.05.

All costs were covered by the patients themselves or by the national health service. Written and oral informed consent was taken from all of the patients and all hospital records and information were kept confidential.

### Results

All postoperative follow-up and evaluation was carried out by the same surgeon. Direct pelvic X-ray images were carefully assessed in order to calculate the difference in AIs, CE angles, CDAs, and Sharp angles. The mean preoperative, postoperative, and correction degrees for the AIs of the hips with SIO were 33.49° (30°-50°), 15.16° (7°-25°), and 18.33°, respectively. For PPO, the mean preoperative, postoperative, and correction degrees for the AIs of the hips were 37.89° (30°-48°), 12.11° (4°-24°), and 25.78° (Figures 2a and 2b), respectively. This difference between SIO and PPO was statistically significant.

The mean CE angle of the final follow-up was 39.15° (20°-55°) with SIO and 43.11° (29°-57°) with PPO. The mean correction degree of the CE angle was 39.15° with SIO and 43.11° with PPO (Figures 3a and 3b). The mean Sharp angle of the final follow-up (postoperative) was 42.44° with SIO and 41.78° with PPO. With SIO, the mean CDA was 147.64°

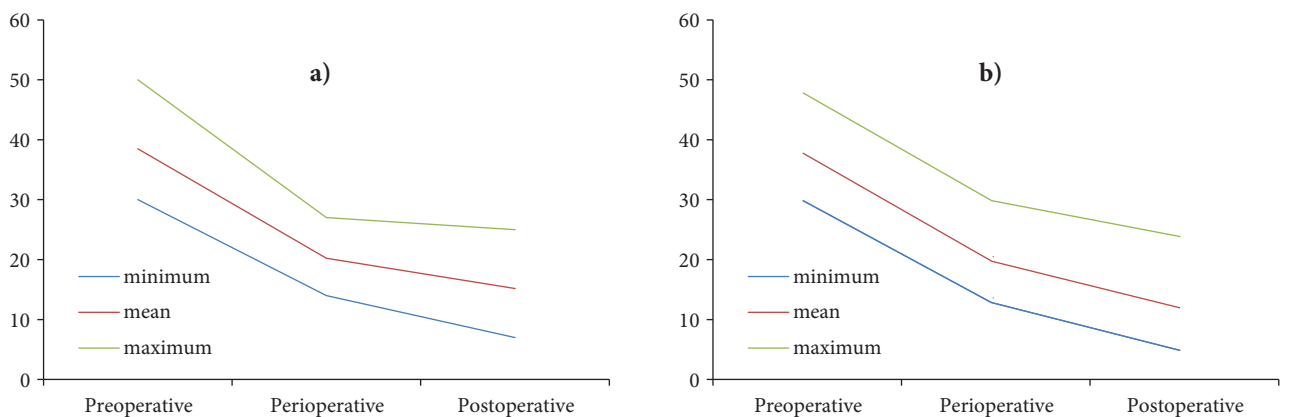


Figure 2. AI mean values for a) SIO and b) PPO.

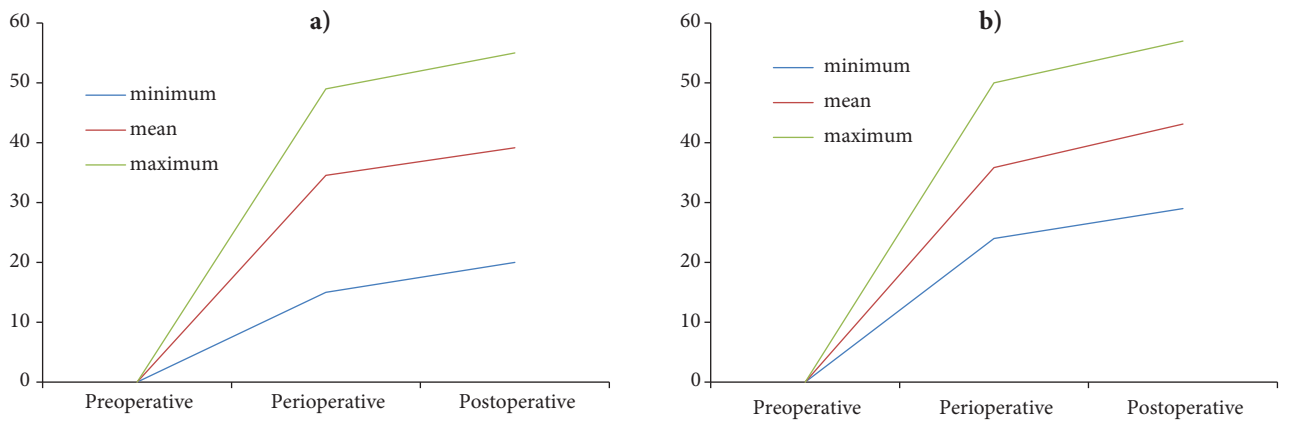


Figure 3. CE angle values for a) SIO and b) PPO.

preoperatively and 138.42° postoperatively, with a mean correction of 9.22°. For PPO, the mean CDA was 147.87° preoperatively and 139.25° postoperatively, with a mean correction of 8.62°.

Long-term outcomes of SIO and PPO were compared. No pain was reported in 92.7% of hips that had received SIO (Figure 4) and in 93.6% hips that had received PPO according to the Sutherland Pain Scale. In hips receiving SIO, 90.9% were evaluated as grade 1 (stable, no pain, no limp, negative Trendelenburg test, full ROM), whereas 91.8% of hips receiving PPO were evaluated as grade 1. Meanwhile, 95.23% of all of the patients that were evaluated had excellent results according to the Trevor Clinical Scoring System. Three patients, 2 of whom received SIO on the positive side, scored positively for the Trendelenburg test.

Superficial infections occurred in 2 hips that received SIO. Figures 5 and 6 present the findings for avascular necrosis (AVN) and femoral head alterations (Figure 5) and other general complications (Figure 6). PPO showed a better degree of correction when compared to SIO ( $P < 0.05$ ), as well as a reduced incidence in AVN. Patients treated with SIO also had a 0.47-cm lengthening of the involved limb. SIO resulted in better improvements in CDA, Sharp angle, and ROM without a statistically significant difference.

**Discussion**

The primary aim of both osteotomy procedures is to sufficiently cover the femoral head, especially in the anterolateral plane, and attain a stable reduction. The

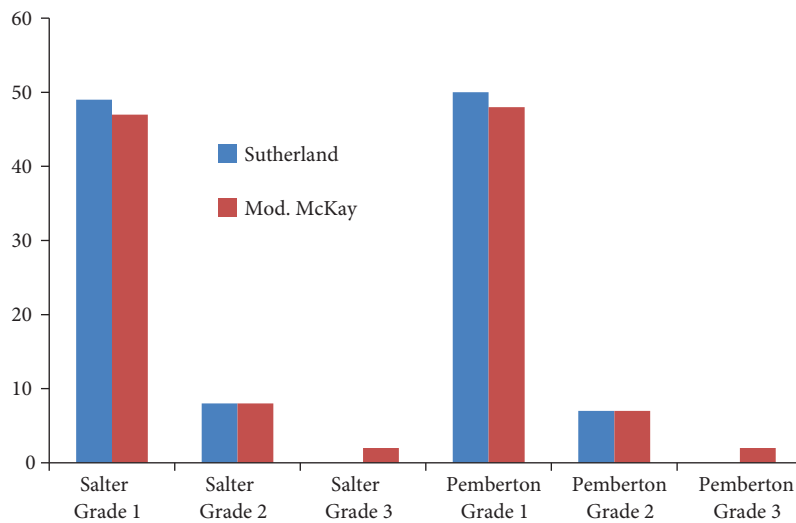


Figure 4. Clinical comparisons.

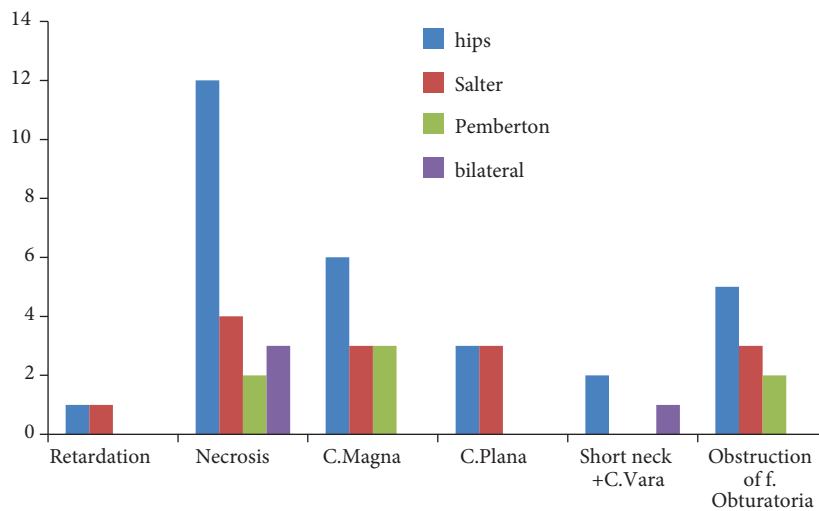


Figure 5. Comparing SIO and PPO techniques and femoral head changes in hips.

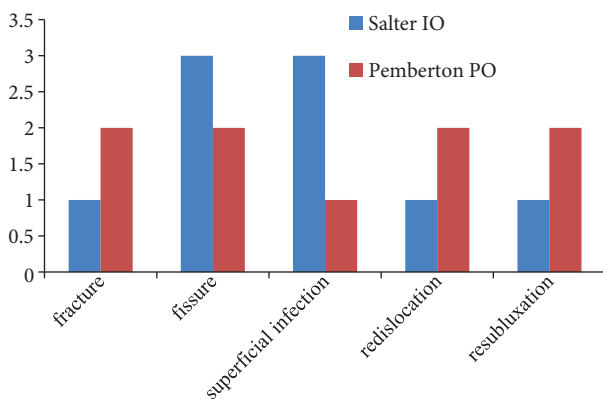


Figure 6. Comparing SIO and PPO techniques and general complications.

AI and CE angles are used to evaluate the sufficiency of femoral head covering (8). Previous studies revealed that the mean AI correction with SIO was between 10° and 23.5° (1,9-11), whereas with PPO it was 5°-35° (5,6,12). In this study, the mean correction degree of the AI was better with PPO, with correction degrees of 18.33° and 25.78° for SIO and PPO, respectively ( $P < 0.05$ ). The mean CE angle with SIO was 37.15°; with PPO, it was 43.11°. The CE angle difference between the 2 techniques was statistically significant (9,10,13,14). The results were compatible with those of previous articles (15-18).

SIO resulted in better improvements in CDA, Sharp angle, and ROM with a statistically insignificant

difference. Better ROM outcomes with SIO were due to more lateral translation in PPO. Out of 126 hips, 16 cases of AVN were noticed. Five of those 16 hips had received PPO, while 11 had the SIO procedure. Coxa magna and coxa vara rates with SIO were twice those of PPO.

Lower limb discrepancy is both a cosmetic and functional problem. Fifty-six of 63 hips with SIO had lower limb lengthening, the mean of which was 0.47 cm. This can be caused by the greater vertical translation with SIO. No other intervention was performed in patients having a discrepancy of less than 1.5 cm (19).

PPO provides better femoral head covering (8) and a better anatomic position of the pelvis than SIO. We did not observe a postoperative decrease of the acetabular volume (3).

The center of the hip moves to a more distal medial and posterior position with SIO. Adductor and flexor muscles of the thigh are stretched and adduction of the hip is limited with SIO. Being an incomplete osteotomy, PPO provides more stability and does not require internal fixation. The success of PPO is provided by the remodeling ability of the acetabulum due to the flexibility of the triradiate cartilage. Greater degrees of correction can be provided by the PPO with fewer degrees of rotation. There is less risk of sciatic nerve and vessel injury with PPO, and the structural alteration of the pelvic bones and the birth canal is reduced.

In orthopedic practice, SIO is performed when the AI is less than 35° and there is less anterolateral insufficiency, whereas PPO is performed when the AI is over 35° and there is more anterolateral insufficiency. Our study reveals that that PPO provides more successful femoral head covering and biomechanical stability when compared to SIO. Greater incidence of AVN in SIO makes postoperative follow-up more crucial, with a need to do it more frequently. PPO is a more stable osteotomy technique and should be preferred when there is a necessity of correcting the AI

and CE angles in patients with DDH. PPO requires no internal fixation, there is less risk of vascular or neural injury, and it possesses a lower rate of complications.

Both of the osteotomy techniques have advantages and disadvantages. Preoperative radiologic and intraoperative evaluation of the patients is crucial in determining which procedure should be performed on the patient. We believe that our study will be helpful to surgeons in determining the appropriate surgical procedure in patients with developmental dysplasia of the hip.

## References

1. Salter RB. Innominate osteotomy in the treatment of congenital hip dislocation and subluxation of the hip. *J Bone Joint Surg [Br]* 1961; 43: 518-39.
2. Pemberton PA. Pericapsular osteotomy of the ilium for the treatment of congenitally dislocated hips. *Clin Orthop* 1974; 98: 41-54.
3. Zorer G, Sürel YB, Savran K. DKÇ tedavisinde Salter ve Pemberton ameliyatlarının asetabular deformasyonu düzeltme etkinliklerinin karşılaştırılması. Proceedings of the 13th National Turkish Orthopedics and Traumatology Congress. Ankara: T.H.K. Basımevi; 1994. p.374-77 (in Turkish).
4. Ochoa O, Seringe R, Soudrie B, Zeller R. Salter's single stage bilateral pelvic osteotomy. *Rev. Chir Orthop Reparatrice Appar Mot* 1991; 77: 412-8.
5. Kessler JI, Stevens PM, Smith JT, Carroll KL. Use of allografts in Pemberton osteotomies. *J Pediatr Orthop* 2001; 21: 468-73.
6. Zorer G, Bagatur AE. Single-stage bilateral Pemberton's pericapsular osteotomy in bilateral developmental dysplasia of the hip. *Acta Orthop Traum Turc* 2002; 36: 288-94.
7. Zamzam MM, Khosshal KI, Abak AA. One-stage bilateral open reduction through a medial approach in developmental dysplasia of the hip. *J Bone Joint Surg Br* 2009; 91: 113-8.
8. Bagatur AE, Zorer G, Sürel YB. Is sufficient femoral head coverage obtained after Pemberton's pericapsular osteotomy? Evaluation by three-dimensional computed tomographic reconstruction. *Acta Orthop Traum Turc* 2002; 36: 203-10.
9. Barrett WP, Staheli LT, Chew DE. The effectiveness of the Salter innominate osteotomy in the treatment of congenital dislocation of the hip. *J Bone Joint Surg [Am]* 1986; 68: 79-87.
10. Vengust R, Antolic V, Srakar F. Salter osteotomy for treatment of acetabular dysplasia in developmental dysplasia of the hip in patients under 10 years. *J Pediatr Orthop B* 2001; 10: 30-6.
11. Bohm P, Brzuske A. Salter innominate osteotomy for the treatment of developmental dysplasia of the hip in children: results of seventy-three consecutive osteotomies after twenty-six to thirty-five years of follow-up. *J Bone Joint Surg [Am]* 2002; 84: 178-86.
12. Karakurt L, Yılmaz E, İncesu M, Belhan O, Serin E. Early results of treatment for developmental dysplasia of the hip in children between the ages of one and four years. *Acta Orthop Traumatol Turc* 2004; 38: 8-15.
13. Gulman B, Tuncay IC, Dabak N, Karaismailoglu N. Salter's innominate osteotomy in the treatment of congenital hip dislocation: a long-term review. *J Pediatr Orthop* 1994; 14: 662-6.
14. Morin C, Rabay G, Morel G. Retrospective review at skeletal maturity of the factors affecting the efficacy of Salter's innominate osteotomy in congenitally dislocated, subluxed, and dysplastic hips. *J Pediatr Orthop* 1998; 18: 246-53.
15. Faciszewski T, Kiefer GN, Coleman SS. Pemberton osteotomy for residual acetabular dysplasia in children who have congenital dislocation of the hip. *J Bone Joint Surg [Am]* 1993; 75: 643-9.
16. Olney B, Latz K, Asher M. Treatment of hip dysplasia in older children with a combined one-stage procedure. *Clin Orthop Relat Res* 1998; 347: 215-23.
17. Szepesi K, Rigo J, Biro B, Fazekas K, Poti L. Pemberton's pericapsular osteotomy for the treatment of acetabular dysplasia. *J Pediatr Orthop B* 1996; 5: 252-8.
18. Wada A, Fujii T, Takamura K, Yanagida H, Taketa M, Nakamura T. Pemberton osteotomy for developmental dysplasia of the hip in older children. *J Pediatr Orthop* 2003; 23: 508-13.
19. Beaty JH. Congenital abnormalities of lower limb. In: Canale ST, editor. *Campbell's Operative Orthopaedics*, Vol. 2. 10th ed. St. Louis: Mosby; 2007. p.1042-69.