

Right diaphragmatic lipoma: report of five cases and review of the literature

Yener AYDIN¹, Mustafa Esat YAMAÇ², Ali Bilal ULAŞ¹, Habib BİLEN³, Atila EROĞLU¹

Aim: Approximately 40 diaphragmatic lipoma cases have been reported in the literature to date. Diaphragmatic lipoma is 2 times more likely to appear on the left rather than the right side. In the present study, diaphragmatic lipoma was evaluated in patients who underwent surgical management in light of the literature data.

Materials and methods: This study retrospectively evaluated 5 consecutive diaphragmatic lipoma patients who underwent surgical treatment at the Thoracic Surgery Clinic between January 2003 and April 2012.

Results: Of the patients, 3 were female and 2 were male. The average age of the patients was 62.2 years (range: 54–77). All of the cases were symptomatic and the most common symptom was chest pain (3 cases). Diaphragmatic lipomas were located on the right posterolateral side in all cases. The methods of approach were thoracotomy in 4 cases and video-assisted thoracoscopic surgery in 1 case. Postoperative complications and mortality did not occur in any of the cases. The average hospital stay was 5 days (range: 3–7). There were no recurrences during the average follow-up of 21.4 months (range: 2–58).

Conclusion: A surgical approach to diaphragmatic lipomas offers histopathological diagnosis, curative treatment, and prevention of malignant transformation.

Key words: Diaphragm, lipoma, surgery

Introduction

Lipoma can be seen in any organ. Although half of the soft tissue tumors are lipomas, diaphragmatic localization is very rare (1). The first report of a diaphragmatic lipoma case by autopsy was made in 1886 by Clark (2). Although lipoma is the most common tumor of the diaphragm, reports of only 40 cases to date are found in the literature. In this study, we presented 5 cases of right-sided diaphragmatic lipoma.

Materials and methods

This study retrospectively evaluated 5 consecutive diaphragmatic lipoma patients who underwent surgical treatment at the Thoracic Surgery Clinic between January 2003 and April 2012.

The records of the patients were evaluated in terms of age, sex, clinical findings, location of the lesions, surgical procedures, postoperative hospitalization times, and surgical outcomes.

All of the patients underwent a physical Examination after the taking of their medical history. A complete blood count, biochemical parameters, and coagulation tests were completed for all of the cases.

Results

Of the patients, 3 were female and 2 were male. The average age of the patients was 62.2 years (range: 54–77). All of the cases were symptomatic and the most common symptom was chest pain (3 cases).

Received: 02.05.2012 – Accepted: 07.06.2012

¹ Department of Thoracic Surgery, Faculty of Medicine, Atatürk University, Erzurum – TURKEY

² Department of Thoracic Surgery, Faculty of Medicine, Karadeniz Technical University, Trabzon – TURKEY

³ Department of Internal Medicine, Faculty of Medicine, Atatürk University, Erzurum – TURKEY

Correspondence: Yener AYDIN, Department of Thoracic Surgery, Faculty of Medicine, Atatürk University, Erzurum – TURKEY

E-mail: dryeneraydin@hotmail.com

Diaphragmatic lipomas were located on the right posterolateral side in all cases (Table). The methods of approach were thoracotomy in 4 cases and video-assisted thoracoscopic surgery in 1 case. In all cases, the lesion was excised and the diaphragm was repaired, primarily with silk number 0 (Figures 1–5). A chest tube was placed in the thorax. For suppressing the postoperative pain level, an intercostal blockade was done with bupivacaine. In all of the cases, a histopathological examination revealed a lipoma. Postoperative complications and mortality did not occur in any of the cases. The average hospital stay was 5 days (range: 3–7). There were no recurrences during the average 21.4 months of follow-up (range: 2–58).

Discussion

Primary tumors of the diaphragm are rare, with benign cases being much rarer. Grancher described benign fibroma as the primary tumor of the diaphragm for the first time in 1868 (3). Lipomas and cystic masses (such as bronchogenic and mesothelial teratoid cysts) are the most reported benign diaphragmatic masses. Lipomas constitute

35% of these benign masses (1,3–5). However, the diaphragm is often invaded by malignant pleural or peritoneal diseases (6). The most common primary malign tumors of the diaphragm are sarcomas, which can be fibrous or muscular (3). Lipoma was detected in only 9 of 71 patients with primary neoplasm of the diaphragm (4).

Diaphragmatic lipomas are encapsulated, soft fatty tumors that are usually seen in obese patients (7). The frequency of incidence is equal between the sexes and the lesions usually emerge during the 4th or 5th decade of life. They often settle at the posterolateral part of the diaphragm and are 2 times more likely to be seen on the left side (3). They usually localize at the Bochdalek hernia and rarely occur bilaterally (1,7).

In all 5 of the cases in this study, the lesions were posterolaterally localized at the right side of the diaphragm. Of the patients, 3 were female and 2 were male. All of the patients were in their 6th, 7th, and 8th decades of life, ages that the literature indicates to be advanced.

Diaphragm tumors do not have any characteristic symptoms (8–13). Complaints of a patient with a diaphragm tumor vary according to age, size of mass,

Table. Characteristics of the patients.

	Case 1	Case 2	Case 3	Case 4	Case 5
Age	65	54	77	59	56
Sex	Female	Male	Female	Male	Female
Symptoms	Cough, sputum	Cough, back pain, hemoptysis	Chest–back pain, hemoptysis	Chest pain	Chest pain
Localization	Posterolateral	Posterolateral	Posterolateral	Posterolateral	Posterolateral
Approach	Thoracotomy	Thoracotomy	Thoracotomy	Thoracoscopic	Thoracotomy
Size of lipoma	8 × 5 cm	5 × 5 cm	6 × 4 cm	6 × 5 cm	7 × 5 cm
Complications	No	No	No	No	No
Hospital stay	7 days	5 days	6 days	3 days	4 days
Recurrence	No	No	No	No	No

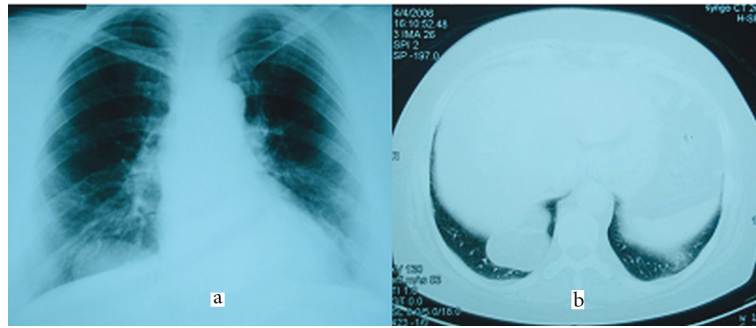


Figure 1. A) Posteroanterior chest radiography of the first case. Ovoid radio-opaque appearance with smooth borders in the lower zone of the right lung. B) CT image showing a clearly bordered homogeneous appearance with the same density of subcutaneous fat tissue.

involvement of adjacent organs, metastatic disease, and histology of the tumor. However, diaphragmatic lipomas are often incidentally determined. Initially, chest-related symptoms are more common than those related to the abdomen. During clinical application, chest pain, shoulder pain, back pain, dyspnea, cough, hemoptysis, and even diaphragmatic rupture have been reported in the literature (1,3,5). Thoracic symptoms were marked in our patients, compatible with the literature.

Williams and Parsons (14) classified diaphragmatic lipomas according to anatomical localization as “intrathoracic lipomas” (total localization in the thoracic cage) and “sandglass thoracic lipomas” (localized both in the intrathoracic and extrathoracic parts, which are classified as cervicomediastinal and

transmural lipomas). Sandglass thoracic lipomas could arise from the right foramen of Morgagni, the hiatus of the vena cava, and the left lumbocostal trigonum, which are 3 weak points of the diaphragm. According to this classification, our diaphragmatic lipoma cases correlate with intrathoracic lipomas.

A radiological evaluation is very important during diagnosis. Views of the diaphragmatic crus are limited in direct radiology. A routine thoracoabdominal computed tomography (CT) scan is preferred to other techniques as it can evaluate morphology and the density of the crus. Water is defined as 0 and air as 100 Hounsfield units (HU) in CT. Negative CT numbers are seen only in air and fat tissue. Fat

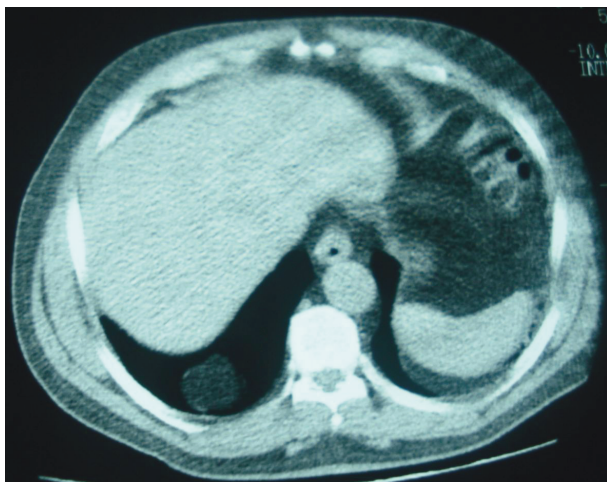


Figure 2. CT image of the second case. Ovoid appearance with homogeneous fat density (-86 HU).

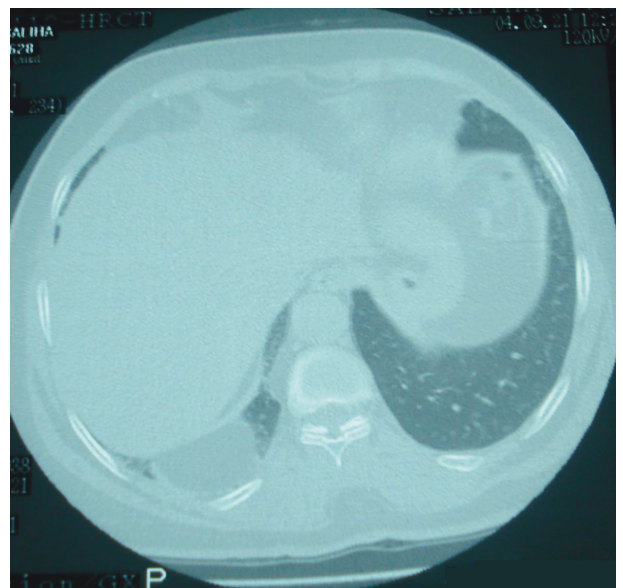


Figure 3. CT image of the third case.

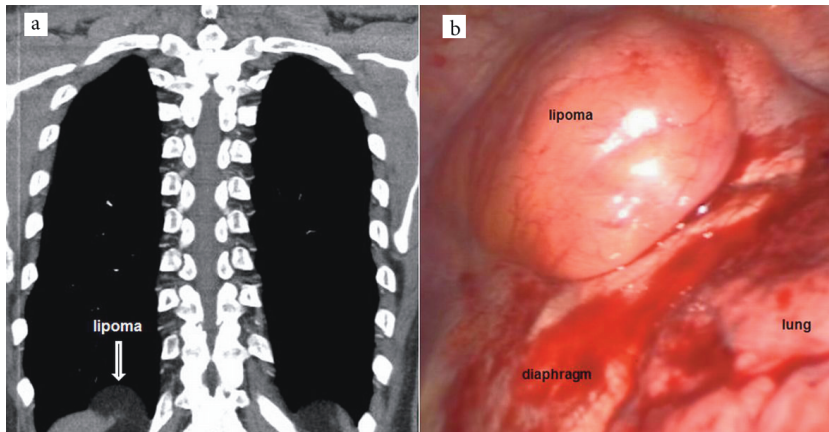


Figure 4. A) CT image of the fourth case and B) video-thoracoscopic appearance of the diaphragmatic lipoma.

tissue is between -80 and -130 HU. CT imaging is accepted as a precise method for lipoma diagnosis due to its high specificity to detect tissues containing homogenous fat tissue (5).

Diaphragmatic lipomas are usually confused with hernias, especially Bochdalek hernias and localized eventrations. Sometimes the left kidney can cause a local elevation of the diaphragm because of its high position, which mimics neoplasm (3,5,15). Eventrations do not disrupt the configuration of the diaphragm, unlike lipomas elliptical or spherical in shape. In adults, Bochdalek hernias usually contain fat. For this reason, they could be incorrectly interpreted as diaphragmatic lipoma. Differential diagnosis of diaphragmatic lipoma from Bochdalek hernia is the most important challenge in diaphragmatic imaging.

In CT, 4 characteristic features are defined for Bochdalek hernia (16). Bochdalek hernias are round-ovoid masses adjacent to the thoracic surface of the

diaphragm, which demonstrate density at -130 to -120 HU. They are located in the posteromedial of the hemidiaphragm. There is an incision at the muscular part of the diaphragm that causes a V-shaped appearance. The density of the diaphragmatic defect continues along through the supradiaphragmatic and subdiaphragmatic densities.

Even though malign variation of lipoma is rare, sometimes this pleomorphic lipoma and others could interfere with a well-differentiated liposarcoma whose malign character may have escaped diagnosis during the initial examination of a tumor (1,3,4).

Differentiation between malignant tumors such as diaphragmatic lipoma and liposarcoma is based on the hypothesis that malignancy could be related to pleural effusion (4). However, histological examination of the complete resection of a lesion is a reliable method for a definite diagnosis. There is no consensus for the treatment of asymptomatic lipoma. Some authors suggested a radiological follow-up of asymptomatic noninfiltrative diaphragm lipoma cases (7). Other authors insisted on surgical treatment due to the risk of the development of diaphragmatic liposarcoma (3,4,8).

As a result, although lipoma is the most common benign tumor of the diaphragm, in the literature only case reports are found. Surgical resection is required to make a differential diagnosis through a definite histopathological diagnosis.

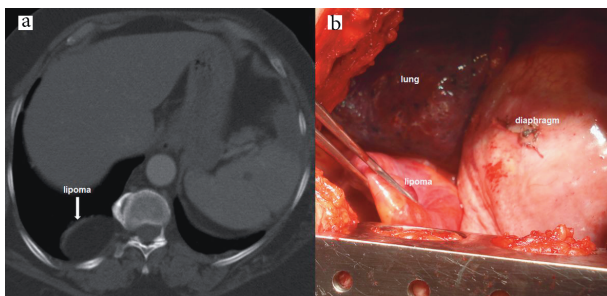


Figure 5. A) CT image of the fifth case and B) intraoperatively appearance of the diaphragmatic lipoma.

References

1. Cheon JS, You YK, Kim JG, Lee DH, Park K, Ahn CJ. Diaphragmatic lipoma in a 4-year-old girl: a case report. *J Pediatr Surg* 2006; 41: e37–9.
2. Clark FW. Subpleural lipoma of diaphragm. *Trans Path Soc Lond* 1886; 38: 324.
3. Sen S, Dişçigil B, Badak I, Gürcün U. Lipoma of the diaphragm: a rare presentation. *Ann Thorac Surg* 2007; 83: 2203–5.
4. Papachristos IC, Laoutides G, Papaefthimiou O, Andrianopoulos EG. Gigantic primary lipoma of the diaphragm presenting with respiratory failure. *Eur J Cardiothorac Surg* 1998; 13: 609–11.
5. Castillo M, Shrikhoda A. Computed tomography of diaphragmatic lipoma. *J Comput Tomogr* 1985; 9: 167–70.
6. Weksler B, Ginsberg RJ. Tumors of the diaphragm. *Chest Surg Clin N Am* 1998; 8: 441–7.
7. Oyar O, Yesildag A, Gulsoy UK. Bilateral and symmetric diaphragmatic crus lipomas: report of a case. *Comput Med Imaging Graph* 2002; 26: 135–7.
8. Shimizu J, Hashimoto T, Imai T, Kawahara E. Primary lipoma of the diaphragm. *Respiration* 1996; 63: 397–9.
9. Yang J, Li S, Kang A, Chen X, Su B, Jin Y. A giant intrathoracic osteolipoma: a case report and review of the literature. *Int J Surg Case Rep* 2012; 3: 290–2.
10. Smahi M, Serraj M, Ouadnoui Y, Lakranbi M. Diaphragmatic lipoma. A case report. *Rev Pneumol Clin* 2011; 67: 127–8.
11. Yarkan Uysal H, Günel S, Uyar AŞ, Başar H. Anesthesia for an adult patient with congenital diaphragmatic eventration. *Turk J Med Sci* 2007; 37: 319–22.
12. Türkyılmaz A, Eroğlu A, Aydın Y, Yılmaz Ö, Karaoğlanoğlu N. Survival in esophageal cancer patients with hematogenous distant organ metastases. *Turk J Med Sci* 2009; 39: 415–21.
13. Klosterman ES, Heng HG, Freeman LJ, Childress MO. Transdiaphragmatic extension of a retroperitoneal lipoma into the intrathoracic extrapleural space via the lumbocostal trigone in a dog. *J Am Vet Med Assoc* 2012; 240: 978–82.
14. Williams WT, Parsons WH. Intrathoracic lipomas. *J Thorac Surg* 1957; 33: 785–90.
15. Doğan NÖ, Aksel G, Demircan A, Keleş A, Bildik F. Gastric volvulus due to diaphragmatic eventration and paraesophageal hernia. *Turk J Med Sci* 2010; 40: 825–8.
16. Oyar O, Kayalioglu G, Cagirci U. Diaphragmatic crus lipoma: a case report. *Comput Med Imaging Graph* 1998; 22: 421–3.