

## Transdiaphragmatic approach to liver and lung hydatid cysts

Yener AYDIN<sup>1</sup>, Mine ÇELİK<sup>2</sup>, Ali Bilal ULAŞ<sup>1</sup>, Atila EROĞLU<sup>1</sup>

**Aim:** Hydatid cysts are a clinical problem in developing and nondeveloped countries. This study aimed to present lung and liver hydatid cysts that underwent the transdiaphragmatic surgical approach.

**Materials and methods:** The study retrospectively evaluated 50 consecutive patients with lung and liver hydatid cysts who underwent transdiaphragmatic surgical treatment at the authors' clinic between January 1998 and December 2011.

**Results:** Twenty-four (48%) patients were male and 26 (52%) were female. The average age of the patients was  $34 \pm 21$  (3–72). All patients had liver cysts and 37 had lung cysts. Forty-eight of the patients underwent thoracotomies, 1 a laparotomy, and 1 a median sternotomy. Frenotomy was the intervention in 49 liver cases and in the case of 1 lung. Excessive biliary drainage occurred in 2 patients postoperatively; fistula from the drain path placed in a liver cyst was evident in 1 patient and pleural effusion occurred in 1 patient. There was no hospital mortality. The average hospital stay was  $9.4 \pm 3.8$  (3–21) days.

**Conclusion:** The simultaneous transdiaphragmatic approach to lung and liver dome cysts is a safe and effective treatment method.

**Key words:** Hydatid cyst, transdiaphragmatic surgery

### Introduction

Hydatid cysts are tissue infestations caused by larval forms of *Echinococcus granulosus*. They may occur at any site in the body. Multiple organ involvement can be seen in approximately one third of hydatid cyst cases (1–5). The most common 2 organs of involvement for hydatid cysts are the liver and lungs, with incidences of 50%–80% and 10%–40%, respectively (1,2). If embryos that enter the liver do not settle there, they approach the heart via the hepatic vein and inferior vena cava, and move from there to the lungs. In addition, upper lobe cysts of the liver can migrate transdiaphragmatically; then ruptured cysts spread in the right hemithorax. In some cases, embryos can settle directly in the lungs by bypassing the liver (6–8). Occasionally, several sessions of surgical procedures

may be required in the treatment of hydatid cysts with multiple organ involvement.

Treatment of patients with multiple organ placements can take a long time. With this condition, patient comfort is adversely affected and hospital costs increase. This study presents cases of right pulmonary and hepatic hydatid cysts for which the authors performed surgery with a one-stage transdiaphragmatic approach.

### Materials and methods

The study retrospectively evaluated 50 patients with lung and liver hydatid cysts who underwent transdiaphragmatic surgical treatment between January 1998 and December 2011.

Received: 04.04.2012 – Accepted: 22.05.2012

<sup>1</sup> Department of Thoracic Surgery, Faculty of Medicine, Atatürk University, Erzurum – TURKEY

<sup>2</sup> Department of Anesthesia and Reanimation, Faculty of Medicine, Atatürk University, Erzurum – TURKEY

**Correspondence:** Yener AYDIN, Department of Thoracic Surgery, Faculty of Medicine, Atatürk University, 25070, Erzurum – TURKEY  
E-mail: dryeneraydin@hotmail.com

The records of the patients were evaluated in terms of age, sex, clinical findings, location of lesions, surgical procedures, postoperative hospitalization time, and surgical outcomes.

All patients underwent a physical examination after their medical history was taken. A complete blood count, biochemical parameters, and coagulation tests were completed for all cases. All patients were evaluated with chest X-rays and thorax computed tomography.

Hydatid cysts of the liver were present in all cases, while lung cysts were associated with 37 cases. General surgeons were consulted in 13 cases of giant cysts; they concluded that the transthoracic approach was appropriate for these cases. In 4 cases (2 lung cysts and 2 liver cysts), empyema was detected because of preoperative cyst rupture; chest tube drainage was performed.

### Surgical technique

An epidural catheter was inserted in 34 patients. Thirty-one patients were intubated with double lumen endotracheal tubes and the others were intubated with standard endotracheal tubes.

Forty-eight patients underwent right thoracotomies. The authors entered through the 7th intercostal space in 33 patients and through the 8th intercostal space in 15. Lung cysts were addressed first. Tampons of 20% diluted povidone iodine absorbed were placed around the cysts. Aspirators attached to large needles entered through the most obvious surfaces of the cysts to aspirate cyst fluid. The cyst walls were opened a few centimeters and the cavities were aspirated again with normal aspirators. The cyst membranes were removed from the cavities and the insides of the cavities were cleaned with povidone-iodine-absorbed gauzes. Saline was inserted into the cavity and lung ventilation was ensured to investigate bronchial leak presence. Bronchial orifices mouths were closed and cavities were capitonated with 2.0 vicryl. The diaphragm was opened by a radial incision over the palpable points of the liver cysts. Cyst fluid was aspirated and cyst membranes were resected by the same technique used for lung cysts. Four patients with bile leakage were sutured. In 14 giant liver cysts, blood supply preserved omentum was placed in the cyst cavity. The

cavities were capitonated in all patients, Petzer drains were placed in the subdiaphragmatic areas, and the diaphragms were closed with No. 0 silk sutures, one by one. The thoraxes were closed, putting 2 drains in the thoracic cavities. The patients were treated with 2 postoperative cycles of 15 mg/kg/day albendazole (2 weeks of drugs and 10 days drug-free in each cycle). One patient with bilateral lung and liver dome cysts was approached via median sternotomy. After intervention to the bilateral lung cysts, the authors approached the liver cysts by opening the diaphragm with the same technique.

In 1 patient, computed tomography revealed 1 cystic lesion (5.5 cm) at the medial segment of the middle lobe of the right lung, 3 cystic lesions (5 cm) at the 7th and 8th segments of the right lobe of the liver, 1 at the 8th segment, and 1 at the left lobe of the 2nd segment 7 cm in diameter each, at the 6th segment 7 cm in diameter, at the caudate lobe 6 cm in diameter, at the 3rd segment 5 cm in diameter, and 1 cystic lesion 8.5 cm in diameter in the spleen. The median laparotomy-incision approach was used in this patient. A splenectomy was performed for the splenic cyst, while cystotomy and omentoplasty were performed for the hepatic cysts. The pulmonary cyst localized above the diaphragm was palpable. The diaphragm was opened by performing an incision of 5–6 cm on the anterior of the diaphragm. Cystotomy and capitonage were performed for the cyst localized in the middle lobe. A thoracic drain was placed and the diaphragm was closed primarily with 0 silk sutures (Table 1).

Table 1. Surgical procedures.

Surgical procedure	N	%
Right posterolateral thoracotomy	48	96
Median sternotomy	1	2
Laparotomy	1	2
Cystotomy and capitonage (lung)	37	100
Cystotomy and capitonage (liver)	50	100
Omentoplasty (liver)	13	26

**Results**

The study included 50 patients; of them 24 (48%) were male and 26 (52%) were female. The mean age was  $34 \pm 21$  (3–72) years. All patients were symptomatic and the most common symptoms were cough (44%), chest pain (40%), and dyspnea (38%) (Table 2). In 1 patient before surgery a lung cyst had ruptured into the diaphragm. In this patient bronchobiliary fistula developed and coughing brought bile up into the mouth.

Nine of the 37 patients with lung cysts had bilateral lung cysts. Two of them also had cysts in the spleen. The lung cyst group comprised 20 (54.1%) patients with intact cysts, while the liver cyst group comprised 38 (76%) patients with intact cysts (Figures 1–3). The average cyst diameter was  $9.9 \pm 3.5$  (4–18) cm (taking the largest cyst diameter in patients with multiple cysts). The most commonly affected lung lobe with lung hydatid cysts was the right lower lobe (86.5%); 5 patients had cysts in the right upper lobe and 5 in the left upper lobe (Table 3).

Table 2. Symptoms of the patients.

Symptoms	n	%
Cough	22	44
Chest pain	20	40
Dyspnea	19	38
Fever	11	22
Sputum	6	12
Nausea and vomiting	5	10
Fatigue/loss of appetite	4	8
Expectoration of cyst fluid	4	8
Abdominal pain	4	8
Back pain	4	8
Hemoptysis	2	4
Biloptysis	1	2
Sweating	1	2

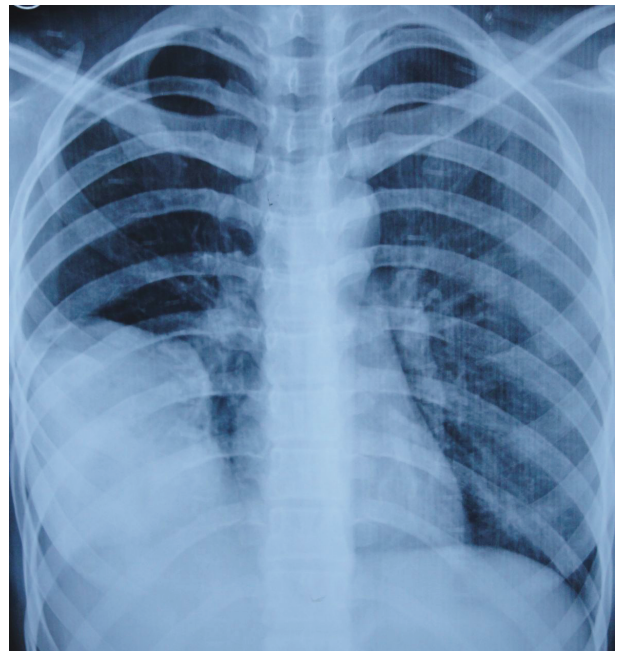


Figure 1. Chest X-ray of a 23-year old female patient with liver and lung cysts.

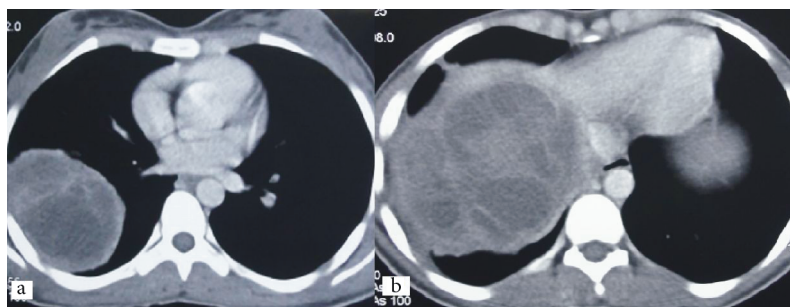


Figure 2. The appearance of cysts in the (a) right lower lobe and (b) liver on thorax computed tomography.



Figure 3. Resected daughter vesicles and cyst membrane.

Table 3. Localizations of lung cysts.

Lung localization	n	%
Right lower lobe	32	86.5
Right upper lobe	5	13.5
Left upper lobe	5	13.5
Left lower lobe	4	10.8
Right middle lobe	2	5.4

Excessive postoperative biliary drainage occurred in 2 patients. An additional surgical procedure was avoided and bile drainage was diminished with follow-up. In 1 patient, fistula occurred from the tract of the drain, which was placed in a liver cyst pouch. In another patient, pleural effusion was observed. Tube thoracostomy was performed in that patient. There was no recurrence or mortality. The average hospital stay was  $9.4 \pm 3.8$  (3–21) days.

## Discussion

Hydatid cysts remain a clinical problem in undeveloped and developing countries. The liver and lungs are the most common organs of involvement. Treatment of patients with multiple organ placements can take a long time. This condition can adversely affect patient comfort and increase hospital costs.

Synchronous pulmonary and hepatic hydatid disease may occur in 4% to 25% of cases (6). The main treatment for hydatid cysts is surgery (6,7). Transdiaphragmatic intervention for hepatic cysts during right thoracotomy, which is appropriate in patients with synchronous right pulmonary and hepatic cysts, prevents patients from undergoing a second surgical or interventional procedure (6,9). Hepatic cysts can be reached by the transdiaphragmatic route during right thoracotomies for pulmonary cysts in synchronous right pulmonary and subdiaphragmatic hepatic cysts and the 2 separate procedures may be performed in 1 stage. Several studies have demonstrated the safety

and acceptable morbidity of this method (9–16). However, the transdiaphragmatic approach is not suitable in all cases of coexistence of right lung and liver hydatid cysts. In liver hydatid cysts the VIth, VIIth, and VIIIth segments of the right lobe can be reached by the transthoracic approach. Laparotomy should be performed in patients with liver hydatid cysts in other locations (17).

Surgery is mandatory for hydatid diseases of the lung. Percutaneous needle aspiration can be applied successfully in the treatment of class I and class II liver hydatid cysts according to Gharbi's classification. However, in patients with simultaneous right lung and liver hydatid cysts, the transdiaphragmatic approach addresses the liver cysts, while opening for a right thoracotomy saves the patient from undergoing a second interventional procedure. With this procedure, many liver cysts can be reached and patients can be prevented from undergoing a second surgical procedure. Furthermore, as in the 13 study cases, without pulmonary hydatid cysts but with only liver dome subdiaphragmatic hydatid cysts, thoracotomy is also preferable to laparotomy (16).

Two approaches are considered in the surgical treatment of superficial cysts of the right lung and liver. The transthoracic approach through the right 7th or 8th intercostal space has been used previously and is still being used currently by many surgeons. On the other hand, the thoraco-abdominal approach is regarded as beneficial and some authorities have supported it recently (6–10).

According to the literature, the incidence of bilateral pulmonary hydatid cysts is 10.8% (9). In our study, pulmonary hydatid cysts were bilateral in 9 (24.3%) cases. Sternotomy for bilateral pulmonary hydatid cysts and liver hydatid cysts has been described previously (13–15). In recent years, studies have shown that interventions to both lungs in the same session by median sternotomy can reduce postoperative pain, hospitalization time, and cost. However, adequate exposure to posterior lesions and lesions thought to be adhered to vital structures probably cannot be achieved. Similarly, sternotomy can be combined with the transdiaphragmatic approach or laparotomy in patients with bilateral hydatid cysts and liver cysts. Sternotomy is a good choice in these cases if the incision is able to reach all the cysts. In the current study, 1 out of 9 cases was approached by median sternotomy. For the other 8 cases, reaching the posterior lung cysts safely was not considered possible by median sternotomy. Primarily, a right thoracotomy was preferred in these cases for liver cysts. Subsequently a left thoracotomy was performed for left lung cysts.

Interventions for pulmonary and subdiaphragmatic hepatic cysts in the same procedure with a right thoracotomy are commonly used as a safe and efficient method. However, for cysts localized in abdominal organs and requiring laparotomy, reports of pulmonary cysts undergoing transdiaphragmatic interventions do not appear in the literature. In our case, an absolute laparotomy was indicated due to the small and intact cyst in the lung, and larger and greater numbers of cysts in the liver. A transdiaphragmatic intervention

by laparotomy was performed for the pulmonary cyst. No complications occurred in the cystotomy–capitonnage procedure performed for pulmonary cysts without thoracotomy.

Approach by laparotomy to lung cysts is not a routine method but it is applicable in the following cases:

1. The patient must have an absolute indication for laparotomy.
2. Pulmonary cysts must not be complicated or giant.
3. Pleural adhesions must not be found.
4. The localization of the pulmonary cysts must allow the laparotomy to reach in through the transdiaphragmatic route (lung base).

Extensive morbidity was reported in the literature, i.e. 1.4%–19.1%, and mortality was reported as 0.6%–4.2% in lung hydatid cysts (6,15–22). In liver cysts, 6%–47% morbidity and 0%–3% mortality were reported (6,15–20). In our study, 2 patients had excessive biliary drainage postoperatively and biliary drainage stopped spontaneously. In 1 patient, fistula occurred due to the drain path placed in the liver cyst pouch. In another patient, pleural effusion occurred. Tube thoracostomy was applied in this patient. There was no mortality.

In conclusion, hydatid cyst disease is still a serious health problem in many countries worldwide. The transdiaphragmatic method is efficient and safe and prevents the patient from requiring a second operation. The authors think that this method should be considered in selected cases.

## References

1. Amendolara M, Bucca D, Barbarino C, Romano MF, Marino G, Zucchelli M et al. Surgical management of symptomatic simple hepatic cysts. *G Chir* 2012; 33: 17–20.
2. Pathak TK, Roy S, Das S, Achar A, Biswas AK. Solitary hydatid cyst in thigh without any detectable primary site. *J Pak Med Assoc* 2011; 61: 1244–5.
3. Akıncı ÖF, Karaoğlanoğlu M, Bozkurt MS, Gözaydın L, Ziyilan SZ. In vitro efficacy of different chemical substances on hydatid cyst components. *Turk J Med Sci* 2011; 41: 17–23.
4. Özekinci S, Bakır Ş, Uzunlar AK, Eren Ş. Pulmonary hydatid disease in southeastern Anatolia, Turkey. *Turk J Med Sci* 2010; 40: 637–41.
5. Karaoğlanoğlu M, Akıncı ÖF, Ulukanlıgil M, Metin MR, Çetin H, Çay N. Hydatid cyst viability: the effect of scolicedal agents on the scolex in the daughter cyst. *Turk J Med Sci* 2011; 41: 1001–6.
6. Sahin E, Enön S, Cangir AK, Kutlay H, Kavukçu S, Akay H et al. Single-stage transthoracic approach for right lung and liver hydatid disease. *J Thorac Cardiovasc Surg* 2003; 126: 769–73.
7. Karaoğlanoglu N, Kurkcuoglu IC, Gorguner M, Eroglu A, Turkyilmaz A. Giant hydatid lung cysts. *Eur J Cardiothorac Surg* 2001; 19: 914–7.

8. Karaođlanođlu N, Erođlu A, Polat KY. Surgical procedure for bilateral lung and liver hydatid cysts. *Ann Thorac Surg* 1998; 66: 988–9.
9. Kir A, Baran E. Simultaneous operation for hydatid cyst of right lung and liver. *Thorac Cardiovasc Surg* 1995; 43: 62–4.
10. Eren N, Ozgen G. Simultaneous operation for right pulmonary and liver echinococcosis. *Scand J Thorac Cardiovasc Surg* 1990; 24: 131–4.
11. Khuroo MS, Wani NA, Javaid G, Khan BA, Yattoo GN, Shah AH et al. Percutaneous drainage compared with surgery for hepatic hydatid cysts. *N Engl J Med* 1997; 337: 881–7.
12. Kurkcuoglu IC, Eroglu A, Karaoglanoglu N, Turkyilmaz A, Tekinbas C, Basoglu A. Surgical approach of pulmonary hydatidosis in childhood. *Int J Clin Pract* 2005; 59: 168–72.
13. Cetin G, Dođan R, Yüksel M, Alp M, Uçanok K, Kaya S et al. Surgical treatment of bilateral hydatid disease of the lung via median sternotomy: experience in 60 consecutive patients. *Thorac Cardiovasc Surg* 1988; 36: 114–7.
14. Kozhujharov S, Chervenjakov P. Longitudinal sternotomy—a method for the surgical option in pulmonary and hepatic echinococcosis. *Khirurgiia (Sofia)* 1995; 48: 12–6.
15. Dhaliwal RS, Kalkat MS. One-stage surgical procedure for bilateral lung and liver hydatid cysts. *Ann Thorac Surg* 1997; 64: 338–41.
16. Athanassiadi K, Kalavronziotis G, Loutsidis A, Bellenis I, Exarchos N. Surgical treatment of echinococcosis by a transthoracic approach: a review of 85 cases. *Eur J Cardiothorac Surg* 1998; 14: 134–40.
17. Smyrniotis VE, Kostopanagiotou EK, Farantos CI, Katis CI, Kostopanagiotou GG. Transthoracic versus transabdominal surgical approach for echinococcal cysts located over the superoposterior aspect of the right lobe of the liver. *World J Surg* 2003; 27: 699–702.
18. Yaldiz S, Gursoy S, Ucvet A, Yaldiz D, Kaya S. Capitonnage results in low postoperative morbidity in the surgical treatment of pulmonary echinococcosis. *Ann Thorac Surg* 2012; 93: 962–6.
19. Yorgancı K, Sayek I. Surgical treatment of hydatid cysts of the liver in the era of percutaneous treatment. *Am J Surg* 2002; 184: 63–9.
20. Ahmadi NA, Badi F. Human hydatidosis in Tehran, Iran: a retrospective epidemiological study of surgical cases between 1999 and 2009 at two university medical centers. *Trop Biomed* 2011; 28: 450–6.
21. Kurkcuoglu IC, Eroglu A, Karaođlanođlu N, Polat P. Complications of albendazole treatment in hydatid disease of lung. *Eur J Cardiothorac Surg* 2002; 22: 649–50.
22. Kürkçüođlu IC, Erođlu A, Karaođlanođlu N, Polat P. Tension pneumothorax associated with hydatid cyst rupture. *J Thorac Imaging* 2002; 17: 78–80.