

## Endovenous laser ablation for saphenous vein insufficiency: long-term results

Ömer ETLİK<sup>1\*</sup>, Aşkın Ali KORKMAZ<sup>2</sup>, Yeşim ÜÇKURT<sup>1</sup>, Sevim İNDELEN<sup>3</sup>,  
Recep GÜNDOĞDU<sup>4</sup>, Alaattin ÖZTÜRK<sup>5</sup>, Salih ALSALEHİ<sup>2</sup>, Soe Moe AUNG<sup>4</sup>

<sup>1</sup>Department of Radiology, Faculty of Medicine, Fatih University Sema Training Hospital, Dragos, İstanbul, Turkey

<sup>2</sup>Department of Cardiovascular Surgery, Faculty of Medicine, Fatih University, Sema Training Hospital, Dragos, İstanbul, Turkey

<sup>3</sup>Department of Anesthesiology, Faculty of Medicine, Fatih University, Sema Training Hospital, Dragos, İstanbul, Turkey

<sup>4</sup>Department of Cardiology, Faculty of Medicine, Fatih University, Sema Training Hospital, Dragos, İstanbul, Turkey

<sup>5</sup>Department of General Surgery, Faculty of Medicine, Fatih University, Sema Training Hospital, Dragos, İstanbul, Turkey

Received: 18.06.2012 • Accepted: 09.08.2012 • Published Online: 29.05.2013 • Printed: 21.06.2013

**Aim:** To present the long-term results of our 158 endovenous laser ablation (EVLA) procedures.

**Materials and methods:** From June 2008 to December 2011, 158 patients (89 women, 69 men; mean age: 38.2 years, range: 27–65) were treated with EVLA for venous insufficiency in 192 lower limbs. All patients were symptomatic and the majority had a class 4 or higher clinical disease (CEAP classification). A 980-nm diode laser was used under general anesthesia combined with local tumescent anesthesia to deliver 100 to 140 laser applications along the course of the vein. Compression bandages were applied for 2 weeks postoperatively. Follow-up exams were done by Doppler ultrasound exam at 4 weeks, 6 months, 1 year, and 2 years.

**Results:** A total of 192 great saphenous veins were ablated, achieving a 99% clinical success rate. Postoperative complications were mild and well tolerated. Of the 2 (1.0%) recanalized target veins, 2 were successfully treated with a second EVLA procedure. After 3 to 6 months of EVLA treatment, 99% of the patients had significant relief of their symptoms. All patients returned to normal activity within 2 days.

**Conclusion:** EVLA for symptomatic saphenous vein incompetence is a minimally invasive and successful technique in resolving varicose veins and reducing symptoms.

**Key words:** Venous insufficiency, laser ablation, saphenous vein

### 1. Introduction

Venous disease is a quite common disease affecting about 25% of the female and 15% of the male population. The main cause of venous insufficiency is primary valvular incompetence. Mild venous disease can cause some clinical complaints as it worsens but is usually asymptomatic. Reflux within the saphenous vein, which results in distal varicose changes, is the underlying cause of varicose veins in most cases (1).

There are a number of treatment options for saphenous vein incompetence, such as stripping, sclerotherapy, ligation, and endovenous laser ablation. Both ligation of the great saphenous vein (GSV) and stripping have previously been used as a surgical treatment; however, recurrence rates of up to 40% at 5 years have been observed. Even in the absence of complications, significant postoperative morbidity have been associated with the surgery (2,3).

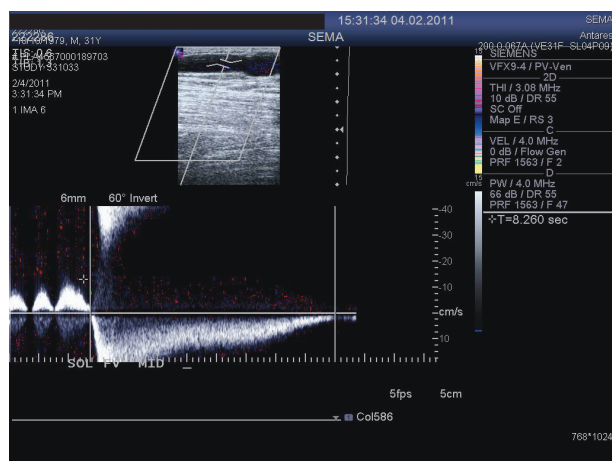
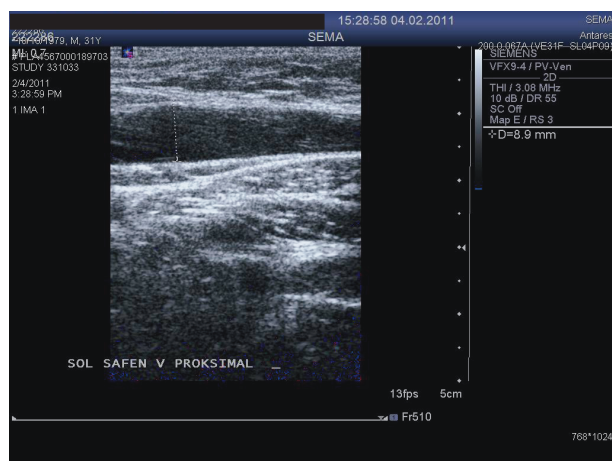
In recent years, new methods of minimally invasive

endovenous interventions have been introduced (3,4). In this study, we present our long-term results of 192 incidences of this less invasive endovenous laser ablation (EVLA) treatment.

### 2. Materials and methods

A total of 158 patients (89 women, 69 men; mean age: 38.2 years, range: 27–65) were included for EVLA treatment for venous insufficiency in 192 lower limbs from June 2008 to December 2011. All patients had symptomatic venous insufficiency. Doppler ultrasonography (US) was performed in all patients and EVLA was carried out in those with grade 3 and 4 venous incompetence (Figures 1a and 1b). Written informed consent, which delineated the reported initial success of the procedure and potential complications, was obtained. Before the laser ablation, a Doppler US examination was performed in order to delineate the varicose vein course on the skin. Under general anesthesia,

\* Correspondence: omeretlik@yahoo.com



**Figure 1.** A 28-year-old man with symptoms of venous insufficiency. Doppler US shows the dilatation of a saphenous vein (a) and the retrograde flow with the Valsalva maneuver (b).

the veins were punctured with a 21-gauge needle under US guidance while the patient was in an upright position on a tiltable table. After the vein was punctured, a 0.889-mm guidewire was inserted into the vein, and then a 5F sheath was placed over the wire up to the saphenofemoral junction (SFJ). We then made the last check to ensure that the tip of the laser fiber was located 2–3 cm distal from the SFJ.

In order to generate sufficient heat to cause thermal damage, a 980-nm diode laser (Intros, Germany) was used. The laser energy damages the vein walls and results in an occlusion in vessel lumen. The tumescent anesthesia (1000 mL isotonic, 7.5 mL 10% jetmonal, 100 mL 8.4% sodium bicarbonate, and 0.5 mL adrenaline) was carried out and the anesthetic solution was injected around the saphenous vein. This solution provides a compression effect on the veins, thus preventing thermal damage to the surrounding structures. The sheath and probe were removed together in 1- to 2-mm increments; 100 to 140 laser applications (at 15 W/s for the first 2 cm and 13 W/s for the remainder of the vein) were used in a treatment. The chosen parameters for ablation were as follows: power 10–15 W, duration 1 s, interval 1. We used lower energy levels for smaller veins and higher energy levels for larger veins. In all patients, phlebectomy was also performed for varicosities after the EVLA procedure.

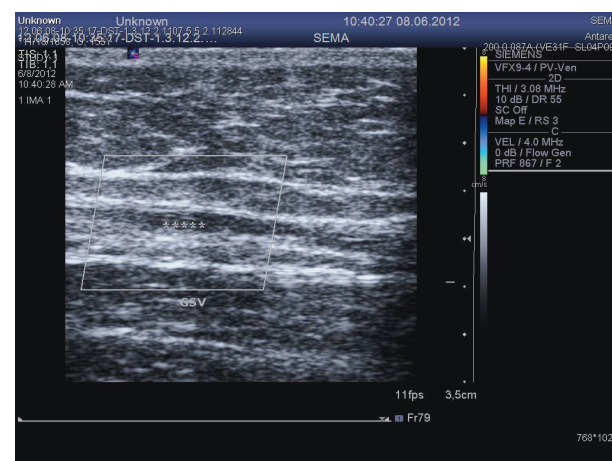
After the procedure, patients were discharged and instructed to keep the 3-layer compression wrap on for 2 days. They were asked to wear custom-made compression stockings, except during sleeping and showering, until their first follow-up appointment at 4 weeks. Each patient was prescribed 600 mg of ibuprofen for its antiinflammatory effect. On the first postoperative visit, all patients underwent Doppler US of the target vein to confirm thrombotic occlusion and demonstrate evidence of wall thickening. Future visits were scheduled depending

on the physical exam findings and symptoms. Follow-up examinations were done at 4 weeks, 6 months, 1 year, and 2 years. We performed a 2-year follow-up exam on 98 patients, a 1-year follow-up exam on 32 patients, and a 6-month follow-up exam on 28 patients.

### 3. Results

We performed laser ablation in all the patients concomitant with phlebectomy. Eight tortuous GSVs could not be cannulated, and thus an antegrade approach was performed. We punctured the proximal saphenous segment under sonographic guidance just distal to the SFJ.

In 98 patients examined more than 2 years after the EVLA, no recurrent varicosities were seen; instead, Doppler US demonstrated a thin, fibrous cord in the area of the previously ablated vein (Figure 2). Furthermore, 28 patients also had no recurrence despite a short time of follow-up period (6 months).



**Figure 2.** After 6 months, follow-up Doppler US showed a totally occluded saphenous vein seen as a thin linear echogenicity.

Before treatment, all patients had symptoms; however, 84% of patients claimed their symptoms diminished after the treatment. Among all responders, satisfaction with the procedure was significantly favorable.

Postprocedural Doppler US revealed 2 (1%) recurrent varicose veins just distal to the ablated veins at the 6-month follow-up exam. For these patients, some perforated vessels occurred and resulted in a distal dilated vessel. The previous EVLA procedure ended just proximal to the knee, and in the course of time some developed collateral vessels and perforated veins were joined to the saphenous vein around the knee. As a result, recurrent varicose vessels occurred. We performed a second laser ablation procedure to the distal segment of the saphenous vein.

There was no deep vein thrombosis (DVT) or severe nerve injury, but 44 patients experienced mild indurations and 32 ecchymoses along the course of the ablated vein after the procedure; these symptoms usually abated after about 2 weeks. None of the patients had DVT or evidence of thrombus protruding into the common femoral vein. One patient had minimal nerve injury, which subsided spontaneously in 2 weeks.

#### 4. Discussion

Venous diseases affect 25% of the female and 15% of the male population. The venous reflux at the SFJ is the most common cause of this disease. Generally, venous enlargement does not cause any symptoms (5). The most common treatment has been the ligation and stripping of the GSV. The EVLA treatment has been used as an alternative treatment since 1998 (1–3).

Surgical treatment is painful and requires a long hospital stay. In addition, high rates of recurrence are observed with surgical treatment. One study shows that as much as a 29% recurrence rate has been reported (4–7).

EVLA treatment was first reported in 1999. The main mechanism behind this method causes thermal damage to the blood vessel wall and results in vein wall fibrosis. EVLA has demonstrated a 90% success rate over several years. Endovenous ablation has several advantages over conventional surgical procedures, such as a lower level of postoperative pain, an earlier recovery, and a reduction in cost. Large-scale studies have shown an approximately 100% technical success rate and a long-term success rate (up to 5 years) ranging from 90% to 100% (7–9). Our study showed that EVLA has an approximately 99% success rate.

The success rate of saphenous vein occlusion ranges from 88% to 100% due to the various laser systems that vary in wavelength (8,9). According to Dexter (10), wavelengths of a particular range (810 nm versus 980 nm)

were determined to be insufficient for GSV treatment. The study's result displayed positive effects, which favored a 980-nm wavelength laser. Bruising at the site, postprocedural pain, and phlebitis were minimal. Therefore, we preferred an endovenous laser with a wavelength of 980 nm for our study. We achieved 100% technical success and a 99% closure rate after 6 and 12 months.

The risks associated with this procedure include bruising, phlebitis, brown stains on the skin, infection, and incomplete closure. Bruising is most common and was seen in 44% of our patients, which was minimal, moderate, or even extensive. Bruising can last up to 1–2 weeks, but in some cases it can be visible for months. Another minor complication is phlebitis, which can make the area become painful and tender, or can cause some skin discoloration. Another postablation change observed are brown stains on the skin, which are caused by iron from the blood. This is usually minor and resolves over the course of a few months. Occasionally, they are darker and can last for several months to a couple of years. The rest of the minor complications rarely occur and have no clinical significance. Hospital stay is less than in surgical treatment, as in our cases. Serious complications following an EVLA are uncommon (3,4). DVT is one of the important complications related to the procedure. The reported incidence of DVT related to the procedure is 1%, but we had no case of DVT in our study. We think that early mobilization, use of effective tumescent anesthesia, and wearing of compression stockings were effective in preventing DVT.

We had 2 recurrent varicose veins just distal to the ablated veins at the 6-month follow-up exam. In these patients, some perforated vessels occurred and resulted in a distal dilated vessel. The previous EVLA procedure had ended just proximal to the knee, and with time collateral vessels and perforated veins had joined to the saphenous vein around the knee. We had to perform a second EVLA procedure on these patients. We thought that performing EVLA on a more distal segment of the GSV might have prevented the recurrence in these patients. We concluded that the EVLA should be made as long as possible and should end just distal to the knee in order to prevent recurrence.

EVLA is an effective, safe, and successful method for treating an incompetent saphenous vein. This method has various advantages over surgical ligation and stripping. Concomitant phlebectomy with EVLA prolonged the procedure, but reduced the need for secondary procedures and significantly improved the quality of life and the severity of the patient's venous disease.

**References**

1. Min RJ, Zimmet SE, Isaacs MN. Endovenous laser treatment of the incompetent greater saphenous vein. *J Vasc Interv Radiol* 2001; 12: 1167–71.
2. Teruya TH, Ballard JL. New approaches for the treatment of varicose veins. *Surg Clin North Am* 2004; 84: 1397–417.
3. Wagner WH, Levin PM, Cossman V, Lauterbach SR, Cohen JL, Farber A. Early experience with radiofrequency ablation of the greater saphenous vein. *Ann Vasc Surg*. 2004; 18: 42–7.
4. Dietzek AM. Endovenous radiofrequency ablation for treatment of varicose veins. *Vascular* 2007; 15: 255–61.
5. Ünlü Y, Karapolat S, Erkut B. Multiple aneurysms of the left external jugular vein. *Turk J Med Sci* 2005; 35: 43–5.
6. Min RJ, Khilnani NM. Endovenous laser ablation of varicose veins. *J Cardiovasc Surg* 2005; 46: 395–405.
7. Merchant RF, Pichot O. Long-term outcomes of endovenous radiofrequency obliteration of saphenous reflux as a treatment for superficial venous insufficiency. *Vasc Surgery* 2005; 42: 502–9.
8. Almeida JA, Kaufman JA. Radiofrequency endovenous ClosureFAST versus laser ablation for the treatment of great saphenous reflux: a multicenter, single-blinded, randomized study. *JVIR* 2009; 20: 752–9.
9. Timperman PE, Sichlau M, Ryu RK. Greater energy delivery improves treatment success of endovenous laser treatment of incompetent saphenous veins. *J Vasc Interv Radiol* 2004; 15: 1061–3.
10. Dexter D, Kabnick L, Berland T, Jacobowitz G. Complications of endovenous laser. *Phlebology* 2012; 27 (Suppl 1): 40–5.