

## Choroidal thickness in healthy Turkish subjects

Erol COŞKUN\*, Seydi OKUMUŞ, Bülent GÜRLER, Ramazan YAYUSPAYI, Burak ÖREN,  
Erdal KAYDU, Ayşegül ÇÖMEZ, İbrahim ERBAĞCI

Department of Ophthalmology, Faculty of Medicine, Gaziantep University, Gaziantep, Turkey

Received: 12.11.2012 • Accepted: 15.01.2013 • Published Online: 02.01.2014 • Printed: 24.01.2014

**Aim:** To investigate choroidal thickness in healthy Turkish subjects.

**Materials and methods:** Refraction, axial length (AXL) measurement, anterior chamber, and fundus examinations were performed. Eyes that had any retinal or choroidal pathology were excluded from the study. Enhanced-depth imaging optical coherence tomography was used to evaluate choroidal thickness.

**Results:** 139 eyes from 70 subjects were investigated. The mean age, AXL, spherical equivalent refractive error (SE), and subfoveal choroidal thickness (SCT) were  $32.9 \pm 11.6$  years,  $23.31 \pm 0.91$  mm,  $-0.15 \pm 1.64$  diopters (D), and  $326 \pm 60$   $\mu$ m, respectively. A negative correlation was found between SCT and AXL ( $P = 0.043$ ). The mean age, SE, AXL, and SCT were  $31.7 \pm 9.3$  and  $34.6 \pm 14.3$  years,  $-0.27 \pm 1.45$  and  $0.02 \pm 1.89$  D,  $23.52 \pm 0.94$  and  $23.02 \pm 0.75$  mm, and  $324 \pm 69$  and  $329 \pm 40$   $\mu$ m in male and female subjects, respectively ( $P = 0.14$ ,  $P = 0.31$ ,  $P = 0.001$ , and  $P = 0.58$ , respectively). Regression analysis showed that SCT decreased by  $0.93$   $\mu$ m for each year of age.

**Conclusion:** In healthy Turkish subjects, SCT decreased by  $0.93$   $\mu$ m for each year of age and was thicker in men when the results were adjusted according to AXL measurements.

**Key words:** Choroidal thickness, EDI OCT

### 1. Introduction

The choroid carries oxygen and metabolites to the prelaminar side of the optic nerve and outer segment of the retina, absorbs the excess light penetrating to the retina and retinal pigment epithelium (RPE) with the aid of the melanocytes that it contains, and acts as a heat sink in many psychological events. The choroidal blood flow is the highest blood flow per tissue mass in the human body (1–3). The choroid cannot be fully investigated via choroid ophthalmoscopy, fundus picture, and fundus fluorescent angiography because of the pigments contained by the choroid and RPE. In addition, it is hard to obtain a full layer image, and information on cross-sectional anatomy of the choroid cannot be obtained. B-Scan ultrasound was used in order to obtain cross-sectional images of the choroid (4). However, resolution was not at the desired level, and since different cross-sections were obtained in each examination, it is a method with weak repeatability.

Enhanced-depth imaging optical coherence tomography (EDI OCT) technologies permit deeper penetration through RPE and a better visualization of the choroid. Studies in healthy individuals and in patients with age-related macular

degeneration (AMD), central serous chorioretinopathy (CSC), high myopia, and glaucoma that investigated the choroidal thickness were performed by using EDI OCT technologies (5–10). It was reported that choroidal thickness may differ according to ethnicity; therefore, many studies assessing the normal mean choroidal thickness in different ethnic groups were performed (6,7). In this study, the normal choroidal thickness values in healthy Turkish individuals are investigated.

### 2. Materials and methods

The study group consisted of the volunteers who were examined in our clinics between February 2012 and January 2013. Refraction, axial length (AXL) measurement, uncorrected visual acuity, best corrected visual acuity, intraocular pressure, anterior chamber, and dilated fundus examinations were performed on all individuals. Exclusion criteria included diabetes mellitus, hypertension, history of intraocular surgery, photodynamic therapy, transpupillary thermotherapy, focal laser treatment, ionizing radiation, uveitis, AMD, CSC, glaucoma, amblyopia, high myopia, and poor image quality due to severe cataract. Gaziantep

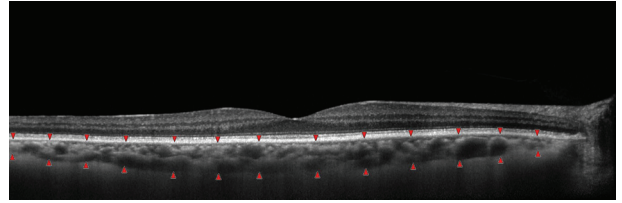
\* Correspondence: drerolcoskun@yahoo.com

University ethics committee approval and informed consents from all patients in accordance with the Declaration of Helsinki were obtained.

### 2.1. Measurement protocol

All EDI OCT measurements were performed by the same clinician (R.Y.) between 1430 and 1600 hours. EDI OCT was performed using Heidelberg Spectralis equipment (Heidelberg Engineering Inc., Heidelberg, Germany) for both eyes of each participant. The EDI OCT images were obtained based on a previously described method (5). Seven sections, each comprising 100 scans using the automatic averaging and eye tracking features, were obtained. The horizontal section going directly through the center of the fovea was selected.

The choroidal thickness was measured from the outer portion of the hyperreflective line corresponding to the RPE to the inner surface of the sclera (Figure 1). The choroidal thicknesses at the fovea, 3 mm nasal to the fovea, and 3 mm temporal to the fovea were measured. Two examiners who were masked to subjects' refraction and axial length (EC and RY) measured the choroidal thickness in all subjects and the mean value of the measurements was calculated. The eyes having more than 15% difference of measurement between the 2 ophthalmologists were excluded from the study.



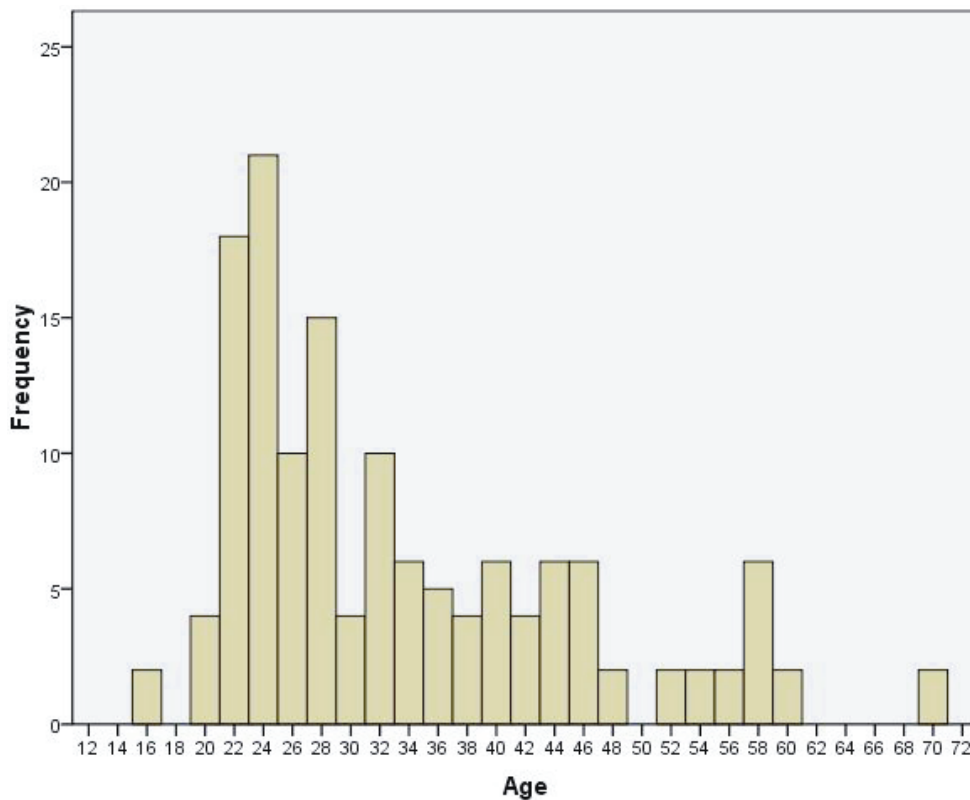
**Figure 1.** An EDI OCT scan obtained from a 58-year-old female subject. The choroidal thickness was measured from the RPE to the inner surface of the sclera (arrowheads).

### 2.2. Statistical analysis

SPSS 11.5 for Windows (SPSS Inc., Chicago, IL, USA) was used for statistical analyses. Data were recorded as the mean  $\pm$  standard deviation. The paired t-test was used to analyze choroidal thickness at different locations. The Pearson correlation test was used to investigate the correlation between different variables. A P-value of less than 0.05 was considered statistically significant.

### 3. Results

A total of 139 eyes from 28 female and 42 male patients were included in the study. Seventy right eyes and 69 left eyes were analyzed. The mean age of the subjects was  $32.9 \pm 11.6$  years (range: 16–70) (Figure 2). The mean AXL



**Figure 2.** The distribution of age of all subjects.

was  $23.31 \pm 0.91$  mm (range: 20.77–26.10). The mean spherical equivalent refraction error (SE) was  $-0.15 \pm 1.64$  (range:  $-5.75$  to  $5.50$ ) (Figure 3). The choroidal thickness measurements of the 2 examiners were significantly correlated (correlation coefficient: 0.843,  $P < 0.01$ ). The mean choroidal thickness at subfoveal, nasal, and temporal sites was  $326 \pm 60$ ,  $179 \pm 58$ , and  $240 \pm 55$   $\mu\text{m}$ , respectively (Table).

There were significant differences between subfoveal thickness and each extrafoveal choroidal thickness ( $P < 0.01$  to  $P < 0.01$ ). There was significant correlation between choroidal thickness measurements at subfoveal and at nasal and temporal locations ( $P < 0.01$  and  $P < 0.01$ , respectively). A negative correlation was found between age and the choroidal thickness at subfoveal, temporal, and nasal locations ( $P = 0.03$ ,  $P = 0.02$ , and  $P = 0.04$ , respectively) (Figure 4).

A negative correlation was found between SE and the choroidal thickness at subfoveal, temporal, and nasal locations ( $P = 0.034$ ,  $P = 0.019$ , and  $P = 0.037$ , respectively). A negative correlation was found between AXL and the choroidal thickness at subfoveal, temporal, and nasal locations ( $P = 0.043$ ,  $P = 0.03$ , and  $P = 0.021$ , respectively). Regression analysis demonstrated that subfoveal choroidal thickness decreased by  $0.93$   $\mu\text{m}$  for each year of age.

When the data from the male and female groups were assessed as 2 different groups, the mean age was  $31.7 \pm 9.3$  years in male subjects and  $34.6 \pm 14.3$  years in female subjects ( $P = 0.14$ ). The mean AXL was  $23.52 \pm 0.94$  mm in male subjects and  $23.0 \pm 0.75$  mm in female subjects ( $P = 0.001$ ). The mean SE was  $-0.27 \pm 1.45$  diopters (D) in male subjects and  $0.02 \pm 1.89$  D in female subjects ( $P = 0.31$ ). The mean subfoveal choroidal thickness was  $324 \pm 69$   $\mu\text{m}$  in male subjects and  $329 \pm 40$   $\mu\text{m}$  in female subjects ( $P = 0.58$ ).

#### 4. Discussion

Diseases such as AMD, polypoidal choroidal vasculopathy (PCV), CSC, and high myopia are thought to result from pathological changes in choroidal tissue (11–15). The incidence of AMD and PCV vary according to ethnicity. For example, wet AMD and PCV are more common in Japanese populations compared to Caucasians (16). In a study that assessed the AMD prevalence in Hispanic, black, Chinese, and white patients, wet AMD was reported to be most common among the Chinese population (17). This may be due to environmental and genetic factors as well as the interracial difference in choroidal structure, since choroidal tissue plays a vital role in the pathophysiology of both diseases. As a result, evaluation of the choroidal tissue

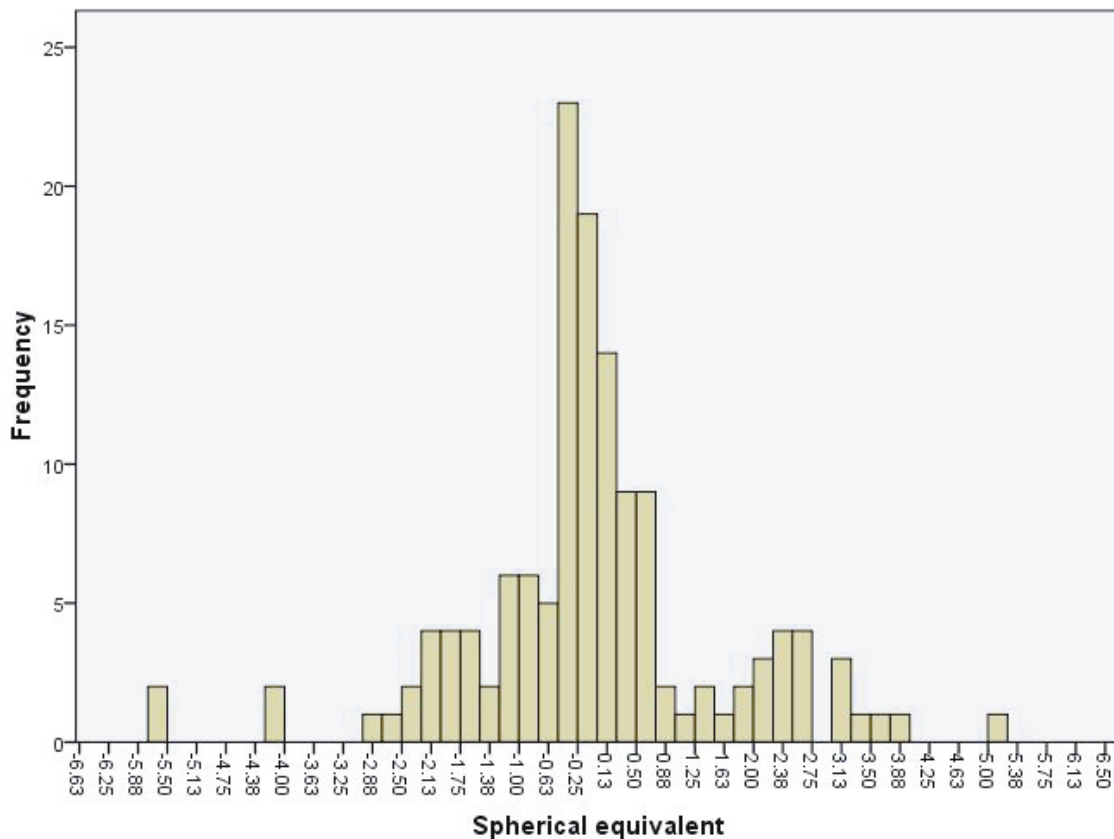
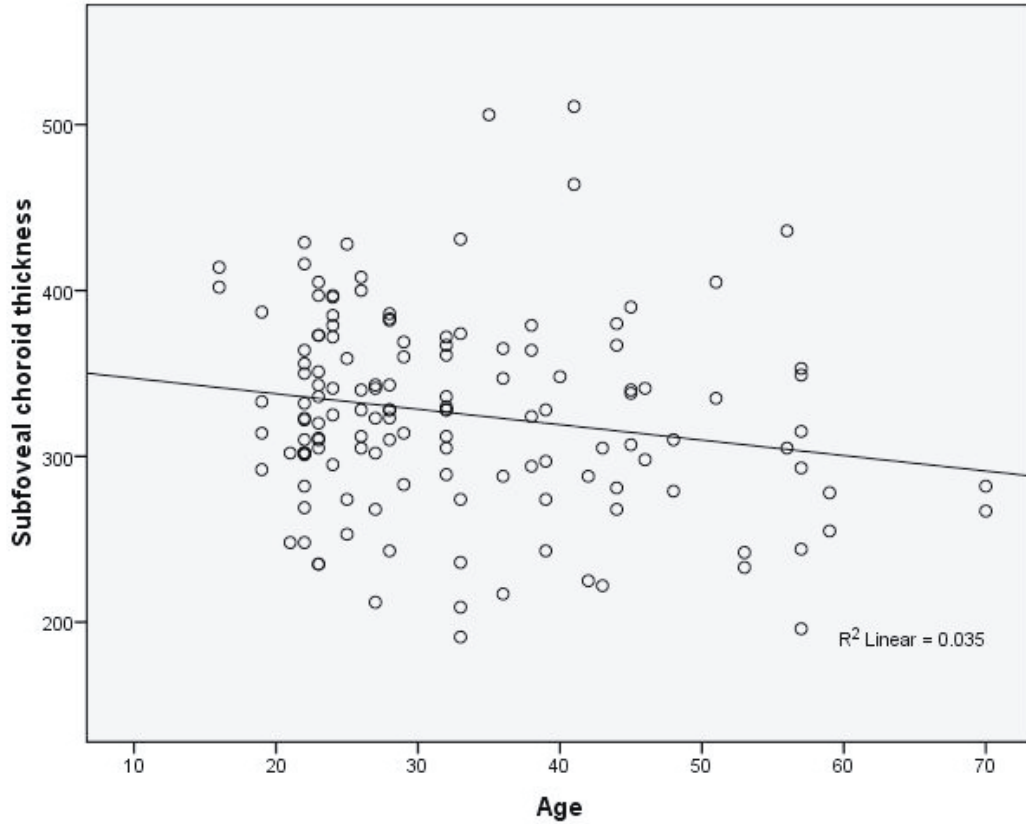


Figure 3. The distribution of the spherical equivalent refraction error of all subjects.



**Figure 4.** Scatterplot of age and subfoveal choroidal thickness of all subjects.

**Table.** Demographic properties of the individuals who were involved in the study and the measurement results of the eyes.

Age (years)	32.9 ± 11.6
Sex (male/female)	42/28
Axial length (mm)	23.31 ± 0.91
Spherical equivalent (D)	-0.15 ± 1.64
Subfoveal choroidal thickness (µm)	326 ± 60
Temporal choroidal thickness (µm)	240 ± 55
Nasal choroidal thickness (µm)	179 ± 58

in different races or ethnicities may aid in pinpointing the diseases in which pathophysiology of the choroid plays a role. This study, to the best of our knowledge, is the first study that investigates the choroidal thickness in a healthy Turkish population.

In this study, it was found out that the subfoveal, nasal, and temporal choroidal thicknesses were inversely proportional to the age and SE and AXL parameters of the eye in the Turkish population. Similarly, in studies conducted within different ethnic groups, it was reported

that there were negative correlations between choroidal thickness and AXL and SE values (5–7). It was observed in this study that subfoveal choroidal thickness was decreased by 0.93 µm per age. This value was reported to be 1.56 µm in an American population, though not representing a homogeneous society, and 1.40 µm in a Japanese population. Although age-related choroidal thickness decrease is a finding that is seen in all studies conducted within different ethnic groups, the amount of decrease was found to be different in all studies. This difference may be because of the small size in the study group, different software usage (for the Japanese population), errors in manual choroidal thickness measurements, and racial differences.

In this study, the choroidal thickness was at its thickest in the subfoveal region, thinner at temporal 3 mm region, and thinnest at the nasal 3 mm in the Turkish population. Margolis and Spaide reported that choroidal thickness decreases from the subfoveal region to the temporal and nasal regions (5). Different studies conducted in different ethnicities support this difference in the choroidal thickness (7).

In our study, the mean subfoveal, nasal, and temporal choroidal thicknesses were found to be 326, 179, and 240 µm, respectively. Margolis and Spaide reported that the

subfoveal choroidal thickness in healthy individuals was 287  $\mu\text{m}$ , while Ikuno et al. reported a thickness of 354  $\mu\text{m}$ , and Li et al. a thickness of 342  $\mu\text{m}$  (5–7). The fact that the choroidal thickness in our population was found to be thicker compared to the study of Margolis and Spaide may be explained by our study group's being 20 years younger on average. When our study group is compared to a study group that assesses the choroidal thickness in a healthy Japanese population (6), it is seen that the Japanese group consists of individuals that are older, more myopic, and having eyes with longer axial lengths. When all these factors are taken into account, it is thought that this study had to yield lower choroidal thickness values when compared to our study, although the subfoveal choroidal thickness in healthy Japanese subjects was found to be approximately 30  $\mu\text{m}$  thicker than in our study group. This may be because of ethnic differences or the different kind of instruments used. The choroidal thickness in a healthy Danish population was found to be a little thicker than in our group (7). This is a normal outcome since the Danish study group was an average of 10 years younger than our study group.

There were no statistically significant differences in subfoveal choroidal thickness between male and female subjects in our study. On the other hand, in studies conducted in a healthy Danish population, male choroidal thickness was found to be greater than that of females (7). This difference may depend on the AXL of the male

subjects being longer than that of female subjects in our study, and choroidal thickness is negatively correlated to AXL. Estrogen receptors have been found in the human RPE, and estrogen provides an antioxidant effect by inhibiting lipid peroxidation. Related studies revealed that patients exposed to estrogen due to hormone replacement therapy or pregnancy had increased incidence of AMD (18–22). Pathogenesis of AMD is multifactorial and choroidal thickness might be playing a role in this broad pathogenetic cycle of the disease.

This study has some limitations. To start with, we did not have a device that measures choroidal thickness automatically like the way it measures retinal thickness. Therefore, this measurement was done manually. Moreover, AXL measurements of the eyes were also done manually. In both cases, there may be measurement errors, and this may affect the outcome.

In conclusion, the choroidal thickness in the Turkish population has a similar range in accordance with the studies conducted previously. Subfoveal choroidal thickness may differ among populations. Subfoveal choroidal thickness shows negative correlations with age and with SE and AXL values. The decreases in choroidal thickness by age vary according to the populations. Due to the antioxidant effect of estrogen in women, choroidal thickness is decreased in women compared to men, but choroidal thickness might be playing a role in the broad pathogenetic cycle of some diseases.

## References

1. Wangsa-Wirawan ND, Linsenmeier RA. Retinal oxygen: fundamental and clinical aspects. *Arch Ophthalmol* 2003; 121: 547–57.
2. Yu DY, Cringle SJ. Oxygen distribution and consumption within the retina in vascularised and avascular retinas and in animal models of retinal disease. *Prog Retin Eye Res* 2001; 20: 175–208.
3. Reiner A, Del Mar N, Zagvazdin Y, Li C, Fitzgerald ME. Age-related impairment in choroidal blood flow compensation for arterial blood pressure fluctuation in pigeons. *Invest Ophthalmol Vis Sci* 2011; 52: 7238–47.
4. De Moraes CG, Reis AS, Cavalcante AF, Sano ME, Susanna R Jr. Choroidal expansion during the water drinking test. *Graefes Arch Clin Exp Ophthalmol* 2009; 247: 385–9.
5. Margolis R, Spaide RF. A pilot study of enhanced depth imaging optical coherence tomography of the choroid in normal eyes. *Am J Ophthalmol* 2009; 147: 811–5.
6. Ikuno Y, Kawaguchi K, Nouchi T, Yasuno Y. Choroidal thickness in healthy Japanese subjects. *Invest Ophthalmol Vis Sci* 2010; 51: 2173–6.
7. Li XQ, Larsen M, Munch IC. Subfoveal choroidal thickness in relation to sex and axial length in 93 Danish university students. *Invest Ophthalmol Vis Sci* 2011; 52: 8438–41.
8. Imamura Y, Fujiwara T, Margolis R, Spaide RF. Enhanced depth imaging optical coherence tomography of the choroid in central serous chorioretinopathy. *Retina* 2009; 29: 1469–73.
9. Jirattanasopa P, Ooto S, Nakata I, Tsujikawa A, Yamashiro K, Oishi A et al. Choroidal thickness, vascular hyperpermeability, and complement factor H in age-related macular degeneration and polypoidal choroidal vasculopathy. *Invest Ophthalmol Vis Sci* 2012; 53: 3663–72.
10. Park SC, De Moraes CG, Teng CC, Tello C, Liebmann JM, Ritch R. Enhanced depth imaging optical coherence tomography of deep optic nerve complex structures in glaucoma. *Ophthalmology* 2012; 119: 3–9.
11. Grossniklaus HE, Green WR. Choroidal neovascularization. *Am J Ophthalmol* 2004; 137: 496–503.
12. Gomi F, Tano Y. Polypoidal choroidal vasculopathy and treatments. *Curr Opin Ophthalmol* 2008; 19: 208–12.
13. Spaide RF, Hall L, Haas A, Campeas L, Yannuzzi LA, Fisher YL et al. Indocyanine green videoangiography of older patients with central serous chorioretinopathy. *Retina* 1996; 16: 203–13.

14. Kim YM, Yoon JU, Koh HJ. The analysis of lacquer crack in the assessment of myopic choroidal neovascularization. *Eye* 2011; 25: 937–46.
15. Dündar S, Özcura F, Meteoglu İ, Kara ME. Effects of long-term passive smoking on the vascular endothelial growth factor and apoptosis marker expression in the retina and choroid: an experimental study. *Turk J Med Sci* 2012; 42: 377–83.
16. Mori K, Horie-Inoue K, Gehlbach PL, Takita H, Kabasawa S, Kawasaki I et al. Phenotype and genotype characteristics of age-related macular degeneration in a Japanese population. *Ophthalmology* 2010; 117: 928–38.
17. Klein R, Klein BE, Knudtson MD, Wong TY, Cotch MF, Liu K et al. Prevalence of age-related macular degeneration in 4 racial/ethnic groups in the multi-ethnic study of atherosclerosis. *Ophthalmology* 2006; 113: 373–80.
18. Giddabasappa A, Bauler M, Yepuru M, Chaum E, Dalton JT, Eswaraka J. 17- $\beta$  estradiol protects ARPE-19 cells from oxidative stress through estrogen receptor- $\beta$ . *Invest Ophthalmol Vis Sci* 2010; 51: 5278–87.
19. Zhang HB, Sun NX, Liang HC, Xiao XH, Liu XN, Wang YN. 17-Alpha-estradiol ameliorating oxygen-induced retinopathy in a murine model. *Jpn J Ophthalmol* 2012; 56: 407–15.
20. Snow KK, Cote J, Yang W, Davis NJ, Seddon JM. Association between reproductive and hormonal factors and age-related maculopathy in postmenopausal women. *Am J Ophthalmol* 2002; 134: 842–8.
21. Seitzman RL, Mangione C, Ensrud KE, Cauley JA, Stone KL, Cummings SR et al. Postmenopausal hormone therapy and age-related maculopathy in older women. *Ophthalmic Epidemiol* 2008; 15: 308–16.
22. Owen CG, Jarrar Z, Wormald R, Cook DG, Fletcher AE, Rudnicka AR. The estimated prevalence and incidence of late stage age related macular degeneration in the UK. *Br J Ophthalmol* 2012; 96: 752–6.