

## New hemostatic agent: the effect of Ankaferd Blood Stopper on healing wounds in experimental skin incision model

Serdar YÜCE<sup>1\*</sup>, Celal ÇANDIRLI<sup>2</sup>, Sibel YENİDÜNYA<sup>3</sup>, Bünyamin MUSLU<sup>4</sup>

<sup>1</sup>Department of Plastic, Reconstructive, and Aesthetic Surgery, Faculty of Medicine, Yüzüncü Yıl University, Van, Turkey

<sup>2</sup>Department of Oral and Maxillofacial Surgery, Faculty of Dentistry, Karadeniz Technical University, Trabzon, Turkey

<sup>3</sup>Department of Pathology, Faculty of Medicine, Turgut Özal University, Ankara, Turkey

<sup>4</sup>Department of Anesthesia, Faculty of Medicine, Turgut Özal University, Ankara, Turkey

Received: 21.02.2013 • Accepted: 22.04.2013 • Published Online: 15.01.2014 • Printed: 14.02.2014

**Aim:** To conduct a histopathological evaluation of the effects of Ankaferd Blood Stopper (ABS) on healing wounds in a rabbit skin incision model.

**Materials and methods:** Incisions were performed on the backs of rabbits. The first incision was allowed to undergo normal secondary healing. ABS (1 mL) was applied to the second incision, which was subsequently allowed to undergo secondary healing. The third incision was sutured. ABS (1 mL) was applied to the fourth incision, which was subsequently sutured. During the wound healing period, the histopathologic signs of ulceration, inflammation, the proliferative phase, and the extent of early remodeling were comparatively evaluated by performing biopsies on days 5, 10, and 30.

**Results:** For all of the ABS-treated wounds, the appearance of the cavities during the early stage and the disappearance of the cavities during the late stage were observed. In addition, on days 5–10, the inflammatory granulation tissue in the ABS-treated wounds was less than in the normal wounds. By day 30, all of the wounds had achieved the same symptomatic state.

**Conclusion:** As ABS does not exert any negative effects on wound healing, this agent is a secure and effective method for achieving hemostasis.

**Key words:** Hemostatic agent, wound healing, skin incision

### 1. Introduction

Ankaferd Blood Stopper (ABS) is a hemostatic agent that consists of a mixture of plants that have been used traditionally in Anatolia for several centuries. The agent is a standard mixture of 5 plants: *Thymus vulgaris*, *Glycyrrhiza glabra*, *Vitis vinifera*, *Alpinia officinarum*, and *Urtica dioica*. Each of these plants exerts effects on endothelial cells, blood cells, angiogenesis, cell proliferation, vascular dynamics, and/or cell mediators. The basic mechanism of ABS involves the formation of encapsulated protein bonds, which are the foci of erythrocyte aggregation (1–6). ABS has been successfully used in many clinical cases (e.g., skin, mucous membrane bleeding, GIS bleeding, and nose bleeds) as a hemostatic agent. The aim of this study was to histopathologically evaluate the effect of ABS, which is used in many surgical fields, on wound healing in a rabbit skin incision model.

### 2. Materials and methods

This study was approved by the ethics committee of Fatih University. In this experimental investigation, 6 young New Zealand white rabbits were utilized; each animal was approximately 1 year old and weighed 2.5–3.0 kg. The rabbits were anesthetized using ketamine hydrochloride (35 mg/kg) and xylazine (5 mg/kg) intramuscularly for sedation. Four 10-cm vertical skin incisions with 5-cm separations were made on the back of each rabbit. Subsequently, the first incision was allowed to undergo secondary healing. After the application of 1 mL of ABS, the second incision was allowed to undergo secondary healing. The third incision was sutured with a silk suture. After the application of 1 mL of ABS, the fourth incision was sutured with a silk suture. After surgery, on days 5, 10, and 30, 3-cm pieces were excised from each incision under ketamine anesthesia. Subsequent to staining with hematoxylin and eosin, the collected specimens were

\* Correspondence: yuceserdar23@yahoo.com

evaluated by a single pathologist under 40× and 100× magnifications. During the wound-healing period, during which biopsy samples were collected on days 5, 10, and 30, the histopathologic signs of ulceration, inflammation, the proliferative phase, and the extent of early remodeling were comparatively evaluated.

The inflammatory phase and the inflammatory cell infiltration density were evaluated in the biopsy samples that were collected on day 5. The signs of hemostasis (i.e. vasoconstriction/vasodilation and thrombus formation) were not histopathologically evaluated in the biopsy samples. During proliferative-phase ulceration and reepithelialization, the presence of fibroplasia and angiogenic components with inflammatory granulation-tissue formation, the extent of wound healing, and the effect of wound contraction on the tissue defect were comparatively evaluated. In the biopsy samples that were collected on day 30 and displayed signs of early remodeling, the newly formed collagen was compared to the normal collagen, and the rate of transition to fibroid collagen was comparatively evaluated.

### 3. Results

#### 3.1. The findings on day 5

##### 3.1.1. Open wound

A normal level of edema was seen. Greater levels of epithelialization and smaller defect areas compared with the ABS-treated open wound were observed. Dense inflammatory cell infiltration and more vascular proliferation were found. Inflammation granulation tissue covering a large space, with cell infiltration and vascular proliferation evident, was seen.

##### 3.1.2. ABS-treated open wound

Tubular spaces were present, the defect area was large, and the inflammation and vascular proliferations were slight. The inflammation cell infiltration was slight, the distance between the normal collagen fibers and the ulceration area was small, and the thickness of the inflammatory granulation tissue in this area was less. Lower levels of edema, fibrosis, and vascular proliferation were observed. There was partial epithelialization, with preservation of the anatomic space.

##### 3.1.3. Sutured wound

Normal progress of wound healing, incomplete epithelialization, and higher levels of inflammatory cell infiltration, edema, vasodilation, congestion, erythrocyte extravasation, and fibroplasias were seen. The presence of vascular proliferation and angiogenesis was observed.

##### 3.1.4. ABS-treated sutured wound

The inflammation was slight, and edema was evident in the wound area; however, insufficient inflammatory cell infiltration was observed. The extent of fibroplasia

and angiogenesis was not sufficient in the inflammatory granulation tissue. The epithelialization was incomplete, and the edema and ABS that filled the defect area, which lacked epithelialization, caused a crater-like space. Also observed were a thin, edematous area with sparse inflammatory cell infiltration and a neighboring area presenting normal collagen fibers in the dermis of the surrounding wound (Figure 1). There was a slight inflammatory cell infiltration within a thin area between the edema liquid and the collagen fibers, which consisted of greater levels of inflammatory cell infiltration, edema, and fibrosis when compared to the untreated state.

#### 3.2. The findings on day 10

##### 3.2.1. Open wound

Ulceration, incomplete epithelialization, and dense inflammatory granulation tissue were observed.

##### 3.2.2. ABS-treated open wound

Sparse inflammatory granulation tissue and partial but sufficient epithelialization were observed.

##### 3.2.3. Sutured wound

Dense inflammatory granulation tissue (i.e. inflammatory cell infiltration, fibroblastic proliferation, and neovascularization) and the presence of epithelialization were seen.

##### 3.2.4. ABS-treated sutured wound

Complete epithelialization, hyperkeratosis, parakeratosis, and hyperplasia were present in the epidermis. Edema, fibrosis, and mixed-type inflammatory cell infiltration were present in the outer dermis. The levels of neovascularization, fibrosis, and inflammatory cell infiltration were lower compared with day 5 (Figure 2).

#### 3.3. The findings on day 30

##### 3.3.1. Open wound

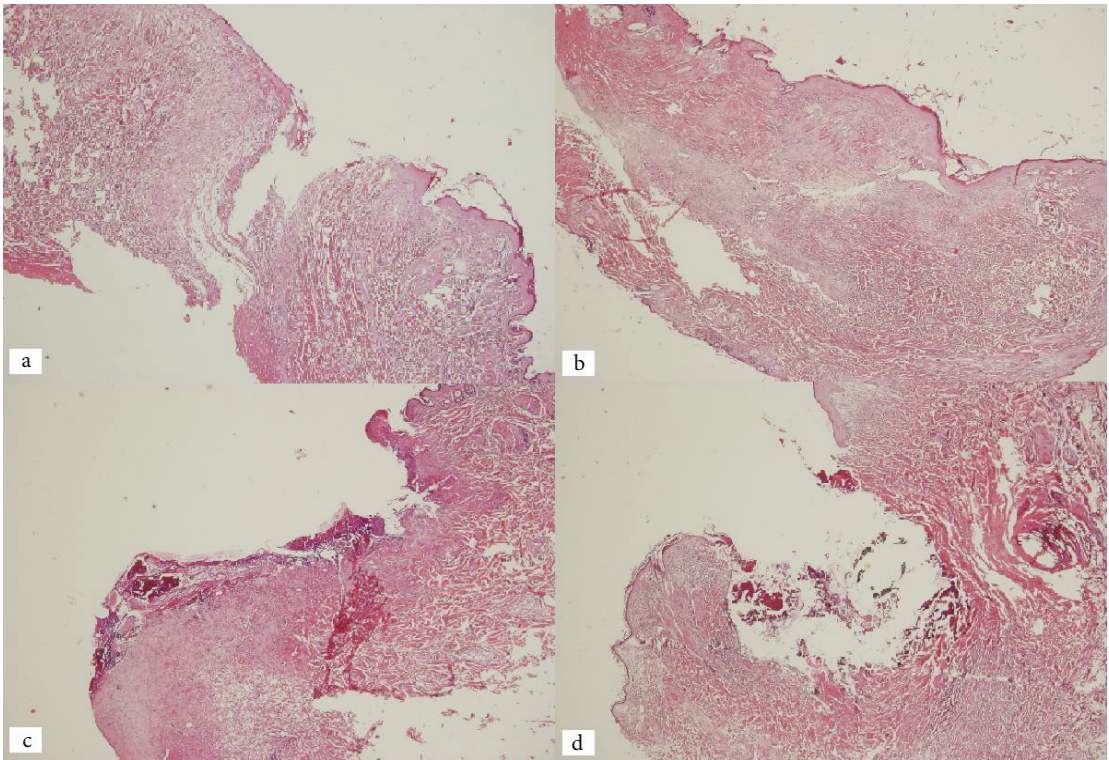
A complete but thin layer of epithelialization (no hyperplasia) was present. Degradation of the inflammatory cell and the vascular component of the inflammatory granulation tissue (continuous fibrosis with no degradation) were seen. The presence of slight depressions (caused by fibrosis) on the wound surface in some of the samples and aberrant healing were also seen.

##### 3.3.2. ABS-treated open wound

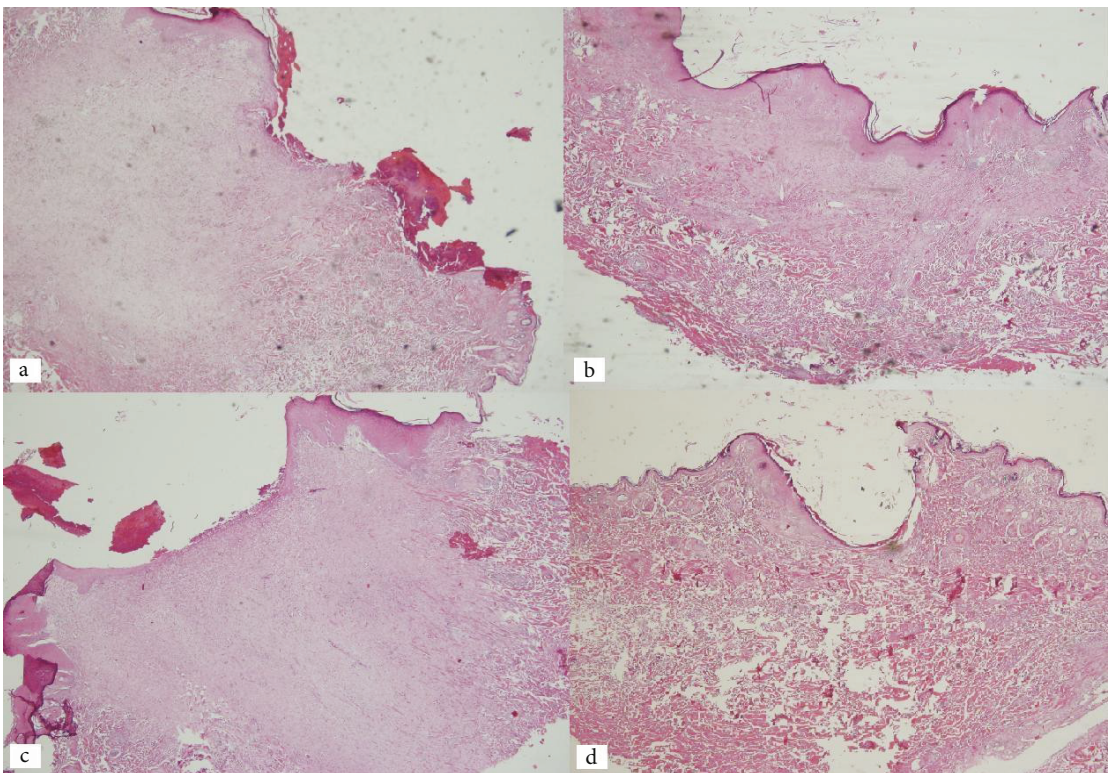
The epithelialized layer was thin and complete, with no hyperplasia. The inflammatory cell and vascular components of the inflammatory granulation tissue were degraded, and the fibrosis was continuous, with no degradation. In some of the samples, a slight depression (caused by fibrosis) was found on the wound surface, and aberrant healing was observed.

##### 3.3.3. Sutured wound

The epithelialization was complete, with a normal thickness and no hyperplasia. Minimal amount of inflammatory



**Figure 1.** The findings on day 5: a) open wound, b) ABS-treated open wound, c) sutured wound, and d) ABS-treated sutured wound.



**Figure 2.** The findings on day 10: a) open wound, b) ABS-treated open wound, c) sutured wound, and d) ABS-treated sutured wound.

granulation tissue was observed. Fibrous collagen, with degradation of the vascularization, was found.

#### 3.3.4. ABS-treated sutured wound

Complete epithelialization, with a normal thickness and no hyperplasia, was seen. Minimal amounts of inflammatory granulation tissue and fibrous collagen, with degradation of the vascularization, were found (Figure 3; Table).

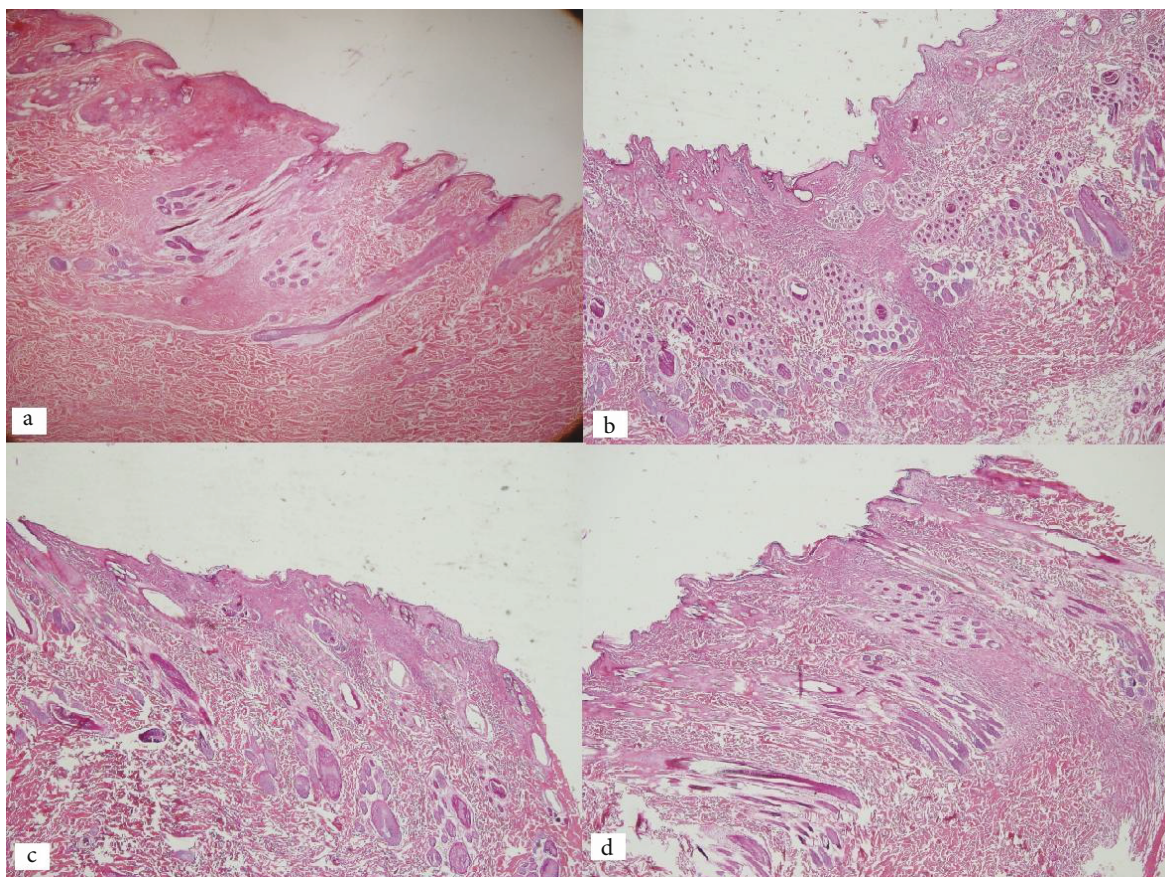
During the early stages, it was macroscopically observed that the protein tissue formed by the ABS preparation prevented contraction of the wound. However, this effect disappeared during the late stages, and all of the wounds exhibited the same progression.

It was observed microscopically that the ABS-treated wounds displayed cavities (caused by the ABS treatment) during the early stages, whereas these cavities disappeared during the late stages. In addition, the amount of inflammatory granulation tissue on days 5 and 10 was less than in untreated wounds, whereas on day 30, all of the wounds were observed to be in the same condition. This finding might indicate that ABS reduces scar development during the later stages of wound healing. This hypothesis should be tested by performing longer studies with animal models.

#### 4. Discussion

ABS is a medicine that is used as a hemostatic agent and that consists of a standard mixture of 5 plants: *Thymus vulgaris* (0.05 mg/mL), *Glycyrrhiza glabra* (0.07 mg/mL), *Vitis vinifera* (0.08 mg/mL), *Alpinia officinarum* (0.07 mg/mL), and *Urtica dioica* (0.06 mg/mL). Each of these plants exerts effects on the endothelium, blood cells, angiogenesis, cell proliferation, vascular dynamics, and/or cell mediators (1–6).

For example, *G. glabra* inhibits angiogenesis, decreases vascular endothelial growth factor production, and inhibits cytokine-induced neovascularization (7). *T. vulgaris* exhibits varying levels of antioxidant activity, which may help to prevent in vivo oxidative damage, such as lipid peroxidation associated with atherosclerosis (8). *V. vinifera* has an antiatherosclerotic effect (6). *A. officinarum* inhibits nitric oxide production in lipopolysaccharide-activated mouse peritoneal macrophages (9). *U. dioica* produces hypotensive responses via a vasorelaxation effect that is mediated by the release of endothelial nitric oxide, the opening of potassium channels, and a negative inotropic action (10).



**Figure 3.** The findings on day 30: a) open wound, b) ABS-treated open wound, c) sutured wound, and d) ABS-treated sutured wound.

**Table.** The histopathologic signs of ulceration, inflammation, the proliferative phase, and the early remodeling stages on days 5, 10, and 30 (A+S: ABS-treated sutured wound; S: sutured wound; A+OW: ABS-treated open wound; OW: open wound; P: partial; c: complete).

Day	Group	Ulceration		Reepithelialization	Clearance of debris	Granulation tissue and angiogenesis			Remodeling phase	
		Ulcer	Epithelialization			Inflammation	Angiogenesis	Fibrosis*	Appearance of fibrillar collagen	Aberrant healing
5	A+S	++	Nonexistent	Not	-	-	-	-	-	-
	S	-	P ++	Completed	+++	++	-	-	-	-
	A+OW	+++	Nonexistent	Not	-	-	-	-	-	-
	OW	++	P +	Not	+++	+++	-	-	-	-
10	A+S	-	c	Completed	+	+	+	+	-	-
	S	-	c	Completed	++	+++	++	++	-	-
	A+OW	+	P +	Not	+	+	+	+	-	-
	OW	+	P +	Not	+++	++	+++	+++	-	-
30	A+S	-	c	Completed	+	+	+	+	++	-
	S	-	c	Completed	+	+	+	+	++	-
	A+OW	-	c	Completed	+	+	++	++	+	+
	OW	-	c	Completed	+	+	+++	+++	+	+

\*: Fibroblast proliferation and matrix production.

Several previous reports studied the mechanism behind the effects of ABS. They showed that when ABS is added to serum or plasma, the agent induces the rapid aggregation of erythrocytes and the formation of proteins. As observed by electron microscopy, ABS aggregates blood cells, especially erythrocytes and active leukocytes. The basic mechanism of ABS involves the formation of encapsulated proteins, which serve as foci of erythrocyte aggregation (1–6).

As demonstrated by in vitro tests, ABS does not affect coagulation factors 2, 5, 7, 8, 9, 10, 11, and 13. Furthermore, the prothrombin time and the active partial thromboplastin time are normal. The activation of plasma fibrinogen decreases, and the fibrinogen antigen levels decrease with an extension of the thrombin time. In addition, the total protein, albumin, and globulin levels decrease (1–6).

ABS is a local hemostatic agent, and this group of agents, called topical hemostatics and blood stoppers, are generally employed for minor bleeding rather than for major injuries. The mechanism of these medicaments is to provide oscillation of natural hemostatic agents, either by activating thrombocytes or as an external substance. Some agents act by different mechanisms, such as adhesion to fibrous structures or vasoconstriction (e.g., adrenalin)

(1). ABS is unlike the other hemostatic agents because its mechanism is to form a protein network and to promote erythrocyte aggregation. By contrast, ABS does not cause external substance reactions or thrombocyte activation (1). Because of this property, ABS is effective not only in normal hemostatic patients, but also in patients who have primary and secondary hemostasis defects (1–3).

Antibacterial activity is an unexpected effect of ABS because it provides high levels of oxygenation due to erythrocyte aggregation. Moreover, ABS exhibits a high level of inhibitory activity towards gram-positive and gram-negative bacteria (2). The antibacterial activities of the plants that constitute ABS were examined, and it was observed that *T. vulgaris* displays bacteriostatic activity towards gram-positive and gram-negative bacteria. In addition, *G. glabra*, *V. vinifera*, and *A. officinarum* display antibacterial effects. *U. dioica* exerts antibacterial effects towards *Streptococcus pyogenes*, *Staphylococcus aureus*, and *Staphylococcus epidermidis*. Plant extracts are generally effective towards gram-positive bacteria, and ABS is effective towards gram-negative bacteria because of the synergistic combination (4).

The hemostatic effects of ABS were demonstrated through various animal experiments. Kosar et al. reported that ABS treatment reduces bleeding in both warfarin-

treated and nontreated rats with bleeding resulting from amputated legs. In a similar study, it was observed that using ABS reduces the quantity of blood and duration of bleeding (11). Bilgili et al. demonstrated that sprays, tampons, and solutions successfully controlled bleeding on surface and deep abdominal cuts in swine bleeding models (12). Using an animal model, Kose et al. demonstrated that ABS is a potent hemostatic agent for cutaneous bleeding resulting from surgical skin defects (13).

The effects of ABS in preventing liver lacerations, partial nephrectomies, air leakage into the lung, and bleeding have been demonstrated via animal studies (14–17). In another animal study, İşler et al. reported that ABS causes new bone formation and reductions in necrosis and inflammation in a rat tibial defect model (18).

The hemostatic effect of ABS has been demonstrated in several different human studies. In many patients with dental problems, ABS was effectively used when efficient hemostasis was required (2). Teker et al. achieved good results in reducing hemorrhages, shortening the surgical duration, and reducing complications by using ABS after tonsillectomies (19). In another study, the researchers reported that the treatment of anterior epistaxis using

ABS is an effective, secure, rapid, and simple alternative (20). ABS has been successfully used to treat peptic ulcers, GIS neoplasms, Mallory Weiss syndrome, bleeding varices, rectal ulcers, fundal varices, colitis radiation, and postpolypectomy rectal ulcers that cause bleeding (21–23).

Al et al. compared using ABS and tampons for hemostasis while inserting ports in patients with cancer. They found that ABS stops bleeding within a shorter time and causes fewer bleeding relapses (24). In another study, Huri et al. used ABS on patients undergoing retroperitoneal radical prostatectomy and reported that the treatment provides efficient hemostasis (25). Guler et al. compared conventional methods and ABS for controlling bleeding during total thyroidectomy. The results demonstrated that ABS is more effective in reducing the operation time, postoperative drainage quantity and duration, and complications (26).

The results of our investigation demonstrate that ABS is a safe medicine, does not exert any negative effects on wound healing, and can be confidently used as a hemostatic agent. However, the effects of ABS on scar development must be evaluated in long-term studies.

## References

1. Aysan E, Bektas H, Ersoz F, Sari S, Kaygusuz A, Huq GE. Ability of the ankaferd blood stopper® to prevent parenchymal bleeding in an experimental hepatic trauma model. *Int J Clin Exp Med* 2010; 3: 186–91.
2. Beyazit Y, Kurt M, Kekilli M, Goker H, Haznedaroglu IC. Evaluation of hemostatic effects of Ankaferd as an alternative medicine. *Altern Med Rev* 2010; 15: 329–36.
3. Beyazit Y, Kekilli M, Haznedaroglu IC, Kayacetin E, Basaranoglu M. Ankaferd hemostat in the management of gastrointestinal hemorrhages. *World J Gastroenterol* 2011; 17: 3962–70.
4. Tasdelen Fisgin N, Tanriverdi Cayci Y, Coban AY, Ozatli D, Tanyel E, Durupinar B, Tulek N. Antimicrobial activity of plant extract Ankaferd Blood Stopper. *Fitoterapia* 2009; 80: 48–50.
5. Kandemir O, Buyukates M, Kandemir NO, Aktunc E, Gul AE, Gul S, Turan SA. Demonstration of the histopathological and immunohistochemical effects of a novel hemostatic agent, Ankaferd Blood Stopper, on vascular tissue in a rat aortic bleeding model. *J Cardiothorac Surg* 2010; 5: 110.
6. Goker H, Haznedaroglu IC, Ercetin S, Kirazli S, Akman U, Ozturk Y, Firat HC. Haemostatic actions of the folkloric medicinal plant extract Ankaferd Blood Stopper. *J Int Med Res* 2008; 36: 163–70.
7. Sheela ML, Ramakrishna MK, Salimath BR. Angiogenic and proliferative effects of the cytokine VEGF in Erlich ascites tumor cells is inhibited by *Glycyrrhiza glabra*. *Int Immunopharmacol* 2006; 6: 494–8.
8. Lee SJ, Umamo K, Shibamoto T, Lee KG. Identification of volatile components in basil (*Ocimum basilicum* L.) and thyme leaves (*Thymus vulgaris* L.) and their antioxidant properties. *Food Chem* 2005; 91: 131–7.
9. Matsuda H, Ando S, Kato T, Morikawa T, Yoshikawa M. Inhibitors from the rhizomes of *Alpinia officinarum* on production of nitric oxide in lipopolysaccharide activated macrophages and the structural requirements of diarylheptanoids for activity. *Bioorg Med Chem* 2006; 14: 138–42.
10. Testai L, Chericoni S, Calderone V, Nencioni G, Nieri P, Morelli I, Martinotti E. Cardiovascular effects of *Urtica dioica* L. (Urticaceae) roots extracts: in vitro and in vivo pharmacological studies. *J Ethnopharmacol* 2002; 81: 105–9.
11. Kosar A, Cipil HS, Kaya A, Uz B, Haznedaroglu IC, Goker H, Ozdemir O, Ercetin S, Kirazli S, Firat HC. The efficacy of Ankaferd Blood Stopper in antithrombotic drug-induced primary and secondary hemostatic abnormalities of a rat-bleeding model. *Blood Coagul Fibrin* 2009; 20: 185–90.
12. Bilgili H, Kosar A, Kurt M, Onal IK, Goker H, Captug O, Shorbagi A, Turgut M, Kekilli M, Kurt OK et al. Hemostatic efficacy of Ankaferd Blood Stopper in a swine bleeding model. *Med Princ Pract* 2009; 18: 165–9.
13. Kose R, Sogut O, Demir T, Koruk I. Hemostatic efficacy of folkloric medicinal plant extract in a rat skin bleeding model. *Dermatol Surg* 2012; 38: 760–6.

14. Kılıçgün A, Sarıkış NG, Korkmaz T, Saydam Ö, Boran Ç, Boztaş G. Effect of Ankaferd Blood Stopper on air leakage in the lung and prevention of bleeding: an experimental study. *J Cardiothorac Surg* 2011; 6: 20.
15. Kilic O, Gonen M, Acar K, Yurdakul T, Avunduk MC, Esen HH, Oz M. Haemostatic role and histopathological effects of a new haemostatic agent in a rat bladder haemorrhage model: an experimental trial. *BJU Int* 2010; 105: 1722–5.
16. Huri E, Akgül T, Ayyıldız A, Ustün H, Germiyanoglu C. Hemostatic role of a folkloric medicinal plant extract in a rat partial nephrectomy model: controlled experimental trial. *J Urol* 2009; 181: 2349–54.
17. Karakaya K, Ucan HB, Tascilar O, Emre AU, Cakmak GK, Irkorucu O, Ankarali H, Comert M. Evaluation of a new hemostatic agent Ankaferd Blood Stopper in experimental liver laceration. *J Invest Surg* 2009, 22: 201–6.
18. İşler SC, Demircan S, Cakarer S, Cebi Z, Keskin C, Soluk M, Yüzbaşıoğlu E. Effects of folk medicinal plant extract Ankaferd Blood Stopper on early bone healing. *J Appl Oral Sci* 2010; 18: 409–14.
19. Teker AM, Korkut AY, Gedikli O, Kahya V. Prospective, controlled clinical trial of Ankaferd Blood Stopper in children undergoing tonsillectomy. *Int J Pediatr Otorhinolaryngol* 2009; 73: 1742–5.
20. Teker AM, Korkut AY, Kahya V, Gedikli O. Prospective, randomized, controlled clinical trial of Ankaferd Blood Stopper in patients with acute anterior epistaxis. *Eur Arch Otorhinolaryngol* 2010; 267: 1377–81.
21. Kurt M, Akdogan M, Onal IK, Kekilli M, Arhan M, Shorbagi A, Aksu S, Kurt OK, Haznedaroglu IC. Endoscopic topical application of Ankaferd Blood Stopper for neoplastic gastrointestinal bleeding: a retrospective analysis. *Dig Liver Dis* 2010; 42: 196–9.
22. Tuncer I, Doganay L, Ozturk O. Instant control of fundal variceal bleeding with a folkloric medicinal plant extract: Ankaferd Blood Stopper. *Gastrointest Endosc* 2010; 71: 873–5.
23. Zulfikar OB, Emiroglu HH, Kebudi R. Nasogastric application of topical Ankaferd Blood Stopper for bleeding from primary esophageal adenocarcinoma in a child with disseminated intravascular coagulation. *Dig Liver Dis* 2011; 43: 247–8.
24. Al B, Yildirim C, Cavdar M, Zengin S, Buyukaslan H, Kalender ME. Effectiveness of Ankaferd blood stopper in the topical control of active bleeding due to cutaneous-subcutaneous incisions. *Saudi Med J* 2009; 30: 1520–5.
25. Huri E, Akgül T, Ayyıldız A, Germiyanoglu C. Hemostasis in retropubic radical prostatectomy with Ankaferd Blood Stopper: a case report. *Kaohsiung J Med Sci* 2009; 25: 445–7.
26. Guler M, Maralcan G, Kul S, Baskonus I, Yilmaz M. The efficacy of Ankaferd Blood Stopper for the management of bleeding following total thyroidectomy. *J Invest Surg* 2011; 24: 205–10.