

Determining torsion angle of humerus head using MRI method

Ayfer Metin TELLİOĞLU^{1*}, Sacide KARAKAŞ¹, Füsün TAŞKIN²

¹Department of Anatomy, Faculty of Medicine, Adnan Menderes University, Aydın, Turkey

²Department of Radiology, Faculty of Medicine, Adnan Menderes University, Aydın, Turkey

Received: 04.05.2012 • Accepted: 22.10.2013 • Published Online: 27.05.2014 • Printed: 26.06.2014

Background/aim: To measure the torsion angle of the humerus using images obtained via magnetic resonance imaging (MRI) in healthy volunteers and to evaluate outcomes with respect to sex and age groups.

Materials and methods: The study consisted of 36 healthy adults (18 males and 18 females aged between 20 and 68 years). The humeral torsion angle (HTA) was calculated using axial MRI images. Differences between results in terms of sex and age groups were evaluated with the Mann-Whitney U test.

Results: The median HTA was 21.5° (25th to 75th percentile: 7.8°–28°; range: –4° to 36°) in females, while it was 18.5° (25th to 75th percentile: 7.5°–32.3°; range: 2° to 41°) in males. HTA median value was 19.5° (25th to 75th percentile: 8.3°–30.5°; range: –4° to 41°) in all healthy volunteers. No significant differences were found between gender and age groups.

Conclusion: Considering intersocietal anatomic differences, our study may shed light on torsion angle for Turkey by determining mean torsion angle value. Moreover, this study indicated that HTA can be successfully measured using MRI. We think that our outcomes can be used as a reference for prosthesis design and shoulder joint prosthesis replacement. Moreover, we also think that this study will provide benefits in examining pathologies related to the shoulder joint, such as recurrent anterior dislocation syndrome.

Key words: Humerus, torsion angle, magnetic resonance imaging

1. Introduction

Humeral torsion angle (HTA) is the angle between the axis on the proximal articular surface of humerus and the axis on the distal articular surface (or transepicondylar line) (1–4). Torsion of the humerus can be defined as a process of twisting in the proximal end of humerus. Torsion angle can be measured when the axis of the humerus head (line between midsection of the tuberculum majus and the midsection of the caput humeri) and the transepicondylar axis in the distal end of humerus are arranged in a superposing fashion. The first anatomic studies about torsion of the humerus, conducted by Cowgill, focused on the origin and underlying reasons for studies (3). It was assumed that humeral torsion derives from 180° rotation of the radius around the ulna when embryologic rotation of forearm started and current localization and orientation of the humerus occurred during development of the extremity. Several researchers claimed that the HTA was dependent on the shape of the thorax and localization of scapula; most studies suggested that humeral torsion derived from muscle contractions in contrary directions in proximal and distal ends (1–4).

The HTA is around 16° in adults and 60° in neonates (5). Decrease in torsion angle parallel to body growth depends on change in position of scapula. The glenoid cavity of the scapula translocates in an anterior-to-lateral direction during growth. The glenoid cavity largely moves in an anterior direction in neonates, while it moves significantly towards the lateral side in adults. Change in position of the scapula is balanced with a decrease in torsion angle (5).

HTA may have significant intersocietal and even interpersonal differences (6,7). It is important for glenohumeral stability in the shoulder joint (8,9). It is also of significance for prosthesis design and shoulder joint prosthesis replacement in surgical terms. It is necessary to know the HTA in order to determine the best anatomic position for intraoperative placement of a shoulder prosthesis (10,11).

In the current study, we aimed to measure HTA using images obtained via magnetic resonance imaging (MRI), which is an advanced radiologic imaging method, in healthy volunteers and to evaluate outcomes considering sex and age groups.

* Correspondence: ayfertellioglu@yahoo.com

2. Material and methods

Thirty-six healthy adults (18 males and 18 females aged between 20 and 68 years; 18 between the ages of 20 and 40 and 18 above 40 years old) without any complaints or known diseases of the shoulder and arm region were enrolled in the study in order to calculate their HTAs using MRI. Subjects were informed about the study and informed consent was obtained. The study was submitted to the Human Ethics Committee of Adnan Menderes University and the approval of the ethics committee was obtained. Resultant data were analyzed using SPSS 14.0. Differences between results in terms of sex and age groups were evaluated with the Mann–Whitney U test.

All examinations were made using a Signa Hi-Speed 1.5T (General Electric Medical Systems, USA) MRI device. Patients were placed in a supine position with arms located by their sides, palmar surfaces facing upwards, and shoulders and arms immobile. Body wraps were placed around the shoulder and elbow regions. T1W images were obtained on the axial plane after a coronal T1W pilot image was obtained (TR/TE: 500/14, field of view: 18 cm, matrix: 256×256 , number of excitations: 3, slice thickness/gap: 5/1 mm). On the first MRI image, where the posterior section of the glenoid cavity was clearly seen, a line was drawn linking the anterior and posterior margins of the humeral articular cartilage and the line was referred to as Line A. Another line was drawn, perpendicular to A and just on the midpoint, referred to as Line H. Moreover, a third line was drawn, which intersected Lines A and H and lay horizontally on the articular surface. The angle between

Line H and the horizontal line was referred to as α_1 (12) (Figure 1). In axial MRI slice imaging of the distal end of the humerus, the transepicondylar line was marked and referred to as Line E. The angle between Line E and the line horizontally lying on articular surface was referred to as α_2 (Figure 2). The HTA was calculated using the formula ($\alpha_1 - \alpha_2$) (12).

3. Results

Median HTA was 21.5° (25th to 75th percentile: 7.8° – 28° ; range: -4° to 36°) in females, while it was 18.5° (25th to 75th percentile: 7.5° – 32.3° ; range: 2° to 41°) in males. Median HTA was 19.5° (25th to 75th percentile: 8.3° – 30.5° ; range: -4° to 41°) in all healthy volunteers (Table 1). When HTA was compared between female and male subjects, no significant difference was found (Table 2; $P > 0.05$). The median HTA in subjects aged from 20 to 40 years was 24.5° (25th to 75th percentile: 8.5° – 33.3°) and it was 16.5° (25th to 75th percentile: 6.8° – 26.3°) in subjects aged over 40 years. When HTA was compared between subjects aged from 20 to 40 years and subjects older than 40 years, no significant difference was found (Table 3; $P > 0.05$).

4. Discussion

Studies were conducted on the difference in the HTA between species and ethnic groups (6). In a study conducted by Edelson on 336 dry bones known to originate from white Americans, black Americans, New Mexico natives, North China, Alaskan Eskimos, and Bedouins of the Negev Desert, torsion angle was found to range from -8° to 74° .

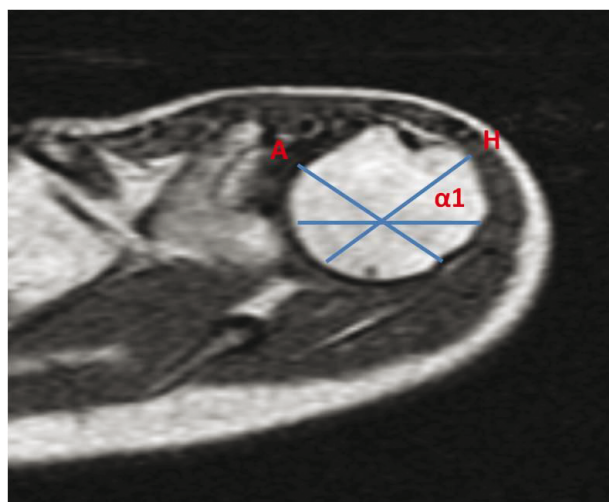


Figure 1. Images were obtained on the axial plane. A line was drawn linking the anterior and posterior margins of humeral articular cartilage and the line was referred to as Line A. Another line was drawn which lay just on the midpoint of, and was perpendicular to, Line A, referred to as Line H. The angle between line H and horizontal line was referred to as α_1 (12).

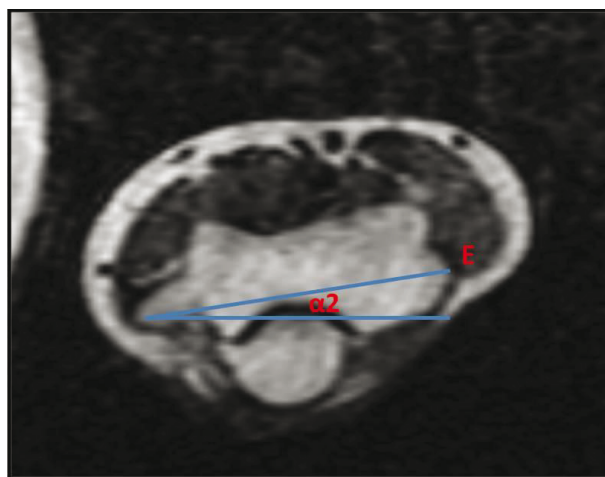


Figure 2. The transepicondylar line was marked and referred to as line E. The angle between the E axis and the line horizontally lying on the articular surface was referred as α_2 . HTA was calculated using axial MRI images [$HTA = (\alpha_1 - \alpha_2)$] (12).

Table 1. Median (25th–75th percentiles), minimum, and maximum values of HTA in males, females, and all groups.

Measurements	Sex	N	Median (25th–75th percentiles)	Min	Max
HTA (°)	Female	18	21.5° (7.8°–28°)	–4°	36°
	Male	18	18.5° (7.5°–32.3°)	2°	41°
	All groups	36	19.5° (8.3°–30.5°)	–4°	41°

Table 2. Comparing HTAs between male and female subjects using the Mann–Whitney U test.

Measurements	Sex	Median (25th–75th percentiles)	P
HTA (°)	Female	21.5° (7.8°–28°)	0.743
	Male	18.5° (7.5°–32.3°)	

Table 3. Comparing HTAs between subjects aged 20–40 years and above 40 years using the Mann–Whitney U test.

Measurements	Age groups	N	Median (25th–75th percentiles)	P
HTA (°)	20–40 years	18	24.5° (8.5°–33.3°)	0.143
	>40 years	18	16.5° (6.8°–26.3°)	

It has been assumed that differences in torsion angle may originate from differences in social genetic structures and physical activities (6).

The measurements performed in Mersin by Öztuna et al. on 14 fetal cadaver humeri (7 pairs) using a photographic technique and 50 dry adult humeri using a special frame design yielded an average humeral torsion angle of 52.8° for the fetuses and 24.9° (9°–47°) for adults (13). In other studies, Öztuna et al. calculated the HTA from 20 bone samples and semiaxial radiography of 40 healthy volunteers. Average HTA was measured as 24° (5°–47°) for the bone samples and 26° (7°–47°) for healthy volunteers. The authors stated that a comparison between the measurements would yield a difference of 0.9° to 3° (14).

In a study conducted by Kronberg et al. in Sweden on 20 patients with recurrent anterior dislocation syndrome, torsion angle was calculated via measurements on semiaxial X-ray graphs and mean HTA was 12° (8). In measurements conducted by Symeonides et al. using computed tomography (CT) images of 38 patients (40 shoulders) with recurrent anterior dislocation syndrome and 40 healthy volunteers, the mean angle was $4.3° \pm 10.56°$ (17° anteversion to 32° retroversion) in the patient group, while it was found to be $16.1° \pm 11.07°$ (0°–49°) in the normal group (9). Both studies indicated that a decrease

in torsion angle (in other words, an anteverted angle) may lead to recurrent anterior dislocation syndrome. Mean torsion angle calculated on healthy volunteers using MRI was $18.1° \pm 12.6°$ (range: –4° to 36°) in females, while it was $19.6° \pm 12.7°$ (range: 2°–41°) in males. Mean HTA values for subjects aged between 20 and 40 years was $21.9° \pm 12.9°$, and it was $15.8° \pm 11.6°$ for subjects aged over 40 years; the mean value for the whole group was $18.9° \pm 12.5°$ (range: –4° to 41°). Our results are similar to the outcomes obtained by Symeonides et al. on healthy volunteers.

HTA is also significant for prosthesis design and shoulder joint prosthesis replacement. It is necessary to know the HTA in order to determine the best anatomic position for intraoperative placement of a shoulder prosthesis (10,11). For facilitating the determination of the best anatomic position in intraoperative placement of shoulder prostheses, Doyle et al. calculated the distance between the axis lying on the proximal articular surface of humerus and the bicipital sulcus using MRI with 41 volunteers and 9 cadavers, and thus they calculated the HTA. Mean bicipital distance was 11.8 ± 3.5 mm and mean HTA was $26.8° \pm 12.2°$ (12). In the current study, the mean value for the whole group was $18.9° \pm 12.5°$ (range: –4° to 41°).

Hernigou et al. demonstrated that determining the torsion range of the humerus would be beneficial in humeri

with fragmented fractures or severe arthritic deformity. Despite a large variation in HTAs, they demonstrated that the variation was very low between the 2 healthy humeral bones of the same subject and the patient's healthy side could be examined as a reference. It was emphasized that each humerus presents the means for the HTA belonging to an individual in the shoulder arthroplasty that was based on the intact side (15).

Cassagnaud et al. performed a study in order to ascertain the method's repeatability in the measurement of the lateralization of the intertubercular groove and humeral retroversion using CT. The authors calculated the average HTA in 32 healthy volunteers (17 females and 15 males between 22 and 44 years of age) as 11.71° on the dominant and 7.03° on the nondominant side. Consequently, they demonstrated that the CT measurement method was repeatable and that such measurements would be useful in shedding light on the pathophysiology of chronic anterior shoulder instability (16).

For patients receiving a shoulder prosthesis, preoperative determination of HTA via radiologic methods is a better approach. However, for patients with bilateral humeral fractures or with unclear bone margins secondary to degenerative arthritis (accordingly, the contralateral side cannot be considered as reference), it is necessary to know mean HTA when the conditions required for determining preoperative torsion angle cannot be met. In the current study, normal values were determined using MRI measurements for measuring HTA in healthy volunteers. Considering intersocietal anatomic differences, our study may give an idea for determining values of torsion angle relevant for Turkey and taking the value as a reference in prosthesis replacement arthroplasties of shoulder joint. Moreover, our outcomes may also offer a tool for making comparisons with regards to evaluations of patients with chronic anterior stability and whether there is angular tendency leading to instability.

References

1. Krahl VE. The phylongely and ontogeny of humeral torsion. *J Phys* 1976; 45: 595–600.
2. Krahl VE, Evens FG. Humeral torsion in man. 1945; 3: 229–253.
3. Cowgill LW. Humeral torsion revisited: a functional and ontogenetic model for populational variation. *Am J Phys Anthropol* 2007; 134: 472–480.
4. Martin CP. The cause of torsion of the humerus and of the notch on the anterior edge of the glenoid cavity of the scapula. *J Anat* 1933; 67: 572–582.
5. Schünke M, Schulte E, Schumacher U, Voll M, Wesker K. *Prometheus Anatomi Atlası* (Yıldırım M, Marur T, translators). 1st ed. İstanbul, Turkey: Nobel Tıp Kitapevleri; 2007 (in Turkish).
6. Edelson G. Variations in the retroversion of the humeral head. *J Shoulder Elbow Surg* 1999; 8: 142–145.
7. Pearl ML, Volk AG. Retroversion of the proximal humerus in relationship to prosthetic replacement arthroplasty. *J Shoulder Elbow Surg* 1995; 4: 286–289.
8. Kronberg M, Broström LA. Rotation osteotomy of the proximal humerus to stabilise the shoulder. *J Bone Joint Surg* 1995; 77: 924–927.
9. Symeonides PP, Hatzokos I, Christoforides J, Pournaras J. Humeral head torsion in recurrent anterior dislocation of the shoulder. *J Bone Joint Surg* 1995; 77: 687–690.
10. Boileau P, Walch G. Adaptability and modularity of shoulder prosthesis. *Maitrise Orthopédique* 2009; 273: 1–9.
11. Hempfing A, Leunig M, Ballmer FT, Hertel R. Surgical landmarks to determine humeral head retroversion for hemiarthroplasty in fractures. *J Shoulder Elbow Surg* 2001; 10: 460–463.
12. Doyle AJ, Burks RT. Comparison of humeral head retroversion with the humeral axis/biceps groove relationship: a study in live subject and cadavers. *J Shoulder Elbow Surg* 1998; 7: 453–457.
13. Öztuna V, Eskandari MM, Öztürk H, Milcan A, Kuyurtar F. Humerus proksimal eklem yüzünün torsiyon profili: kadavra humeruslarında yapılan anatomik ölçüm sonuçları. *Acta Orthop Traumatol Turc* 2001; 35: 260–264 (in Turkish).
14. Öztuna V, Öztürk H, Eskandari MM, Kuyurtar F. Measurement of the humeral head retroversion angle: a new radiographic method. *Acta Orthop Trauma Surg* 2002; 122: 406–409.
15. Hernigou P, Duparc F. Determining humeral retroversion with computed tomography. *J Bone Joint Surg* 2002; 84: 1753–1762.
16. Cassagnaud X, Maynaud C, Petroff E, Dujardin C, Mestdagh H. A study of reproducibility of an original method of CT measurement of the lateralization of the intertubercular groove and humeral retroversion. *Surg Radiol Anat* 2003; 25: 145–151.