

The effect of lateral internal sphincterotomy on resting anal sphincter pressures*

Kemal PEKER^{1**}, İsmayil YILMAZ¹, İsmail DEMİRİYLMAZ², Abdullah İNAL¹, Arda IŞIK¹

¹Department of General Surgery, Faculty of Medicine, Erzincan University, Erzincan, Turkey

²Department of General Surgery, Faculty of Medicine, İbni Sina Hospital, Kayseri, Turkey

Received: 24.07.2013 • Accepted: 18.09.2013 • Published Online: 27.05.2014 • Printed: 26.06.2014

Background/aim: Anal fissures are one of the most common proctologic disorders. This study aimed to investigate alterations in anal sphincteric resting pressures after lateral internal sphincterotomy, which was performed for chronic anal fissure treatment.

Materials and methods: Fifty-six (68.3%) male and 26 (31.7%) female patients were included in this study. Patients complicated with fistula-in-ano, abscess, cancer, inflammatory bowel disease, dermatitis, poor general condition, allergy to any of the standard medications, previous history of anal trauma, previous anal surgery, or diagnosis of a neurological disease and patients who did not give consent to the trial were excluded from the study. Two groups were formed: a control group with 41 healthy volunteers and a study group with 41 chronic anal fissure patients. Preoperative and postoperative manometric anal measurements were compared.

Results: Preoperative mean resting anal sphincter pressure was 51.29 mmHg for the control group and was 59.99 mmHg for the patient group. Although resting anal sphincteric pressures of the patient group remained within the physiological range, when compared with the control group there was a statistically significant difference. Postoperative mean resting anal sphincteric pressures of the patient group was 32.43 mmHg.

Conclusion: Lateral internal sphincterotomy decreases resting anal sphincter pressures effectively in chronic anal fissure patients.

Key words: Lateral internal sphincterotomy, anal fissure, manometry, anal sphincter pressures

1. Introduction

Anal fissures, one of the most common proctologic disorders, appear on the distal part of the anal canal. An anal fissure is a vertical mucosal tear that is lined with squamous epithelium, which causes severe pain during and after defecation (1). Although it may affect people of all ages, mainly young and middle-aged patients suffer from the disease, which is distributed among both sexes at the same ratio (2). The condition manifests itself as bleeding and anal pain during defecation. Solid stools and high anal sphincteric pressures have usually been accepted as etiological factors (3).

Treatment options vary from local medical applications to surgical sphincterotomy. The object in anal fissure treatment is to get rid of, or at least to reduce, the spasm in the anal sphincter. If an anal fissure is left untreated, complications will normally ensue and the patient's quality of life eventually declines (4). Although many studies suggest that the etiology of anal fissure has an ischemic origin and anal fissures may be healed with the

reduction of anal sphincteric pressure either chemically or surgically, surgical treatment remains the principal treatment for chronic, intractable cases. Currently, among numerous other defined surgical techniques, lateral internal sphincterotomy (LIS) is the most frequently performed procedure for the treatment of anal fissures (5). Although a decrease in anal sphincteric pressure is the desired outcome of the procedure, an incompetent anal sphincter complex may result in anal incontinence. Thus, the amount of decrease in anal sphincteric pressure after surgical sphincterotomy is critical (6). This study investigated changes in anal sphincteric resting pressures after LIS, which was performed for chronic anal fissure treatment.

2. Materials and methods

A prospective controlled clinical study was conducted at Mengücek Gazi Training and Research Hospital in Erzincan, Turkey, between September 2012 and May 2013. This study was approved by the ethics committee

* This study was presented at the 14th Congress of Colorectal Surgery, Antalya, Turkey, 2013.

** Correspondence: k.peker@yahoo.com.tr

of Erzincan University and performed in accordance with the Declaration of Helsinki. All patients were asked to provide written informed consent prior to enrollment, after an explanation of the associated risks and benefits and a description of the study protocol. Considering the effect of ageing in anal sphincteric pressures (7), 82 nonseñile patients were included in the study. Patients complicated with fistula-in-ano, abscess, cancer, inflammatory bowel disease, dermatitis, poor general condition, allergy to any of the standard medications, previous history of anal trauma, previous anal surgery, or diagnosis of a neurological disease and patients who did not give consent to the trial were excluded from the study. Two groups were formed. The first group was the control group (G1) with 41 healthy volunteers without any prior proctologic disorder or history of anal surgery, and the second group (G2) was composed of 41 chronic anal fissure patients who were chosen to have surgical treatment. Conditions that did not respond to medical treatment for 6–8 weeks and the appearance of internal anal sphincter muscle fibers on the base of the anal fissure and sentinel pile on physical examination were defined as chronic anal fissure. The resting anal pressures of both groups were measured by rectal manometer prior to operation and 6 months after surgery.

2.1. Lateral internal sphincterotomy

All of the patients were operated on by the same surgeon in a standardized technique. Patients were operated under spinal anesthesia and sedation in the lithotomy position. Intersphincteric space was dissected through a transverse incision of 1–2 cm long in the 3 o'clock position. The internal anal sphincter was defined with a dissector when the left index finger was placed in the anal canal. The full thickness of the internal sphincter was transected in a lateral position. Hemostasis was achieved with a gauze pad and the incision was laid open.

2.2. Postoperative management

All patients were given soft foods at the postoperative sixth hour. They were later discharged with recommendation for sitz baths at least 4 times a day and after defecation. The first follow-up was conducted on the postoperative

seventh day and the second was in the fourth week, and then they continued monthly. Mean follow-up period was 6 months.

2.3. Manometric evaluation

All the patients underwent anal manometry testing. Manometric tests were performed with a 9E-12-100A Menfis Biomedica 9-way catheter (Menfis bioMedica s.r.l. Bologna, Italy). The PVC catheter had an external diameter of 12 Fr (4 mm), an operative length of 100 cm, and a total length of 180 cm. It had 1 central lumen of 1.4 mm in diameter, which opened at the tip, and 4 lumina, which opened with 4 side-ports of 0.8 mm in diameter with a radial arrangement 3 cm from the tip. The remaining 4 lumina opened with 4 side-ports, 5 cm apart along the catheter in a helicoidal arrangement. Centimetric markings started from side-port no. 8. (Figure).

Before each test, the device was calibrated at the same level as the patient. The examination was performed with a rapid pull-through technique while the patient was placed in a supine right lateral position. The catheter was pulled by a mechanical device with a speed of 1 mm/s under resting conditions.

2.4. Statistical analysis

Data were analyzed using SPSS 17.0 (SPSS Inc., Chicago, IL, USA). Variables were not distributed normally according to normality tests. Mann–Whitney *U*, Wilcoxon signed-ranks, and chi-square nonparametric tests were used. $P < 0.05$ was accepted as significant.

3. Results

Fifty-six (68.3%) male and 26 (31.7%) female patients were included in the study. The ages of the patients varied between 21 and 64, and the mean age was 34.9 ± 9.9 years. There were no significant differences between the control and study groups in terms of sex (chi-square = 3.604, $P = 0.097$). None of the patients described fecal or gas incontinence in the preoperative period. However, in the postoperative period 3 patients (7.31%) complained of gas incontinence and 1 patient (2.4%) had a recurrent anal fissure.

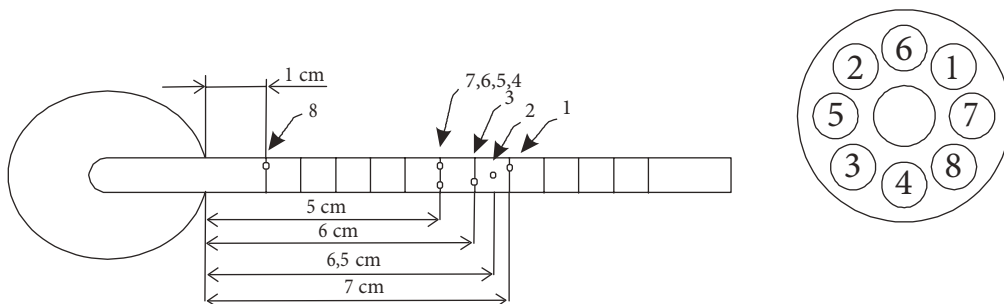


Figure. Diagram of the anorectal manometry catheter used in the study.

Preoperative mean resting anal sphincter pressure was 51.29 mmHg for the control group and was 59.99 mmHg for the patient group. Although resting anal sphincteric pressures of the patient group remained within the physiological range, when compared with the control group there was a statistically significant difference (Table 1). Postoperative mean resting anal sphincteric pressure of the patient group was 32.43 mmHg. There was a statistically significant difference between the postoperative study group and the control group (Table 2). There was also a statistically significant difference between the preoperative study group and the postoperative study group (Table 3).

4. Discussion

As was mentioned above, an anal fissure is defined as a painful ulceration of the anal canal that extends from the anal verge to the dentate line. Acute or chronic, almost all anal fissures appear on posterior midline (8). The vulnerability of the mucosa in the posterior midline to direct traumas, due to its relative inflexibility and lack of connective tissue support (9), and poor blood flow in the posterior anal wall, which has been demonstrated with Doppler and flowmetry (10–12), have been suggested for pathogenesis. Crohn's disease, AIDS, lymphoma,

leukemic ulceration, epithelial tumors of the anal canal, syphilis, herpes simplex infection, tuberculosis, and cytomegalovirus infection should all be considered in atypical anal canal ulcerations (13). A chronic anal fissure lesion is composed of a mucosal fissure, with sentinel pile on the lower edge and hypertrophied papillae on the upper edge (14). Diagnosis can be established by complaints in the patient's history in most cases. Sitz baths and stool softeners may be useful for medical treatment (8). According to the research (14), 80%–90% of incipient anal fissures heal spontaneously with conservative treatments. Conservative treatments aim to break the vicious circle of spasm and pain in this disorder. Nitroglycerin ointments have been reported to be effective in treatment by providing a significant increase in blood flow and decreasing anal pressure (15). A calcium channel blocker, diltiazem, has been suggested for patients who are refractory to glyceryl trinitrate (16). Balloon dilatation may be an option for surgically high-risk patients (17). A botulinum toxin injection to the internal sphincter causes paralysis for 4–8 weeks and healing is obtained in 40%–70% of patients in this period (18). LIS, which is the gold standard for chronic anal fissure treatment, aims to reduce anal canal pressure. A decrease in anal canal pressure and consequent healing

Table 1. Comparison of control group and preoperative study group.

Group	n	Mean ± std. dev.	Median	P
G1	41	51.294 ± 16.761	47.390	0.004**
G2 (Preoperative)	41	59.993 ± 13.136	59.890	

Monte Carlo; **: P < 0.01.

Table 2. Comparison of control group and postoperative study group.

Group	n	Mean ± std. dev.	Median	P
G1	41	51.294 ± 16.761	47.39	0.000***
G2 (Postoperative)	41	32.660 ± 11.306	30.380	

Monte Carlo; ***: P < 0.001.

Table 3. Comparison of preoperative study group and postoperative study group.

Preoperative/postoperative study group	n	Mean ± std. dev.	Z	P
Preoperative	41	59.993 ± 13.136	-5.475	0.000***
Postoperative	41	32.660 ± 11.306		

Monte Carlo; ***: P < 0.001.

has been shown in 40%–50% of anal fissure patients with high anal canal pressure (19).

Anal canal resting pressures vary between 40–70 mmHg in healthy adults and this value is found to be lower in women and older people (20). Resting anal sphincter pressure is constituted of 50%–85% internal anal sphincter, 25–30% external anal sphincter, and 15% anal pads (21). Although a decrease in resting anal pressure after LIS has been documented, there is as of yet insufficient data to show the extent of this decrease. In our study group, we showed that resting anal pressures were significantly lowered after LIS procedure. While preoperative mean resting anal pressure was 59.99 mmHg in anal fissure patients, this value dropped to 32.43 mmHg after the LIS operation. Decreases in anal pressures were

statistically significant. Despite the limited data in the literature, surgical sphincterotomy is shown to reduce the anal sphincter tone effectively (22,23). Decreased anal sphincter tone results in the healing of anal fissures and low recurrence rates (24). Incontinence remains the main distressing complication after the operation. Flatus incontinence occurred in 3 (7.31%) patients after the operation, similar to previous studies (6,25).

Consequently, the LIS procedure decreases resting anal sphincter pressures effectively in chronic anal fissure patients. To conclude, low recurrence rates after the operation, relatively low complication rates, and the cost-effectiveness of the operation render this procedure an optimal treatment option for chronic anal fissures that are refractory to conservative treatments.

References

1. Utzig MJ, Kroesen AJ, Buhr HJ. Concepts in pathogenesis and treatment of chronic anal fissure-a review of the literature. *Am J Gastroenterol* 2003; 98: 968–974.
2. Tsunoda A, Kashiwagura Y, Hirose K, Sasaki T, Kano N. Quality of life in patients with chronic anal fissure after topical treatment with diltiazem. *World J Gastrointest Surg* 2012; 27: 251–255.
3. Kaya B, Eriş Ç, Şimşek A. The development of anal incontinence after lateral internal sphincterotomy and risk factors. *Kolon Rektum Hast Derg* 2011; 21: 1–7.
4. Fruehauf H, Fried M, Wegmueller B, Bauerfeind P, Thumshirn M. Efficacy and safety of botulinum toxin A injection compared with topical nitroglycerin ointment for the treatment of chronic anal fissure: a prospective randomized study. *Am J Gastroenterol* 2006; 101: 2107–2112.
5. Arslan K, Erenoğlu B, Doğru O, Turan E, Eryilmaz MA, Atay A, Kökçam S. Lateral internal sphincterotomy versus 0.25% isosorbide dinitrate ointment for chronic anal fissures: a prospective randomized controlled trial. *Surg Today* 2013; 43: 500–505.
6. Kement M, Karabulut M, Gezen FC, Demirbas S, Vural S, Oncel M. Mild and severe anal incontinence after lateral internal sphincterotomy: risk factors, postoperative anatomical findings and quality of life. *Eur Surg Res* 2011; 47: 26–31.
7. Bannister JJ, Abouzekry L, Read NW. Effect of aging on anorectal function. *Gut* 1987; 28: 353–357.
8. Bouguen G, Eléouet M, Favreau C, Siproudhis L. Anal fissure. *Rev Prat* 2008 31; 58: 1769–1773.
9. Lund JN, Scholefield JH. Aetiology and treatment of anal fissure. *Br J Surg* 1996; 83: 1335–1344.
10. Lund JN, Binch C, McGrath J, Sparrow RA, Scholefield JH. Topographical distribution of blood supply to the anal canal. *Br J Surg* 1999; 110: 711–714.
11. Schouten WR, Briel JW, Auwerda JJ. Relationship between anal pressure and anodermal blood flow - the vascular pathogenesis of anal fissure. *Dis Colon Rectum* 1994; 37: 664–669.
12. Schouten WR, Briel JW, Auwerda JJ, De Graaf EJ. Ischaemic nature of anal fissure. *Br J Surg* 1996; 83: 63–65.
13. Dinotta F, De Pasquale R, Nasca MR, Tedeschi A, Micali G. Disseminated herpes simplex infection in a HIV+ patient. *G Ital Dermatol Venereol* 2009; 144: 205–209.
14. Evans J, Luck A, Hewett P. Glyceryl trinitrate vs. lateral sphincterotomy for chronic anal fissure. *Dis Colon Rectum* 2001; 44: 93–97.
15. Puçe JJ, García-Coret MJ, Villalba FL, Ali-Mahmoud I, Roig JV. Local treatment of a chronic anal fissure with diltiazem vs. nitroglycerin. A comparative study. *Cir Esp* 2010; 87: 224–230.
16. Medhi B, Prakash A, Upadhyay S, Xess D, Yadav TD, Kaman L. Comparison of observational and controlled clinical trials of diltiazem in the treatment of chronic anal fissure. *Indian J Surg* 2011; 73: 427–431.
17. Renzi A, Bruscianno L, Pescatori M, Izzo D, Napolitano V, Rossetti G, del Genio G, del Genio A. Pneumatic balloon dilatation for chronic anal fissure: a prospective, clinical, endosonographic, and manometric study. *Dis Colon Rectum* 2005; 48: 121–126.
18. Nasr M, Ezzat H, Elsebae M. Botulinum toxin injection versus lateral internal sphincterotomy in the treatment of chronic anal fissure: a randomized controlled trial. *World J Surg* 2010; 34: 2730–2734.
19. Ezri T, Susmallion S. Topical nifedipine vs. topical glyceryl trinitrate for treatment of chronic anal fissure. *Dis Colon Rectum* 2003; 46: 805–808.
20. Loening-Baucke V, Anuras S. Effects of age and sex on anorectal manometry. *Am J Gastroenterol* 1985; 80: 50–53.
21. Lestar B, Penninckx F, Kerremans R. The composition of anal basal pressure. An in vivo and in vitro study in man. *Int J Colorectal Dis* 1989; 4: 118–122.

22. Prohm P, Bönner C. Is manometry essential for surgery of chronic fissure-in-ano? *Dis Colon Rectum* 1995; 38: 735–738.
23. Chowcat NL, Araujo JG, Boulos PB. Internal sphincterotomy for chronic anal fissure: long term effects on anal pressure. *Br J Surg* 1986; 73: 915–916.
24. Sileri P, Stolfi VM, Franceschilli L, Grande M, Di Giorgio A, D'Ugo S, Attina G, D'Eletto M, Gaspari AL. Conservative and surgical treatment of chronic anal fissure: prospective longer term results. *J Gastrointest Surg* 2010; 14: 773–780.
25. Garg P, Garg M, Menon GR. Long-term continence disturbance after lateral internal sphincterotomy for chronic anal fissure: a systematic review and meta-analysis. *Colorectal Dis* 2013; 15: e104–117.