

Comparison of estrogen and betamethasone in the topical treatment of labial adhesions in prepubertal girls

Nazile ERTÜRK*

Department of Pediatric Surgery, Etlik Zübeyde Hanım Women's Health Teaching and Research Hospital, Ankara, Turkey

Received: 02.12.2013 • Accepted: 13.01.2014 • Published Online: 24.10.2014 • Printed: 21.11.2014

Background/aim: To compare estrogen and betamethasone in the topical treatment of labial adhesions in prepubertal girls.

Materials and methods: In this retrospective study, we evaluated 39 girls with labial adhesions covering at least 50% of the vaginal opening. Of the total patients, 20 were treated with a topical estrogen preparation, while the remaining 19 patients were treated with a combination of betamethasone cream and petroleum ointment (Vaseline) for 3 to 9 weeks.

Results: Sixteen of 20 (80%) patients in the estrogen treatment group were treated successfully with topical estrogen cream only, and 17 of 19 (89.4%) patients in the second group were treated successfully with a combination of betamethasone cream and petroleum ointment. Two patients (2/20) in the estrogen treatment group underwent a surgical procedure for the manual separation of the labial adhesion. One patient (1/19) treated with betamethasone cream and petroleum ointment required a manual separation procedure. We observed a side effect of labial enlargement in 2 patients (10%) who were treated with estrogen only, while the only side effect of the betamethasone treatment was local irritation, which occurred in a single patient (5.2%). In addition, the success rate of the betamethasone treatment exceeded that of the topical estrogen (89.4% and 80%, respectively).

Conclusion: Betamethasone cream with petroleum ointment is a safe and effective primary therapy for prepubertal labial adhesions.

Key words: Labial adhesions, betamethasone, estrogen

1. Introduction

Labial adhesion is the partial or complete adherence of the labia minora (1) originating at the posterior fourchette and extending towards the clitoris (2). Labial adhesions occur in 1.8% of females, with a peak incidence at 13 to 23 months of age. However, the prevalence of labial adhesions may be greater due to the low rate of detection among asymptomatic children (3). Although often asymptomatic, labial adhesions may become apparent when they result in postvoid dripping (urinary incontinence), urinary tract infections, vaginitis (vaginal irritation), hematuria, and increased urinary frequency (4). Labial adhesion may occur as a result of inflammation or low prepubertal estrogen levels (4).

Therefore, topical estrogen therapy is the treatment of choice (1). Estrogen creams, however, may have unwanted side effects, such as breast budding, labial engorgement, and hyperpigmentation (5). While topical estrogen creams have potentially significant side effects, topical steroid creams, such as 0.05% betamethasone, are very well tolerated with no significant side effects for the majority of cases and only

local irritation occurring in some individuals (5). In this retrospective study, we have evaluated the effectiveness of estrogen and 0.05% betamethasone cream, applied twice daily, in the treatment of prepubertal labial adhesions.

2. Materials and methods

Children of all ages are referred to our gynecology training and research hospital with gynecological problems. Thus, a wide age range of children (2 months to 9 years) were included in this study. Study inclusion criteria were fusion of at least 50% of the vaginal opening, absence of significant clinical symptoms (urinary infection, painful or altered urinary stream, recurrent vulvar or vaginal infections, postvoid dripping, etc.), and prior medical history of labial fusion treatment of any kind. The study group included 39 girls diagnosed with labial adhesion in our ambulatory care clinic who underwent topical treatment between February 2010 and July 2012.

The patients were divided into 2 groups according to the method of treatment without any randomization. Patients attending the clinic during the first 1.5 years of

* Correspondence: erturknazile@gmail.com

the study period ($n = 20$) constituted the first group (G1), while patients diagnosed during the last year ($n = 19$) composed the second group (G2). We prescribed 3 weeks of topical estrogen cream to G1 patients and a combination of topical corticosteroids (0.05% betamethasone cream) and petroleum ointment (Vaseline) to G2 patients. Several recent publications have suggested that corticosteroids are effective in the treatment of labial adhesion (4,5). Subsequently, our treatment protocol was revised to include betamethasone treatment in the last year.

The parents of the children were instructed to apply a thin layer of estrogen or betamethasone cream to the raphe along the adhesion line twice daily. A single course of treatment was defined as a 3-week course. All children were treated with 1 to 3 courses. Outcomes were stratified into several categories: successful, partially successful, and requiring surgical therapy. The successful category was defined as complete separation of the labia. Treatment resulting in greater than 75% separation of labia was considered a partial success. Patients whose lesions did not respond to topical therapy or whose parents chose surgical therapy after first undergoing topical therapy were placed into the surgical category.

A review of patient medical history, current medical charts, parent interviews, and office examinations were all included in the analysis of clinical characteristics. The data collected included the duration of the topical estrogen treatment or of the topical betamethasone treatment, side effects of medical therapy, incidence of successful separation, incidence of recurrence, percentage requiring surgery, and any perceived advantages of the 2 treatments.

Due to the small sample size, the Fisher exact test was used to determine the statistical significance of any differences between the treatment groups. $P = 0.05$ was established as the threshold of statistical significance.

3. Results

The 39 patients included in the study ranged in age from 2 months to 9 years old. The first group included 20 patients and had a mean age of 2.8 years (ranging from 3 months to 9 years); the second group included 19 patients and had a mean age of 2.4 years (ranging from 2 months to 8 years). When the groups were compared for age, there was no difference between them ($P = 0.508$). The treatment and outcome of the study groups are depicted in Figure 1.

The 20 patients of the G1 group were prescribed 3 weeks of topical estrogen treatment; of those in G1, 13(65%) experienced complete resolution of labial fusion within 3 weeks. Following the first treatment course, continued treatment was recommended to 7 (35%) patients for whom the initial treatment had failed. Despite continued treatment efforts, the parents of 2 patients (2/7) indicated that the topical treatment had not resolved their concerns and expressed a desire to further correct the condition. The parents of these patients consented to surgical resolution of labial adhesion. Fused labia were opened surgically under local anesthetic (lidocaine gel). A total of 3 patients out of the original 7 undergoing extended treatment used topical estrogen for a total of 6 weeks. Labial adhesion was completely resolved in these children and did not reoccur during follow-up. Two children in the same group (2/7) showed no improvement in symptoms, with 1 experiencing a partial opening of the labial adhesion and 1 being completely unaffected by the treatment. A third course of treatment was initiated in these patients; however, no separation occurred. Surgical treatment of labial adhesion was conducted in these patients under local anesthesia.

The 19 children included in G2 were treated with betamethasone cream and petroleum ointment (Vaseline, Unilever) in succession, twice daily over a period of 3 weeks. These patients were advised to continue the use of

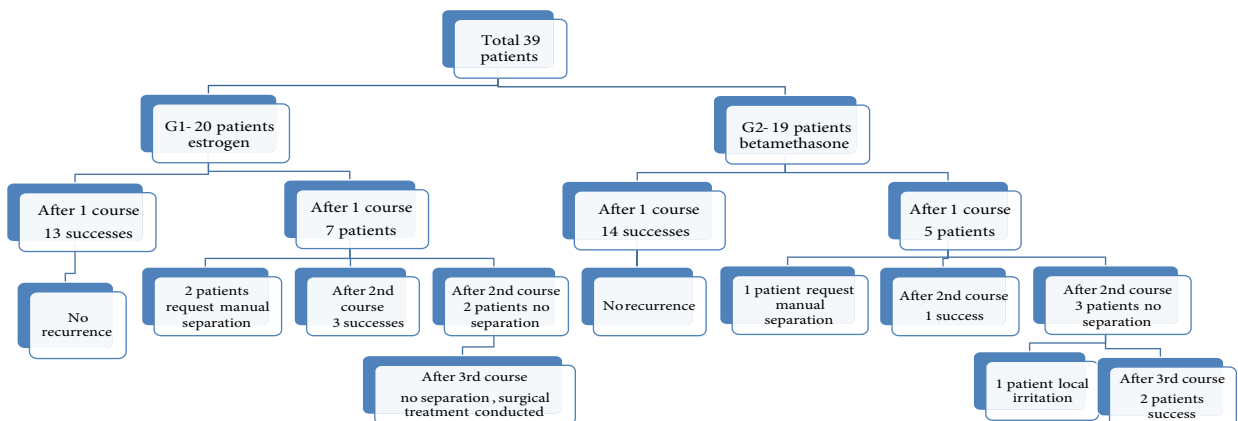


Figure 1. A schematic description of the study groups.

petroleum ointment for 1 month after labial separation. The protocol was applied to 19 children (G2), of whom 14 (73.6%) experienced complete resolution of labial adhesion within 3 weeks. However, symptoms did not completely resolve in 5 patients. One of these patients opted for surgical treatment prior to completion of the betamethasone course due to difficulties with treatment compliance. Surgical opening of the labial adhesion was performed under local anesthesia. The remaining 4 children (4/5) did not express excessive discomfort with the treatment, which was subsequently continued for 3 weeks. During the second course of treatment, labial adhesion resolved completely in 1 of the children but continued in the remaining patients. A third course of treatment was initiated. During this period (9 weeks) labial adhesion resolved completely in 2 patients, and, in 1 patient, symptoms continued and local irritation developed. Betamethasone treatment was then terminated and manual separation of labial adhesion was conducted.

There was no recurrence during the follow-up period in these patients.

4. Discussion

Labial adhesion, also known as labial agglutination, is a thin membranous adhesion of varying length of the labia minora (2). The adhesion originates at the posterior fourchette and extends towards the clitoris (2). The etiology of labial adhesion is unknown but is presumed to be related to hypoestrogenism and vulvar irritation in prepubertal girls (6). The majority of cases of labial adhesion are asymptomatic and resolve spontaneously once endogenous and exogenous estrogen increase at puberty (5). Prepubertal labial adhesions occur in 0.6%–3.0% of girls (5). Although most patients are asymptomatic, labial adhesion is often diagnosed when adhesions become inflamed or begin to interfere with voiding. Dysuria and recurrent vulvar or vaginal infections are typical symptoms at initial presentation. On rare occasions, urinary retention may occur when complete adhesion is present (3). Low estrogen expression is the most widely accepted cause of labial adhesion, and supplementation with topical estrogen treatment is the mainstay of therapy (6). Historically, medical treatment of labial adhesion involved a regimen of topical estrogen applied for an unspecified period of time, with the physician monitoring the response to treatment and the continued presence of adhesion (4). This method of treatment is successful in approximately 50%–88% of patients, and it typically results in separation of the adhesion within 2–8 weeks (3,4). Topical estrogen creams are often well tolerated; however, side effects such as hyperpigmentation of the labia and premature breast development have been reported. Serious side effects such as vaginal bleeding and precocious puberty are

possible (5,6). Two (10%) of our 20 patients who had been previously treated with estrogen cream (G1) experienced labial engorgement during the treatment that resolved once the treatment was terminated.

Topical estrogen has known side effects, while topical steroids are well tolerated. Elmore et al. (7) and Chu et al. (8) used betamethasone cream successfully in the treatment of phimosis in children, reporting no significant side effects.

In accordance with recent studies, betamethasone cream in conjunction with topical estrogen therapy has been promoted as a novel treatment modality (4,5,9). The reported success rate of topical estrogen cream varies between 47% and 100%, depending on treatment frequency and length (1,3,10). Myers et al. (5) reported a success rate of 81% following treatment with betamethasone cream. Mayoglou et al. (4) reported treatment durations of 2.2 months and 1.25 months, respectively. In our study, the duration of the betamethasone treatment was shorter, approximately half the treatment duration of that reported by Leung et al. (1) (2.4 months). The success rates for topical estrogen and betamethasone in the present study were 80% and 89.4%, respectively (Figure 2), with treatment durations of 4 weeks and 3.1 weeks, respectively. This is in agreement with some published reports. Sanfilippo (11) reported that 1 week of treatment was effective in more than 90% of cases. Opipari (12) recommended treatment with topical estrogen for 4 to 12 weeks. Aribarg (13) reported that, out of 25 girls with severe adhesion of the labia minora, 22 (88%) of the patients were treated successfully by topical estrogen within 1 month.

Some physicians recommend surgical separation if the labia remain fused following 2 weeks of topical therapy (3,14). Muram (3) performed a retrospective chart review of 259 girls with symptomatic labial adhesion. These patients were treated with topical estrogen for 10 to 14 days, with labial adhesion resolving in 121 (47%) patients. Surgical separation of labial adhesion was conducted under local anesthesia in 138 girls who did not respond to topical therapy. In our study, 2 patients from the first

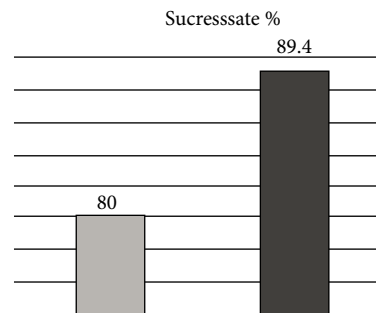


Figure 2. Success rates of estrogen (blue bar) and betamethasone (red bar) treatment in patients with labial adhesions.

group and 1 patient from the second group underwent surgical treatment due to parental concerns after the first course of topical therapy proved unsuccessful.

No clinical guidelines regarding the duration of topical therapy have been determined (4). The potential risks of long-term topical estrogen or betamethasone treatment, including adrenal suppression and cancer, remain unknown (4). In the current study, 2 patients from G1 and 1 patient from G2 did not respond to treatment after 3 courses of topical therapy and, therefore, underwent surgical separation. For unresponsive or refractory cases, manual separation with local anesthetic gel is the treatment of choice. While topical estrogen creams have potentially significant side effects, topical steroid creams such as 0.05% betamethasone are well tolerated with no significant side effects other than local irritation. In our study, labial swelling was observed in 2 (10%) patients during the use of topical estrogen. In the topical betamethasone treatment group, 1 (5.2%) patient developed local irritation. It can thus be concluded that betamethasone has fewer side effects relative to topical estrogen.

Although the difference was not statistically significant ($P = 0.356$), we observed a trend indicating that betamethasone may be more effective than estrogen due to reduced treatment time, a higher rate of treatment success, and fewer side effects. While our study was retrospective and included a limited number of participants, our experience suggests that treatment with 0.05% betamethasone cream applied twice daily is safe and has an effectiveness that is comparable to estrogen cream therapy in the treatment of prepubertal labial adhesions.

Follow-up examinations at 3 and 9 months revealed no recurrence of adhesions in the first treatment group. None of the patients needed another treatment course in the second treatment group over a mean follow-up period of 1.5 years. Other studies have reported no recurrence following successful treatment of labial adhesion (1). The absence of recurrence may be related to our emphasis on the importance of meticulous introital hygiene to minimize inflammation and to the application of a petroleum ointment (Vaseline) for 1 month following the treatment course in order to minimize readhesion. In this study we used betamethasone cream with petroleum

ointment to reduce the incidence of local irritation caused by betamethasone cream. We recommend the use of betamethasone cream with petroleum ointment.

We advise the parents of children treated for labial adhesion to follow up in the event of any recurrence and to continue the use of petroleum ointment to prevent adhesions. In the case of continued adhesions or severe cases, we advise the patients and their families to report to the hospital. This approach promotes careful treatment and follow up in the home environment. Treatment decisions concern both parents and children, and physicians should provide accurate information and support to all involved.

In our study, there were children or families in both treatment groups who refused topical treatment. Many girls with labial adhesion were admitted with a presumptive diagnosis of absent vagina, commonly a result of parental anxiety. When parental anxiety is extreme, we suggest manual separation instead of topical treatment. In such cases, parental attitudes complicate long-term treatment with topical medications.

In conclusion, both topical estrogen and betamethasone are effective treatments for labial adhesion in the majority of patients. Our findings support previously published data indicating that labial adhesions respond well to topical betamethasone therapy. Betamethasone cream (0.05%) is a safe and effective treatment for prepubertal labial adhesions with a favorable side effect profile relative to topical estrogen. Further interventions may be required in patients with labial adhesions that do not respond to topical therapy.

Clinical summary:

- Topical treatment with betamethasone cream is effective in the majority of patients and can be used safely to treat symptomatic prepubertal girls with labial adhesions.
- Successful and complete treatment of labial adhesion with topical preparations may take several weeks.
- The use of petroleum ointment with betamethasone reduces the potential side effects of betamethasone
- We advise the parents to continue to use petroleum ointment for 1 month after the resolution of labial adhesion.

References

1. Leung AKC, Robson WLM, Kao CP, Liu EKH, Fong JHS. Treatment of labial adhesion with topical estrogen therapy. *Clin Pediatr* 2005; 44: 245–247.
2. Valender MH, Mikkelsen DB, Bygum A. Labial agglutination in a prepubertal girl: effect of topical oestrogen. *Acta Derm Venereol* 2009; 89: 198–199.
3. Muram D. Treatment of prepubertal girls with labial adhesions. *J Pediatr Adolesc Gynecol* 1999; 12: 67–70.
4. Mayoglou L, Dulabon L, Martin-Alguacil N, Pfaff D, Schober J. Success of treatment modalities for labial fusion: a retrospective evaluation of topical and surgical treatments. *J Pediatr Adolesc Gynecol* 2009; 22: 247–250.

5. Myers JB, Sorensen CM, Wisner BP, Furness PD 3rd, Passamanek M, Koyle MA. Betamethasone cream for the treatment of pre-pubertal labial adhesions. *J Pediatr Adolesc Gynecol* 2006; 19: 407–411.
6. Soyer T. Topical estrogen therapy in labial adhesions in children: therapeutic or prophylactic? *J Pediatr Adolesc Gynecol* 2007; 20: 241–244.
7. Elmore JM, Baker La, Snodgrass WT. Topical steroid therapy as an alternative to circumcision for phimosis in boys younger than 3 years. *J Urol* 2002; 168: 1746–1747.
8. Chu CC, Chen KC, Diau GY. Topical steroid treatment of phimosis in boys. *J Urol* 1999; 162: 861–863.
9. Tebruegge M, Misra I, Nerminathan V. Is the topical application of oestrogen cream an effective intervention in girls suffering from labial adhesions? *Arch Dis Child* 2007; 92: 268–271.
10. Schober J, Dulabon L, Martin-Alguacil N, Kow LM, Pfaff D. Significance of topical estrogens to labial fusion and vaginal introital integrity. *J Pediatr Adolesc Gynecol* 2006; 19: 337–339.
11. Sanfilippo JS. Labial adhesions. In: Behrman RE, Kliegman RM, Jenson HB, editors. *Nelson Textbook of Pediatrics*. 16th ed. Philadelphia, PA, USA: Saunders; 2004. pp. 1829–1830.
12. Pipari AW Jr. Management quandary. Labial agglutination in a teenager. *J Pediatr Adolesc Gynecol* 2003; 16: 61–62.
13. Aribarg A. Topical oestrogen therapy for labial adhesions in children. *Br J Obstet Gynaecol* 1975; 82: 424–425.
14. Arkin AE, Chern-Hughes B. Case report: labial fusion postpartum and clinical management of labial lacerations. *J Midwifery Womens Health* 2002; 47: 290–292.