

Efficacy of wound infiltration with lornoxicam for postoperative analgesia following thyroidectomy: a prospective, randomized, double-blind study

Zafer KILBAŞ^{1*}, Mustafa Öner MENTEŞ¹, Ali HARLAK¹, Taner YİĞİT¹, Salih Müjdat BALKAN¹, Ahmet COŞAR², Erkan ÖZTÜRK¹, Orhan KOZAK¹, Cemil Turgut TUFAN¹

¹Department of General Surgery, Gülhane School of Medicine, Ankara, Turkey

²Department of Anesthesiology, Gülhane School of Medicine, Ankara, Turkey

Received: 21.02.2014 • Accepted/Published Online: 18.06.2014 • Printed: 30.06.2015

Background/aim: Postoperative pain control constitutes a major problem and studies have focused on reducing opioid requirements using regional techniques. We aimed to investigate the efficacy of wound infiltration with lornoxicam on postoperative pain control following thyroidectomy.

Materials and methods: In this prospective, randomized-controlled study, 80 patients scheduled for thyroidectomy were randomly assigned to 2 groups. After the thyroidectomy was performed, patients in group I underwent wound infiltration with 4 mg of lornoxicam and patients in group II received the same amount of saline. Rescue analgesia was provided with additional doses of lornoxicam delivered by an on-demand patient-controlled analgesia device. Total analgesic consumption during the postoperative 24 h, and pain intensities assessed using a visual analog scale score at 0, 2, 4, 8, 12 and 24 h postoperatively were recorded.

Results: Pain scores during the postoperative 24 h were slightly lower in group I than in group II, but the difference was not significant ($P > 0.05$). The mean analgesic consumption was 8.87 ± 1.87 mg and 10.33 ± 1.25 mg in groups I and II, respectively ($P > 0.05$).

Conclusion: Wound infiltration with lornoxicam neither improved postoperative pain control nor decreased total analgesic consumption.

Key words: Wound infiltration, lornoxicam, postoperative pain, thyroidectomy

1. Introduction

Thyroidectomy is the most frequently performed procedure in endocrine surgery all around the world. With the introduction of new energy devices and the development of minimally invasive techniques in the era of thyroid surgery, postoperative hemorrhage and hypocalcemia have been minimized and the surgical procedure has been performed increasingly as an ambulatory surgery during the last decade (1,2). Today, postoperative pain constitutes one of the major obstacles to day care surgery.

Postoperative pain related to thyroid surgery is estimated to be of moderate to severe intensity, and most patients require narcotic analgesics for pain control (3). Effective postoperative pain management can provide patients comfort; moreover, it can shorten functional recovery time and enable patients to return to daily activities and work sooner (4). Traditional pain management achieved this objective by using large amounts of opioid analgesics with many undesired side effects. The role of connective tissue trauma and inflammation as potent factors for the development of postoperative pain are well understood. In addition, nonsteroidal anti-

inflammatory drugs (NSAIDs) are known to act by inhibiting prostaglandin synthesis, both in the central nervous system and in the damaged soft tissue region. Thus, systemic or local administration of NSAIDs may help to decrease the intensity of postoperative pain and the level of analgesic consumption by attenuating the inflammation and edema. As it is understood that combination therapies targeting different sites of the pain pathway have better results, recent studies have focused on wound infiltration analgesia by using new agents to reduce opioid use and its side effects.

Lornoxicam, one of the oxycam class of NSAIDs, is a potent analgesic with anti-inflammatory properties in a range of painful conditions, including postoperative pain (5,6). The peroral and parenteral forms of lornoxicam have been used to treat moderately acute postoperative pain (5,7). In addition, local administration of lornoxicam combined with a local anesthetic has been found safe and effective in clinical trials (8,9). However, the efficacy of wound infiltration analgesia with lornoxicam alone for postoperative pain management after thyroid surgery has not been studied yet.

* Correspondence: zkilbas@yahoo.com

The aim of this double-blind, prospective randomized and placebo-controlled study was to investigate the analgesic efficacy of wound infiltration with lornoxicam in patients undergoing thyroidectomy based on their pain intensity scores and 24 h of postoperative analgesic consumption.

2. Material and methods

After institutional approval was obtained from the Ethics Committee of the Gülhane School of Medicine, Ankara, Turkey, and written informed consent, 80 adult patients aged 20–65, scheduled for partial or total thyroidectomy, and with American Society of Anesthesiologists (ASA) classification I or II were enrolled in the study. The study was carried out between 2007 and 2009, in the Gülhane School of Medicine, Department of General Surgery, Ankara, Turkey.

Exclusion criteria included a known intolerance or allergy to any drugs used in the study, cardiovascular or respiratory disease, renal or liver failure, coagulopathy, alcohol addiction, and opioid addiction. In addition, patients who did not want to participate in the study, had undergone previous thyroid surgery, or had undergone thyroid resection in combination with neck dissection were excluded.

In this prospective randomized, placebo-controlled study, the 80 patients were randomly divided into 2 groups of 40 patients in each: group I, in which wound infiltration with 4 mg lornoxicam was done, and group II, a control group in which wound infiltration was done with the same amount of physiological saline.

The severity of pain was assessed using a visual analog scale (VAS) and patients were informed about the VAS ratings (0 = no pain, 100 = the worst possible pain) and about the use of the patient-controlled analgesia (PCA) pump. Patients were asked to evaluate their postoperative pain using the VAS at 0, 2, 4, 8, 12, and 24 h, both at rest and at movement of the neck in two directions (up–down and left–right). Systolic blood pressure (SBP), diastolic blood pressure (DBP), peripheral oxygen saturation (SpO₂), heart rate (HR), and respiratory rate (RR) of patients were recorded before and 0, 2, 4, 8, 12, and 24 h after the operation by nurses who were blinded to the study group. Sedation was evaluated using a five-point numerical scale, with 0 = alert and 4 = deep sleep.

2.1. Anesthesia and surgical procedure

A standardized anesthesia protocol was used for all our patients. Preinduction was carried out with intravenous midazolam (1–1.5 mg) and fentanyl (2 µg/kg), and then induction was performed with intravenous propofol (1.5–2 mg/kg). Tracheal intubation was facilitated with atracurium (0.5 mg/kg) and patients were maintained with 1.5%–2% sevoflurane in a mixture of 66% nitrous

oxide and 34% oxygen. No opioids were administered intraoperatively. The thyroidectomies were performed by three different surgical teams using a standardized technique with elevation of the subplatysmal flaps, retraction of the strap muscles, and the routine use of suction drains in all patients. Suction drains were taken off at the first postoperative day and no hematomas or seromas were observed in any patients.

2.2. Infiltration analgesia

At the completion of each thyroidectomy and before skin closure, wound infiltration was performed by the surgeons, who were blinded to the applied medications. An anesthetist prepared and labeled the study drugs. The patients in group I (lornoxicam group) underwent wound infiltration with 4 mg of lornoxicam (Xefo; Nycomed Pharma AS, Roskilde, Denmark) diluted with 10 cc of saline and the infiltration was applied into the front group cervical muscles and subcutaneous tissue in both flaps (top and bottom) so as to be 2.5 cc for each side. The patients in group II (saline group) were administered the same amount (10 mL) of saline in the same manner.

After tracheal extubation, patients in both groups were transferred to the postanesthesia recovery unit and postoperative analgesia was maintained by intravenous infusion of lornoxicam (prepared to 12 mg/100 mL) via a PCA pump. The PCA pump was programmed as follows: bolus dose of 4 mg, continuous infusion of 0.12 mg/h, demand dose of 0.2 mg, and lock-out interval of 30 min. Further PCA doses of lornoxicam were delivered as 0.2 mg doses on patient demand.

Total lornoxicam consumption during the postoperative 24 h, VAS scores, and hemodynamic parameters were recorded at specific time intervals. Any side effects related to the agents used in the study and postoperative nausea and vomiting were recorded and treated as necessary.

2.3. Outcomes

The primary outcome variable of our study was total analgesic consumption (lornoxicam mg/kg) for the 24-h-long postoperative period. The secondary outcome variables were the VAS scores at specific time intervals.

2.4. Statistical analysis

Calculation of sample size was performed using power analysis and sample size calculation software. A sample size of 40 patients per group was needed to demonstrate a significant difference with a power of 80% and an α -coefficient of 0.05. The results are presented as count, percent (%), and mean values with their standard deviations (SD). The Mann–Whitney U test was used to assess VAS scores, consumed dose of lornoxicam, and hemodynamic parameters. Fisher's exact test was used for the evaluation of sex and ASA scores. A P value < 0.05 was considered statistically significant.

3. Results

All 80 patients, randomized by using sealed envelopes, completed the study (Table 1). The 2 groups did not differ in terms of distribution of age, sex, weight, ASA score, or duration of surgery (Table 2). There were no statistically significant differences in sedation or the hemodynamic parameters including SBP, DBP, RR, HR, and SpO₂ between the 2 groups during the postoperative 24 h. Postoperative nausea and vomiting was observed in 3 patients in group I and in 2 patients in group II.

3.1. Postoperative analgesic consumption

Postoperative analgesic consumption (mg) over 24 h was the total amount of lornoxicam administered with the PCA pump to attain a VAS of <30. In group I, the mean 24 h consumption of lornoxicam was 8.87 ± 1.87 mg and it was 10.33 ± 1.25 mg for group II (P = 0.416). There was no statistically significant difference in terms of postoperative analgesic consumption between the groups (Table 3).

Table 1. Flow diagram of the study.

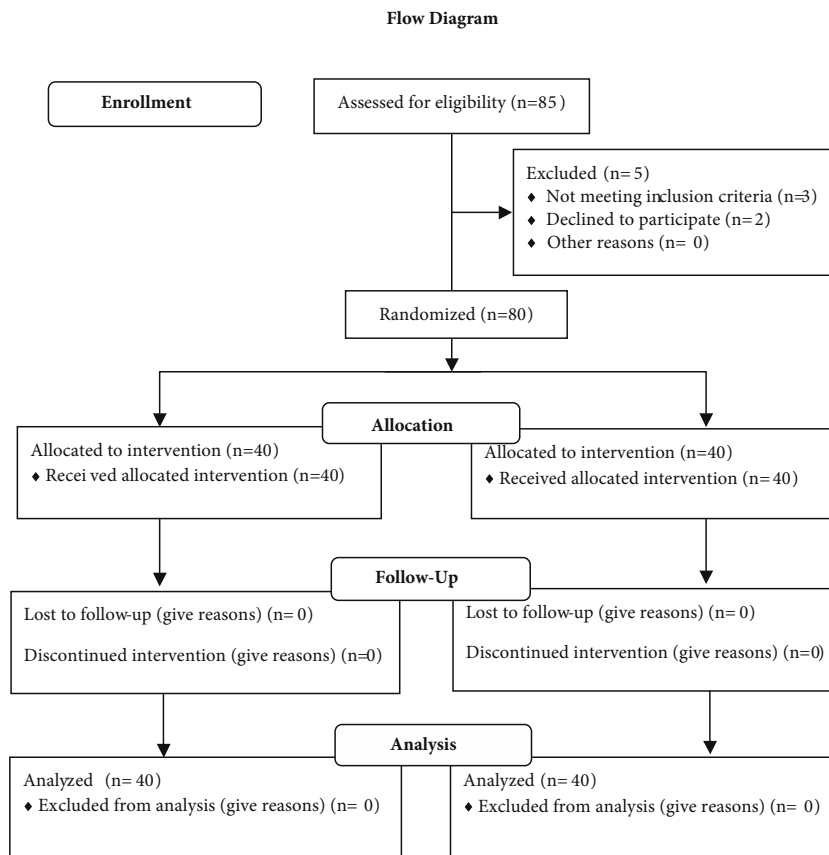


Table 2. Demographic characteristics and surgical data of patients.

	Group I (n = 40)	Group II (n = 40)	P
Age	40.35 ± 11.58	44.14 ± 12.40	0.307
Weight (kg)	68.30 ± 10.61	73.52 ± 11.0	0.92
Operation time (min)	128.04 ± 30.25	132.39 ± 23.51	0.634
Sex (M/F)	9/31	10/30	0.123
ASA (I/II)	29/11	31/9	0.346

Table 3. Comparison of analgesic requirements during postoperative 24 h.

	Group I	Group II	P
Total Lornoxicam (mg) consumption	8.87 ± 1.87	10.33 ± 1.25	0.416

3.2. Postoperative visual analog scores

Although postoperative pain scores (both at rest and at neck movement) were lower with lornoxicam compared with the placebo at the specific time intervals (Figures 1 and 2), the difference between the groups at all time intervals was not statistically significant ($P > 0.05$). In addition, the average of the VAS scores at rest and at neck movement was not statistically different between the groups (Figure 3).

4. Discussion

This prospective, randomized, placebo-controlled study demonstrated that wound infiltration with lornoxicam alone does not reduce postoperative analgesic consumption following thyroidectomy. On the other hand,

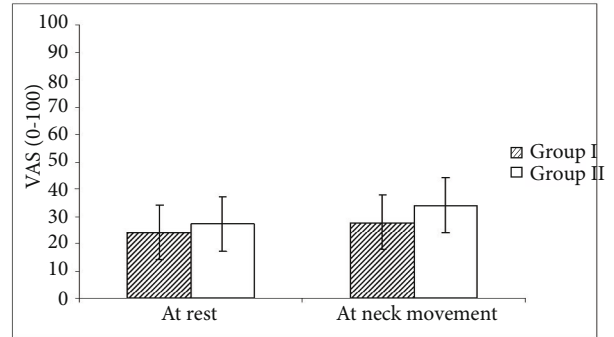


Figure 3. Average of VAS pain scores at rest and at neck movement in two directions (up-down and left-right).

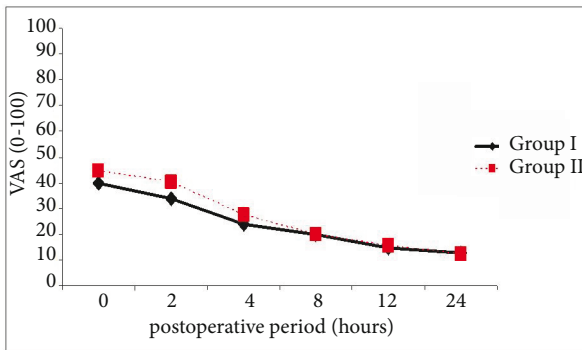


Figure 1. Comparison of the postoperative VAS pain scores at rest. Values are presented as mean ± standard deviation.

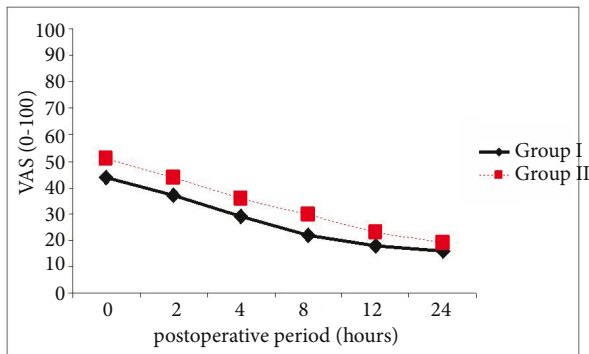


Figure 2. Comparison of the postoperative VAS pain scores at neck movement. Values are presented as mean ± standard deviation.

as a secondary outcome of the study, the results showed that postoperative pain control after thyroid surgery can be achieved with lornoxicam administered via PCA.

Postoperative pain is an undesirable condition that can delay functional recovery and cause prolongation in length of hospital stay. An effective management of postoperative pain relieves suffering and leads to earlier mobilization, reduced hospital costs, and increased patient satisfaction (10–12).

Thyroid surgery with a mean postoperative VAS score of 69 is considered to be moderately painful (13,14). Recent reports suggest that patients experience a significant amount of pain, especially in the early postoperative hours, despite modern and less invasive surgical techniques (13). In the development of the pain after thyroid surgery, inflammation from tissue trauma (due to dissection and retraction of the deep and superficial layers) and hyperextension of the neck during surgery play a major role (15).

Since day care surgery is an option for thyroid surgery and it is being increasingly performed, postoperative pain control has gained critical importance. Opioids are the traditional first-line analgesics most commonly used for postoperative pain control. However, they have a wide range of side effects including respiratory depression, sedation, nausea, vomiting, and a delay in return of gastrointestinal function (16).

The current concept in the management of postoperative pain is minimizing the dose of opioids to reduce side effects while still providing adequate analgesia. This goal may be accomplished with a multimodal approach and infiltration analgesia (17).

Local anesthetic or NSAID infiltration as a part of multimodal analgesia is performed to decrease the pain after surgery. Incision-site local anesthetic infiltration has been found to be effective for the management of postoperative pain, especially in radical prostatectomy and laparoscopic cholecystectomy (18,19). However, our literature search did not reveal any study related to the effect of wound infiltration with lornoxicam alone in thyroid surgery. There are limited trials regarding the effects of infiltration analgesia and the results are controversial.

Gozal et al. demonstrated the pain-reducing effect of local anesthetic (bupivacaine) infiltration in thyroid surgery and they found that the 24-h morphine requirement and the mean pain scores were significantly less in the treatment group (20). Similarly, wound infiltration with local anesthetics and bilateral superficial and deep cervical plexus block were reported to reduce postoperative pain and opioid requirements after thyroid surgery (15,21–23). Karamanlioglu et al. demonstrated that wound infiltration with the combination of lornoxicam and ropivacain effectively reduced postoperative pain during the first 12 h (24). Furthermore, they found that time to first analgesic was significantly longer in the treatment group than in the control group.

On the other hand, there also exist some other studies reporting opposite results regarding the effects of wound infiltration (14). A meta-analysis consisting of randomized trials reported that wound infiltration significantly decreased postoperative analgesic consumption, and in addition, it increased time to first analgesic requirement (25). However, in terms of postoperative pain scores, they found no significant differences in patients who had wound infiltration with local anesthetic. Some randomized trials have demonstrated that local anesthetic injection around incision sites can reduce postoperative somatic pain, but this is not the case for visceral pain (26,27).

Since we did not use any opioids for postoperative pain management, our study demonstrated that postoperative pain control can be accomplished with the use of NSAIDs alone, and thus the side effects of opioids or narcotics can be avoided. Secondly, lornoxicam can be safely used both as an infusional analgesic with a PCA device or as an

infiltration analgesia agent. The use of lornoxicam with a PCA can contribute to postoperative pain treatment with low dose analgesics and increase patient comfort.

In the management of mild to moderate postoperative pain, NSAIDs have been studied as a single agent and the results are satisfactory. In a randomized controlled clinical trial, single doses of lornoxicam (4 and 8 mg intravenous) were compared to those of tramadol (50 mg) in patients undergoing hysterectomy and lornoxicam was found to be more effective than tramadol in controlling postoperative pain as well as being better tolerated (28).

There have been an increasing number of studies conducted to investigate the effect of local infiltration with NSAIDs in postoperative pain. The results of these studies demonstrated that there is evidence for a clinically relevant peripheral analgesic effect of wound infiltration with NSAIDs (29,30).

Our study presents some limitations. First of all, three different surgical teams were involved in the study, but they operated with the same standardized technique and the durations of the surgical procedures were similar. In addition, we used lornoxicam both as an infiltrating analgesic and as a rescue analgesic; if we had used a different agent as the rescue analgesic, the criteria of postoperative analgesic consumption would be a more objective parameter. This decision was made because we wanted to investigate whether lornoxicam alone could be an alternative to opioids for the management of postoperative pain.

An allergic reaction to the agents used, a prolongation in wound healing, and a risk of wound infection are the most common concerns with the infiltration analgesia technique, but we did not observe any signs of wound infection or allergic reaction in any of the patients.

In conclusion, wound infiltration with lornoxicam alone did not significantly reduce postoperative pain intensities or analgesic consumption when compared with saline in patients undergoing thyroid surgery. On the other hand, our results suggest that lornoxicam can be an alternative to opioids when administered by PCA for the treatment of moderate to severe postoperative pain.

References

1. Clark N, Schneider DE, Vrabec S, Bauer PS, Chen H, Sippel RS. Increased efficiency of endocrine procedures performed in an ambulatory operating room. *J Surg Res* 2013; 184: 200–203.
2. Stack BC, Moore E, Spencer H, Medvedev S, Bodenner DL. Outpatient thyroid surgery data from the University Health System (UHC) Consortium. *Otolaryngol Head Neck Surg* 2013; 148: 740–745.
3. Andrieu G, Amrouni H, Robin E, Carnaille B, Wattier JM, Pattou F, Vallet B, Lebuffe G. Analgesic efficacy of bilateral superficial cervical plexus block administered before thyroid surgery under general anaesthesia. *Br J Anaesth* 2007; 99: 561–566.
4. Recart A, Duchene D, White PE, Thomas T, Johnson DB, Cadeddu JA. Efficacy and safety of fast-track recovery strategy for patients undergoing laparoscopic nephrectomy. *J Endourol* 2005; 19: 1165–1169.

5. Rawal N, Kroner K, Simin-Geertsen M, Hejl C, Likar R. Safety of lornoxicam in the treatment of postoperative pain: a post-marketing study of analgesic regimens containing lornoxicam compared with standard analgesic treatment in 3752 day-case surgery patients. *Clin Drug Investig* 2010; 30: 687–697.
6. Ilias W, Jansen M. Pain control after hysterectomy: an observer-blind, randomised trial of lornoxicam versus tramadol. *Br J Clin Pract* 1996; 50: 197–202.
7. Hall PE, Derry S, Moore RA, McQuay HJ. Single dose oral lornoxicam for acute postoperative pain in adults. *Cochrane Database Syst Rev* 4, 2009: CD007441.
8. Ismail SA, Mowafi HA. Preoperative peritonsillar lornoxicam infiltration is not superior to intravenous lornoxicam for pain relief following tonsillectomy in adults. *Eur J Anaesthesiol* 2010; 27: 807–811.
9. Muslu B, Usta B, Muslu S, Yeşilay A, Gözdemir M, Sert H, Demircioglu R. Effect of locally administered lornoxicam in the management of low back pain after lumbar epidural anesthesia: a double-blind, randomized, controlled study. *Minerva Anesthesiol* 2009; 75: 494–497.
10. Motamed C, Merle JC, Yakhou L, Combes X, Dumerat M, Vodinh J, Kouyoumoudjian C, Duvaldestin P. Intraoperative IV morphine reduces pain scores and length of stay in the post anaesthetic care unit after thyroidectomy. *Br J Anaesth* 2004; 93: 306–307.
11. Joshi GP. Postoperative pain management. *Int Anesthesiol Clin* 1994; 32: 113–126.
12. Gupta A, Kaur K, Sharma S, Goyal S, Arora S, Murthy RS. Clinical aspects of acute postoperative pain management & its assessment. *J Adv Pharm Technol Res* 2010; 1: 97–108.
13. Motamed C, Merle JC, Yakhou L, Combes X, Vodinh J, Kouyoumoudjian C, Duvaldestin P. Postoperative pain scores and analgesic requirements after thyroid surgery: comparison of three intraoperative opioid regimens. *Int J Med Sci* 2006; 3: 11–13.
14. Eti Z, Irmak P, Gulluoglu BM, Manukyan MN, Gogus FY. Does bilateral superficial cervical plexus block decrease analgesic requirement after thyroid surgery? *Anesth Analg* 2006; 102: 1174–1176.
15. Lacoste L, Thomas D, Kraimps JL, Chabin M, Ingrand P, Barbier J, Fusciardi J. Postthyroidectomy analgesia: morphine, buprenorphine, or bupivacaine? *J Clin Anesth* 1997; 9: 189–193.
16. Camilleri M. Opioid-induced constipation: challenges and therapeutic opportunities. *Am J Gastroenterol* 2011; 106: 835–842.
17. Kehlet H, Dahl JB. The value of “multimodal” or “balanced analgesia” in postoperative pain treatment. *Anesth Analg* 1993; 77: 1048–1056.
18. Tauzin-Fin P, Sesay M, Svartz L, Krol-Houdek MC, Maurette P. Wound infiltration with magnesium sulphate and ropivacaine mixture reduces postoperative tramadol requirements after radical prostatectomy. *Acta Anaesthesiol Scand* 2009; 53: 464–469.
19. Louizos AA, Hadzilia SJ, Leandros E, Kouroukli IK, Georgiou LG, Bramis JP. Postoperative pain relief after laparoscopic cholecystectomy: a placebo-controlled double-blind randomized trial of preincisional infiltration and intraperitoneal instillation of levobupivacaine 0.25%. *Surg Endosc* 2005; 19: 1503–1506.
20. Gozal Y, Shapira SC, Gozal D, Magora F. Bupivacaine wound infiltration in thyroid surgery reduces postoperative pain and opioid demand. *Acta Anaesthesiol Scand* 1994; 38: 813–815.
21. Steffen T, Warschkow R, Brandle M, Tarantino I, Clerici T. Randomized controlled trial of bilateral superficial cervical plexus block versus placebo in thyroid surgery. *Br J Surg* 2010; 97: 1000–1006.
22. Dieudonne N, Gomola A, Bonnichon P, Ozier YM. Prevention of postoperative pain after thyroid surgery: a double-blind randomized study of bilateral superficial cervical plexus blocks. *Anesth Analg* 2001; 92: 1538–1542.
23. Aunac S, Carlier M, Singelyn F, De Kock M. The analgesic efficacy of bilateral combined superficial and deep cervical plexus block administered before thyroid surgery under general anesthesia. *Anesth Analg* 2002; 95: 746–750.
24. Karamanlioglu B, Turan A, Memis D, Kaya G, Ozata S, Ture M. Infiltration with ropivacaine plus lornoxicam reduces postoperative pain and opioid consumption. *Can J Anaesth* 2005; 52: 1047–1053.
25. Ong CK, Lirk P, Seymour RA, Jenkins BJ. The efficacy of preemptive analgesia for acute postoperative pain management: a meta-analysis. *Anesth Analg* 2005; 100: 757–773.
26. Updike GM, Manolitsas TP, Cohn DE, Eaton LA, Fowler JM, Young DC, Copeland LJ. Pre-emptive analgesia in gynecologic surgical procedures: preoperative wound infiltration with ropivacaine in patients who undergo laparotomy through a midline vertical incision. *Am J Obstet Gynecol* 2003; 188: 901–905.
27. Leung CC, Chan YM, Ngai SW, Ng KF, Tsui SL. Effect of pre-incision skin infiltration on post-hysterectomy pain – a double-blind randomized controlled trial. *Anaesth Intensive Care* 2000; 28: 510–516.
28. Radhofer-Welte S, Rabasseda X. Lornoxicam, a new potent NSAID with an improved tolerability profile. *Drugs Today* 2000; 36: 55–76.
29. Wang YL, Hsieh JR, Chung HS, Yu CL, Ho AC, Lu PP, Tan PP. The local addition of tenoxicam reduces the incidence of low back pain after lumbar epidural anesthesia. *Anesthesiology* 1998; 89: 1414–1417.
30. Elhakim M, Fathy A, Elkott M, Said MM. Intra-articular tenoxicam relieves post-arthroscopy pain. *Acta Anaesthesiol Scand* 1996; 40: 1223–1226.