

Risk factors and maximum standardized uptake values within lymph nodes of anthracosis diagnosed by endobronchial ultrasound-guided transbronchial needle aspiration

Nilgün YILMAZ DEMİRÇİ^{1*}, İbrahim Onur ALICI², Aydın YILMAZ³,
Funda DEMİR AĞ⁴, Ebru TATCI⁵, Yurdanur ERDOĞAN³

¹Chest Diseases Clinic, Faculty of Medicine, Gazi University, Beşevler, Ankara, Turkey

²Chest Diseases Clinic, Yüksek İhtisas Hospital of Turkey, Altındağ, Ankara, Turkey

³Chest Diseases Clinic, Atatürk Chest Diseases and Chest Surgery Education and Research Hospital, Keçiören, Ankara, Turkey

⁴Department of Pathology, Atatürk Chest Diseases and Chest Surgery Education and Research Hospital, Keçiören, Ankara, Turkey

⁵Department of Nuclear Medicine, Atatürk Chest Diseases and Chest Surgery Education and Research Hospital, Keçiören, Ankara, Turkey

Received: 23.09.2014 • Accepted/Published Online: 03.01.2015 • Printed: 30.07.2015

Background/aim: Enlarged mediastinal lymph nodes can result from serious etiologies including granulomatous disease, neoplasia, etc., and a rare condition called anthracosis. The aim of this study was to determine the incidence of risk factors and the uptake values within the anthracotic lymph nodes.

Materials and methods: 106 patients who underwent endobronchial ultrasound transbronchial needle aspiration and were diagnosed as having anthracosis were analyzed retrospectively. Patients with positive confirmation by surgical biopsies or a 1-year follow-up period were enrolled.

Results: 201 lymph nodes were sampled from 106 patients. Subcarinal and interlobar lymph nodes were the most commonly affected stations (36.8% and 34.3%, respectively). The mean durations of exposure to biomass and cigarette smoke were 35.5 and 33 years, respectively. The mean maximum standardized uptake value (SUVmax) within the lymph nodes was 4.76. The SUVmax of the patients with associated malignancy was 4.19 and the SUVmax of nonmalignant patients was 5.28. This difference was statistically significant ($P = 0.009$).

Conclusion: These findings suggest that anthracosis also affects the mediastinal and hilar stations; it should be considered in differential diagnosis in patients with mediastinal and hilar lymphadenopathies with intense uptake on positron emission tomography scans, especially when there is a history of exposure to known risk factors.

Key words: Endobronchial ultrasound, pulmonary anthracosis, positron emission tomography

1. Introduction

Indoor air pollution resulting from the use of solid fuels for cooking and heating is a significant public health concern in developing countries, where a substantial proportion of the population relies exclusively on such fuels for cooking and heating (1). Like biomass smoke and air pollution, cigarette smoke also leads to a black pigmentation called anthracosis. Mediastinal lymphadenopathy is a common clinical problem and there are several causes, such as infection, neoplasia, and granulomatous disease. In developing countries, anthracosis may be another cause of mediastinal lymphadenopathy. Anthracosis is a benign condition that can also cause confusion with false-positive positron emission tomography (PET) images and mimic malignancy (2).

F-18 fluorodeoxyglucose (FDG) combined with PET/computed tomography (CT) imaging detects metabolic anomalies due to differences in tissue glucose uptake, and thus metabolic activity. FDG PET/CT is used in the diagnosis and staging of cancers, monitoring of efficacy of treatment, and restaging. FDG is not a cancer-specific agent, and false-positive findings in benign diseases have been reported (3).

We reviewed patients with mediastinal and hilar lymphadenopathies that were diagnosed as having nodal anthracosis with endobronchial ultrasound-guided transbronchial needle aspiration (EBUS-TBNA). EBUS-TBNA is a safe, minimally invasive diagnostic modality with a high yield for the diagnosis of mediastinal and/

* Correspondence: nilgundemirci@gazi.edu.tr

or hilar adenopathy, as well as for lesions adjacent to the airways. Because of its high diagnostic yields and minimally invasive nature, EBUS-TBNA is considered an alternative method to mediastinoscopy (4).

The finding of high maximum standardized uptake values (SUVmax) in PET-CT of patients with anthracotic lymph nodes has attracted attention. This condition is a common clinical problem in tuberculosis-endemic countries. We conducted this retrospective evaluation to determine the incidence of risk factors and the uptake values within the lymph nodes of anthracotic patients.

2. Materials and methods

All patients who underwent EBUS-TBNA and PET/CT for staging or diagnosis with mediastinal lymph node and were diagnosed as nodal anthracosis at the Atatürk Chest Disease and Chest Surgery Education and Research Hospital between March 2010 and January 2012 were retrospectively analyzed. Patients with positive confirmation with surgical biopsies or at least 1-year follow-up period for mediastinal lymph node were enrolled. All patients had a PET scan for cancer staging or mediastinal lymph node etiology. We retrospectively reviewed the medical records of all patients for basic demographic data, history of active/passive smoking, occupational history, drugs used, exposure to biomass fuel composed of animal dung, and detailed medical history including tuberculosis and other infections. The duration of the exposure to the biomass was defined as cumulative years. EBUS-TBNA was performed under conscious sedation with midazolam, ketamine, or propofol in an operating room. An EBUS (BF-UC180F, Olympus, Tokyo, Japan) was used to examine the lymph nodes and the ultrasound images were processed with a dedicated scanner (EU-ME1, Olympus, Tokyo, Japan). We used 22-gauge needles to sample the lymph nodes. The cytology specimens were smeared onto slides and air dried, and stained with Giemsa and other required stains. We also prepared cell blocks for every patient. For the cell blocks, the aspirated material was ejected into 10 cc of sterile saline solution and immediately transferred to the pathology department. After processing through filter paper, the tissue fragments were fixed in 10% buffered formalin. Cell blocks were embedded in paraffin, and sections of 6 μ m thickness were obtained and stained with the requisite stains (hematoxylin–eosin and further morphological, histochemical, and immunohistochemical analyses) according to the histopathologist's decision. The cell blocks with macroscopic anthracosis and aggregated anthracotic macrophages on microscopic examination were enrolled in the study. We also routinely devoted aspirated material for culture with Löwenstein–Jensen

medium. Rapid on-site evaluation (ROSE) was not available at our institution. PET/CT was carried out with an integrated PET/CT scanner (Siemens, Biograph-6-True Point). Patients were instructed to fast for at least 6 h before the examination. After confirmation of a normal peripheral blood glucose level (<180 mg/dL), the patients received an intravenous injection of 145 μ Ci/kg (maximum 200 μ Ci) of F-18 FDG and rested for 60 min before the scan. Images were obtained from the base of the skull to mid-thigh level. The SUV was calculated as the ratio of tissue radiotracer concentration (mCi/mL) and injected dose (mCi) at the time of data acquisition divided by body weight (g). The study was approved by the Ethics Committee of Atatürk Chest Diseases and Chest Surgery Education and Research Hospital.

2.1. Statistical analysis

All statistical analyses were carried out using SPSS for Windows v.17 statistical software. Descriptive statistics were expressed as mean \pm standard deviation for continuous variables and frequency (in percent) for categorical variables. Spearman correlation was used to investigate possible associations between SUVmax and other variables and between sonographic parameters and exposure duration. Student's t-test was used to evaluate the relationship between categorical variables, SUVmax, and presence or absence of malignancy within the lymph nodes. A P value <0.05 was considered statistically significant.

3. Results

Between March 2010 and January 2012 in total 1138 lymph nodes were sampled from 546 patients. A total of 201 lymph nodes, cytologically confirmed with anthracosis, were sampled from 106 patients; 25 of the patients were female and 81 were male. The mean age was 59.8 ± 11.5 years (Table 1).

There was no comorbid disease in 41 patients, while 65 patients had at least one comorbid disease (chronic obstructive pulmonary disease, diabetes mellitus, chronic heart failure, lung cancer, extrapulmonary cancer, hypertension). While 88 (83%) patients had a history of exposure to biomass smoke, 83 (78.3%) patients had a history of active/passive cigarette smoke and 68 (64.2%) patients had a history of exposure to biomass smoke and cigarette smoke together; 4 (3.8%) patients had no exposure. The mean durations of exposure to biomass smoke and cigarette smoke were 35.45 ± 24.4 and 33.06 ± 28.4 years, respectively. Eleven patients had a history of tuberculosis or contact with tuberculosis; however, none of the patients had active tuberculosis. Moreover, the cultures of aspirated material obtained with convex probe-EBUS were negative

Table 1. Study group characteristics.

Age (years)	59.8 (18–80)
Sex (female/male)	25/81
Exposure duration to biomass smoke (years)	35.45 ± 24.4
Exposure to cigarette smoke (package years)	33.06 ± 28.4
Mean SUVmax value	4.76 (1.2–16.8)

for *Mycobacterium tuberculosis*. Seven of the patients had bronchoscopic findings of anthracotic pigmentation on only the overlying mucosa, while two patients had bronchoscopic findings of anthracotic pigmentation with bronchial obliteration; other bronchoscopic findings were normal. While 42 patients had lung cancer (25 squamous, 8 adenocarcinoma, 6 not otherwise specified, 3 small cell lung cancer, 1 large cell), 5 had extrapulmonary cancer (1 testicular cancer, 2 stomach cancer, 2 non-Hodgkin lymphoma). The mean short axis length of the nodes was 11.79 ± 6.22 mm (13.6 mm in benign cases, 10.2 mm in malignant cases, $P < 0.05$). The diagnoses were confirmed surgically for staging in 35 (24.8%) cases and all of these cases represented lung cancer. The remaining patients were followed up for at least 1 year and CT scan showed completely stable appearances. None developed malignancy.

Subcarinal and interlobar lymph nodes were the most commonly affected stations (36.8% and 34.3%, respectively) (Table 2).

The sonographic features of the lymph nodes were 99% hypoechoic, 50.7% heterogeneous, 52.7% oval shaped, 73.6% distinct margin, 96% necrosis absent, and 95% calcification absent. No significant interactions were identified between these sonographic parameters, SUVmax value and exposure duration. The mean maximum uptake value within the lymph nodes was 4.76

(1.2–16.8). There was no correlation between SUVmax values and durations of exposure to biomass and cigarette smoke ($P > 0.05$) (Figures 1 and 2). Moreover, the SUVmax value within the lymph nodes of 4 patients who had no exposure was 7.18. The SUVmax value of the patients with associated malignancy was 4.19 and the SUVmax value of nonmalignant patients was 5.28. This difference was statistically significant ($P = 0.009$) (Figures 3 and 4).

4. Discussion

In this retrospective study we evaluated the cases of mediastinal lymphadenopathy in which lymph node anthracosis was identified as the final primary diagnosis using EBUS-TBNA. The nodes were metabolically active on PET/CT and radiologically indistinguishable from those in malignancy or granulomatous conditions.

Indoor air pollution, derived from the combustion of biomass fuel, is the primary source of exposure to biomass smoke in developing countries. Biomass fuel is any material derived from plants or animals that is deliberately burned by humans. Wood is the most common example, but in areas with little forestation, corn husks, straw, and animal dung are frequently used alternatives. Many of the substances in biomass smoke can be detrimental to health. There is in vitro evidence that many of these substances are mutagenic, and contain irritants and coagulating agents that can compromise respiratory system defenses.

Table 2. Sampled lymph nodes according to stations.

Stations of the lymph nodes	n (percent)
7	74 (36.8%)
11L	37 (18.4%)
11R	32 (15.9%)
4R	28 (13.9%)
4L	26 (12.9%)
Other	4 (1.9%)
Total	201 (100%)

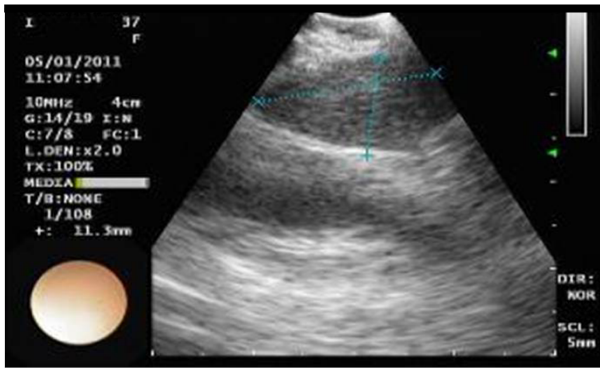


Figure 1. An endobronchial ultrasound image of anthracotic lymph node with distinct margin and homogeneous echogenicity in the right paratracheal area.

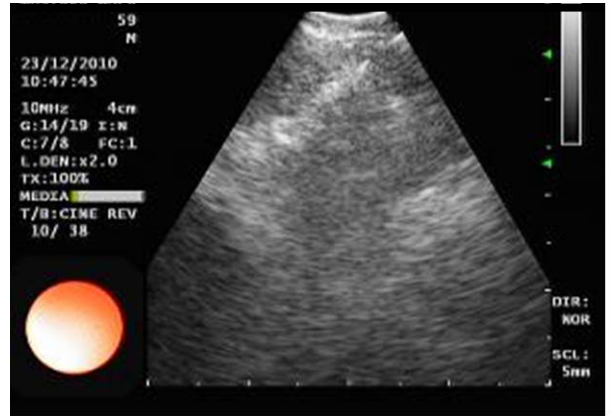


Figure 2. An endobronchial ultrasound image of anthracotic lymph node with indistinct margin and heterogeneous echogenicity in the subcarinal area.

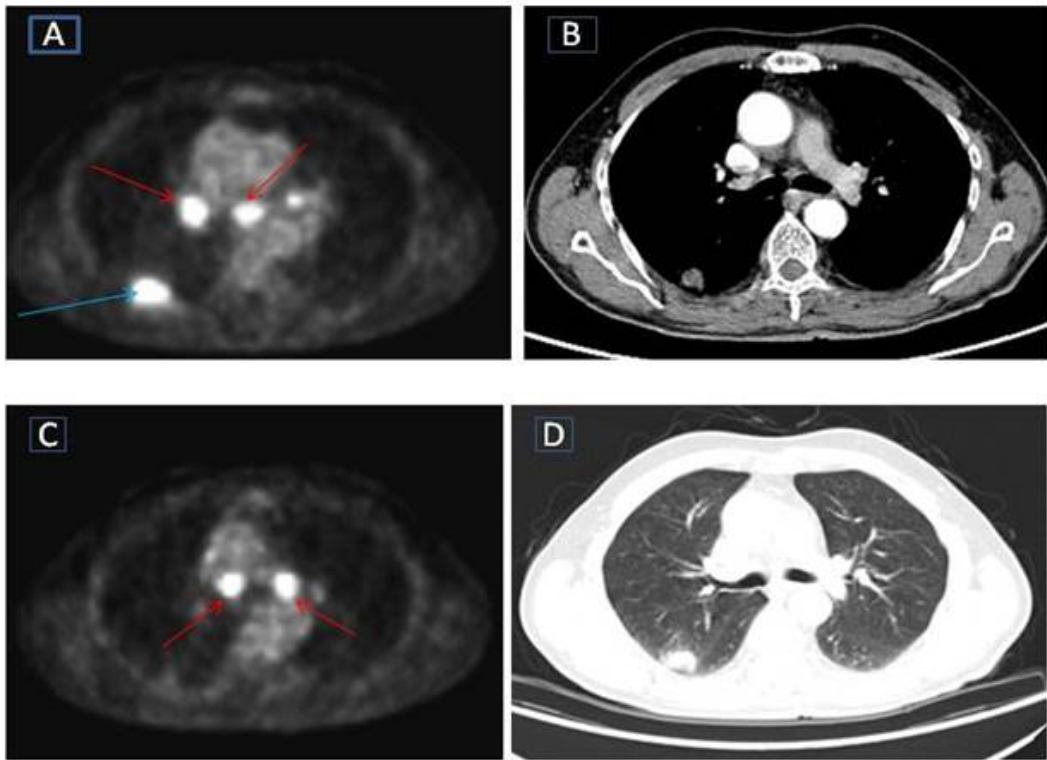


Figure 3. A 68-year-old man with pulmonary adenocarcinoma presenting for staging evaluation. He had 60 years of exposure to biomass smoke history. Axial positron emission tomography/computed tomography (PET/CT) (A) shows a right upper lobe 2.5 cm mass, maximum standardized uptake values (SUVmax): 8.23 (blue arrow); right hilar adenopathy SUVmax: 7.04; and subcarinal lymph node SUVmax: 6.04 (red arrow). (C) Axial PET/CT shows bilateral paratracheal lymph adenopathy, SUVmax: 6.86 (right) and 9.88 (left) (red arrow). (B and D) CT with mediastinal and lung windows shows a right upper lobe mass. With endobronchial ultrasound transbronchial needle aspiration, all lymph nodes were found to be anthracotic. The patient underwent mediastinoscopy and lymph nodes were anthracotic. Right upper lobectomy and lymph node dissection were performed and postoperative pathology of lymph nodes confirmed anthracosis.

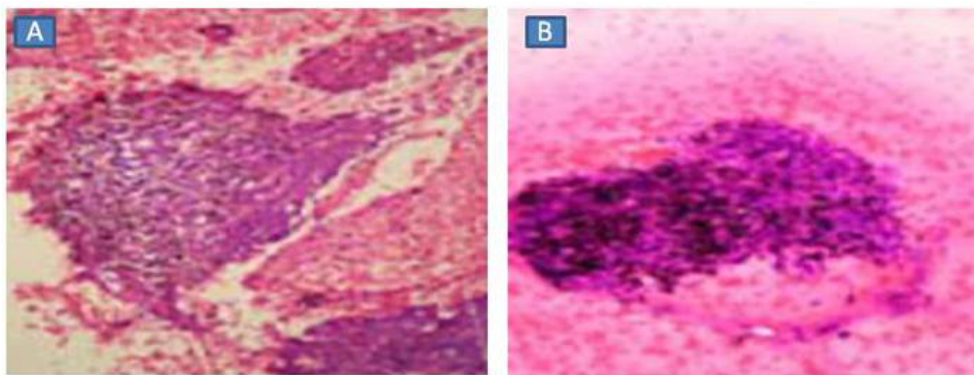


Figure 4. Pathologic preparations of patient in Figure 1. (A) Anthracotic lymph nodes in cell block (HEX400). (B) Anthracotic pigments, lymphocytes in cytological smears.

Exposure to smoke interferes with the ciliary defenses of the lungs and decreases several antibacterial properties of lung macrophages, such as adherence to glass, the phagocytic rate, and the number of bacteria phagocytosed. Through these mechanisms the risk of acute and chronic lung infections and lung cancer increases (5–8). About 50% of the world population and 90% of rural communities in developing countries are using biomass as their single source of cooking fuel (8).

Most women living in rural areas in Turkey use biomass fuels for domestic energy and are exposed to high levels of indoor air pollution in their daily lives. Ekici et al. studied the presence of chronic airway disease (CAD) in nonsmoking women in Kırıkkale and found that CAD attributed to biomass smoke exposure was found in 23.1% of that population (9). In our study, most patients were living in rural areas and the mean duration of exposure to biomass smoke was 35.45 ± 24.4 years; only 4 patients had no history of exposure.

Long-term exposure to biomass smoke, smoking, and tuberculosis are important causes of anthracosis, which is black pigment discoloration of the bronchi (10). In our study, while bronchoscopic findings of anthracotic pigmentation on only the overlying mucosa were found in 7 of the patients and anthracotic pigmentation with bronchial obliteration in 2 patients, other bronchoscopic findings were normal. Moreover, 11 patients had a history of tuberculosis or contact with tuberculosis.

EBUS-TBNA is a minimally invasive procedure performed under local anesthesia and allows real time assessment and biopsy of mediastinal lymph nodes and, therefore, often obviates the need for mediastinoscopy. It has a sensitivity of 95.7%, a specificity of 100%, and an accuracy of 97.1% in distinguishing benign from malignant mediastinal and/or hilar lymph nodes (11,12). While sampling with EBUS the reintroduction of the stylet into the needle creates friction between the two

surfaces and causes the release of metal particles. These are always obviously visible and extracellular and differ from dusts or anthracosis. Anthracosis is the most frequently encountered endogenous source of particles in mediastinal lymph node samples, and is mostly located inside macrophages, or if “scratched” during spreading of the smear, has a granular appearance and remains associated with dust-filled macrophages. Probably, the particles have been previously inhaled, phagocytosed by alveolar macrophages, and then transported by the lymphatic system to the nodes, which is in contrast with particles potentially directly released from the needle. This metal particle deposition could be associated with a potential risk of granulomatous inflammatory reaction (13,14).

Anthracosis often causes intrapulmonary lymphadenopathy, but rarely mediastinal mass, mediastinal lymphadenopathy, or axillary lymphadenopathy. Moreover, intrathoracic lymph nodes are often anthracotic in elderly persons (15). Kirchner et al. analyzed multislice computed tomography findings of EBUS-TBNA confirmed anthracosis and found that the most common site of anthracotic lymph nodes was the subcarinal area (16). In our study, subcarinal and interlobar lymph nodes were the most commonly affected stations (36.8% and 34.3%, respectively). In the same study the authors concluded that enlarged anthracotic mediastinal lymph nodes show most often an oval shape and are well-defined, nodal confluences and calcifications are frequent (16). Parallel with this, sonographic features may be very useful for evaluating mediastinal lymph nodes (17). Imai et al. compared the echoic features of mediastinal lymph nodes with sarcoidosis to those with lung cancer and found low and homogeneous echogenicity is a distinct sonographic feature of lymph nodes with sarcoidosis rather than lung cancer metastasis (18). Özgül et al. found that, although lymph nodes of patients with sarcoidosis are often round, they may have a granular appearance, homogeneous

echogenicity, and distinct margin, and logistic regression analysis revealed that the only independent predictive factor for the diagnosis of sarcoidosis was the presence of a distinct margin (12). In our study the sonographic features of the lymph nodes were 99% hypoechoic, 73.6% distinct margin, 50.7% heterogeneous, 52.7% oval, 96% necrosis absent, and 95% calcification absent. No significant interactions were identified between these sonographic parameters, SUVmax value, and exposure duration. Further prospective studies are needed that analyze the echoic findings of anthracotic lymph nodes.

Park et al. evaluated the clinical implication of microscopic anthracotic pigment in the mediastinal staging of nonsmall cell lung cancer. Furthermore, they mentioned that the lymph nodes with microscopic anthracotic pigment were metabolically active, which showed high FDG uptake, but usually were histologically benign. The researchers concluded that the accumulation of anthracotic particles could impair trapping malignant cells in lymph nodes (19). In our study, we examined both benign and malignant cases. Moreover, the SUVmax values of nonmalignant patients were found to be significantly higher than in patients with malignant disease.

FDG is a glucose analogue that is transported into both normal and malignant cells. It is not a cancer-specific agent, and false-positive findings in benign diseases have been reported. PET has greater than 90% sensitivity, but a specificity of only about 80% in diagnosing pulmonary pathology (20). Inflammatory cells such as neutrophil and activated macrophages at the site of inflammation or infection show increased FDG accumulation. Active granulomatous processes such as tuberculosis and sarcoidosis, infectious conditions such as pneumocystis carinii pneumoniae, active fibrotic lesions, pneumoconiosis, and sclerosing hemangioma have also been reported to show increased FDG accumulation and cause false-positive PET scans for malignancy (3,21–22). Imai et al.

compared mediastinal lymph nodes with sarcoidosis to those with lung cancer. The median value of the SUVmax of the targeted lymph nodes was 7.7 (range, 4.6–10.1), thus showing a high uptake indistinguishable from lung cancer metastatic lymph nodes (18). Moreover, anthracotic material can cause antigenic stimulation to macrophages. Anthracotic lymph nodes in the neck, hilar region, and mediastinum and anthracotic pulmonary nodules have all been reported to display increased FDG uptake on PET scanning (23–26). In a brief report of 6 patients with coal worker's pneumoconiosis and suspected malignancy, the mean SUVmax of nodes were 6.0 (2.8–15) (26). In another case report of mediastinal lymphadenopathy associated with anthracosis and exposure to wood smoke, the nodes were metabolically active on PET/CT and the SUVmax within the lymph nodes was 5–8.4 (14). In this study, the SUVmax value within the lymph nodes was 4.76 (1–16.8) and was indistinguishable from malignant or granulomatous conditions.

Our study has some limitations. First, ours is a retrospective review with a limited number of patients. Second, we evaluated the cases of mediastinal lymphadenopathy in which lymph node anthracosis was identified as the final primary diagnosis and so we could not compare the echoic findings of anthracosis with other malignant or benign diseases such as sarcoidosis, tuberculosis, or malignant lymph nodes.

In conclusion, anthracosis can mimic, or exist with, benign or malignant conditions. Our results suggest that anthracosis affects not only intrapulmonary lymph nodes, but also the mediastinal and hilar stations, and should be considered in the differential diagnosis of patients with mediastinal and hilar lymphadenopathies with intense uptake on PET scans in developing countries. Hereby histopathologic confirmation of mediastinal and hilar lymphadenopathy is obligatory.

References

1. Sapkota A, Gajalakshmi V, Jetly DH, Roychowdhury S, Dikshit RP, Brennan P, Hashibe M, Boffetta P. Indoor air pollution from solid fuels and risk of hypopharyngeal/laryngeal and lung cancers: a multicentric case-control study from India. *International Journal of Epidemiology* 2008; 37: 321–328.
2. Onitilo AA, Engel JM, Tanimu SB, Nguyen TC. Anthracosis and large mediastinal mass in a patient with healed pulmonary tuberculosis. *Clin Med Res* 2010; 8: 99–103.
3. Chang JM, Lee JL, Goo MG, Lee HY, Lee JJ, Chung JK, Im JG. False positive and false negative FDG-PET scans in various thoracic diseases. *Korean J Radiol* 2006; 7: 57–69.
4. Nakajima T, Yasufuku K, Takahashi R, Shingyoji M, Hirata T, Itama M, Matsui Y, Itakura M, Iizasa T, Kimura H. Comparison of 21-gauge and 22-gauge aspiration needle during endobronchial ultrasound-guided transbronchial needle aspiration. *Respirology* 2011; 16: 90–94.
5. Tuthill RW. Woodstoves, formaldehyde, and respiratory disease. *Am J Epidemiol* 1984; 120: 952–955.
6. Hosgood HD, Boffetta P, Greenland S, Amy Lee YC, McLaughlin J, Seow A, Duell EJ, Andrew AS, Zaridze D, Szeszenia-Dabrowska N et al. In-home coal and wood use and lung cancer risk: a pooled analysis of the International Lung Cancer Consortium. *Environ Health Perspect* 2010; 118: 1743–1747.

7. Akhtar T, Ulah Z, Khan MH, Nazli R. Chronic bronchitis in women using solid bio mass fuel in rural Peshawar, Pakistan. *Chest* 2007; 132: 1472–1475.
8. Bruce N, Perez-Padilla R, Albalak R. Indoor air pollution in developing countries: a major environmental and public health challenge. *Bulletin of the World Health Organization* 2000; 78: 1078–1092.
9. Ekici A, Ekici M, Kurtipek E, Akin A, Arslan M, Kara T, Apaydin Z, Demir S. Obstructive airway diseases in women exposed to biomass smoke. *Environ Res* 2005; 99: 93–98.
10. Bekci TT, Maden E, Emre L. Bronchial anthracofibrosis case with endobronchial tuberculosis. *International Journal of Medical Sciences* 2011; 8: 84–87.
11. Yasufuku K, Chiyo M, Sekine Y, Chhajed PN, Shibuya K, Lizasa T, Fujisawa T. Real-time endobronchial ultrasound-guided transbronchial needle aspiration of mediastinal and hilar lymph nodes. *Chest* 2004; 126: 122–128.
12. Ozgul MA, Cetinkaya E, Kirkil G, Ozgul G, Abul Y, Acat M, Onaran H, Urer HN, Tutar N, Dincer HE. Lymph node characteristics of sarcoidosis with endobronchial ultrasound. *Endosc Ultrasound* 2014; 3: 232–237.
13. Gounant V, Ninane V, Janson X, Colombat M, Wislez M, Grunewald D, Bernaudin JF, Cadranet J, Fleury-Feith J. Release of metal particles from needles used for transbronchial needle aspiration. *Chest* 2011; 139: 138–143.
14. Hewitt RJ, Wright C, Adeboyeke D, Ornel D, Berry M, Wickremasinghe M, Wright A, Sykes A, Kon OM. Primary nodal anthracosis identified by EBUS-TBNA as a cause of FDG PET/CT positive mediastinal lymphadenopathy. *Respiratory Medicine Case Reports* 2013; 10: 48–52.
15. Takemasa A, Bando M, Murayama F, Sohara Y, Hironaka M, Sugiyama Y. Clinical analysis of intra-pulmonary lymph nodes. *Nihon Kokyuki Gakkai Zasshi* 2001; 39: 322–327.
16. Kirchner J, Mueller P, Broll M et al. Chest CT Findings in EBUS-TBNA-proven anthracosis in enlarged mediastinal lymph nodes. *Rofo* 2014; 186: 1122–1126.
17. Fujiwara T, Yasufuku K, Nakajima T, Chiyo M, Yoshida S, Suzuki M, Shibuya K, Hiroshima K, Nakatani Y, Yoshino I. The utility of sonographic features during endobronchial ultrasound-guided transbronchial needle aspiration for lymph node staging in patients with lung cancer: a standard endobronchial ultrasound image classification system. *Chest* 2010; 138: 641–647.
18. Imai N, Imaizumi K, Ando M, Shimokata T, Ogawa T, Ito S, Hashimoto N, Sato M, Kondo M, Hasegawa Y. Echoic features of lymph nodes with sarcoidosis determined by endobronchial ultrasound. *Intern Med* 2013; 52: 1473–1478.
19. Park YS, Lee J, Pang JC, Chung DH, Lee SM, Yim JJ, Yang SC, Yoo CG, Kim YW, Han SK. Clinical implication of microscopic anthracotic pigment in mediastinal staging of non-small cell lung cancer by endobronchial ultrasound-guided transbronchial needle aspiration. *J Korean Med Sci* 2013; 28: 550–554.
20. Vansteenkiste JF, Stroobants SG. Positron emission tomography in the management of non-small cell lung cancer. *Hematol Oncol Clin North Am* 2004; 18: 269–288.
21. Lim JWM, Tang CL, Keng GHW. False positive F-18 fluorodeoxyglucose combined PET/CT scans from suture granuloma and chronic inflammation: report of two cases and review of literature. *Ann Acad Med Singapore* 2005; 34: 457–460.
22. Özgül MA, Çetinkaya E, Tutar N, Özgül G, Onaran H, Bilaceroglu S. Endobronchial ultrasound-guided transbronchial needle aspiration for the diagnosis of intrathoracic lymphadenopathy in patients with extrathoracic malignancy: a study in a tuberculosis-endemic country. *Journal of Cancer Research and Therapeutics* 2013; 9: 416–421.
23. Onitilo AA, Engel JM, Tanimu SB, Nguyen TC. Anthracosis and large mediastinal mass in a patient with healed pulmonary tuberculosis. *Clin Med Res* 2010; 8: 99–103.
24. Cheng NM, Yeh TW, Ho KC, Ng SH, Hsueh C, Yen TC, Liao CT. False positive F-18 FDG PET/CT in neck and mediastinum lymph nodes due to anthracosis in a buccal cancer patient. *Clin Nucl Med* 2011; 36: 963–964.
25. Canbaz F, Kefeli M, Sahin Z, Basoglu T. Anthracotic solitary pulmonary nodule imitating lung malignancy on F-18 FDG PET/CT imaging. *Clin Nucl Med* 2011; 36: 955–956.
26. Reichert M, Bensadoun ES. PET imaging in patients with coal workers pneumoconiosis and suspected malignancy. *Journal of Thoracic Oncology* 2009; 4: 649–651.