

An experimental comparative study on classic tube thoracostomy and thoracostomy with a newly designed thorax drainage catheter*

Mahmut TOKUR¹, Mehmet ERGİN^{2**}, Mehmet OKUMUŞ³, Zerrin Defne DÜNDAR⁴

¹Department of Thoracic Surgery, Faculty of Medicine, Kahramanmaraş Sütçü İmam University, Kahramanmaraş, Turkey

²Department of Emergency Medicine, Faculty of Medicine, Near East University, Lefkoşa, Turkish Republic of Northern Cyprus

³Department of Emergency Medicine, Faculty of Medicine, Kahramanmaraş Sütçü İmam University, Kahramanmaraş, Turkey

⁴Department of Emergency Medicine, Meram Faculty of Medicine, Necmettin Erbakan University, Konya, Turkey

Received: 21.05.2014 • Accepted/Published Online: 11.06.2015 • Final Version: 05.01.2016

Background/aim: The collection of fluids, blood, pus, or air in the pleural cavity is a pathological condition requiring pleural drainage. A newly designed thorax drainage catheter in the prototype phase was used in this experimental study to test its efficacy.

Materials and methods: A hemopneumothorax was first caused by a penetrating injury on the frontal axis of the sixth intercostal space on the right hemithorax with a scalpel on 6 female *Sus domesticus* swine subjects. After resting for 5 min, a tube or catheter was inserted. The same procedure with a tube thoracostomy or thorax drainage catheter was repeated on the left hemithorax. The time periods were recorded. After all procedures were completed, the thoracic organs were assessed for iatrogenic injuries.

Results: In terms of time elapsed for procedure, statistically significant differences between the tube thoracostomy and thorax drainage catheter applications were identified ($P < 0.05$). Additional iatrogenic injuries were nonexistent for both groups. During the thorax drainage catheter application, a surgical set or the use of sutures was not required.

Conclusion: This study showed promising results regarding the efficacy of the thorax drainage catheter for convenient use in prehospital and hospital settings by physicians with little experience with tube thoracostomy.

Key words: Trauma, penetrating, thorax drainage

1. Introduction

For pathologies that develop in the intrapleural space, and in surgical interventions involving the thorax as well as the mediastinum, drainage of the pleural cavity is generally required. Fluids, blood, pus, and gas collection in the pleural cavity are all pathological conditions that may require pleural drainage. For this procedure, thoracentesis, tube thoracostomy, and the placement of other thoracic catheters are standard methods (1,2).

Currently, tube thoracostomies are generally performed by surgeons and attached to an underwater drainage. In this method, chest drains are placed in the pleural cavity through an incision at an intercostal space (1,2).

The thorax drainage catheter is a new design that is in the prototype phase (Figure 1). This method does not require the use of surgical tools or suture materials. This new design has a form similar to that of the Foley

catheter and is composed of a tube with 2 or 3 channels. An inflatable balloon is located at its tip. Clips and an umbrella-like lid differentiate it from a Foley catheter. On the outside of the catheter, there is a sharp-tipped metallic tubular guide. This guiding tube creates an entry hole in the skin, subcutaneously, and intercostal tissue without the need of surgical dissection for the placement of a drain to enable it to reach the pleural space. The thorax drainage catheter is then fixed in place by the lid and clips, and no suture is necessary (Figures 2–4). The main objective for the development of the thorax drainage catheter is that its use does not require “specialist training” and it is easy to use in prehospital health service settings. This experimental study, which is the first study regarding the thorax drainage catheter, was undertaken to test the efficacy of the new thorax drainage catheter in practice.

* This article was accepted as a poster presentation at the 7th Mediterranean Emergency Medicine Congress, Marseille, France, 8–11 September 2013.

** Correspondence: drmehmetergin@gmail.com

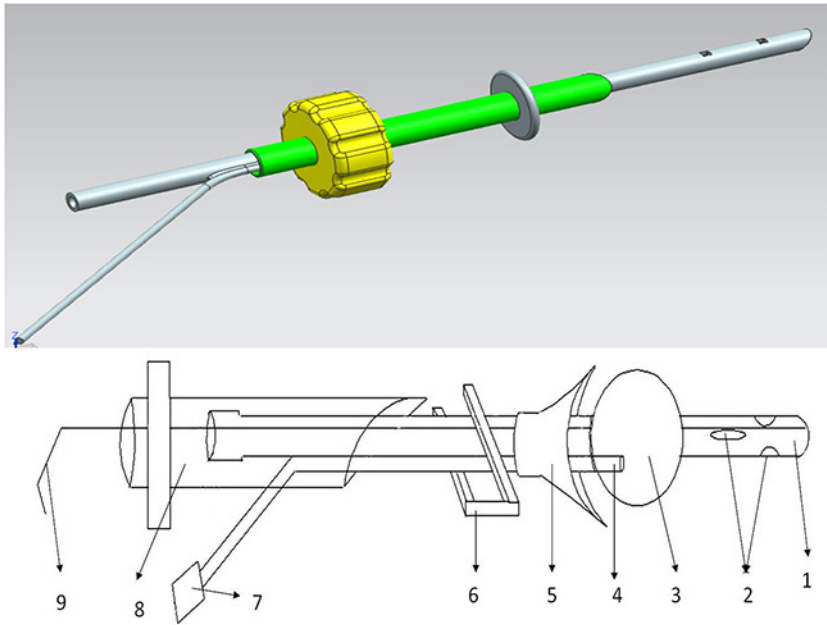


Figure 1. The technical drawing of the newly designed thoracic drainage catheter. 1- The drainage that is inserted into the thoracic cavity, 2- the holes that permit air or fluid passage, 3- the balloon that prevents the catheter getting out of the thoracic cavity, 4- the air channel that can inflate the balloon, 5- the cover that fixes the catheter in its location, 6- the clips that can lock the cover, 7- the valve that controls air or fluid passage into the air channel-inflating balloon, 8- the guide pipe with a sharp edge at the end that permits the catheter to pass the cutaneous and subcutaneous layers of the thoracic wall, 9- the guide wire that enables location of the catheter in the thoracic cavity.

2. Materials and methods

2.1. Overview of the experimental animal groups

In this study, six 1-year-old female *Sus domesticus* swine subjects, each weighing 55 to 60 kg, were used. All animals were kept under a 12/12-h light/dark cycle at a constant temperature (22 °C) and allowed free access to food and tap water. The animals were not fed for 24 h prior to the experiment but were provided with water. The Çukurova University School of Medicine Ethical and Experimental Committee approved all experimental procedures. All investigators complied with the 1996 Guide for the Care and Use of Laboratory Animals. All precautions were taken to reduce the total number of animals required and to minimize their discomfort. Immediately after the penetrating thorax injury, animals were randomly assigned to 2 groups. During the experiment, vascular access was obtained through the *V. auricularis lateralis* with a 0.9% isotonic fluid infusion. For anesthesia, subjects were given a combination of Rompun (2 mg/kg, IM) + ketamine (13 mg/kg IM). For the reduction of secretion, a dose of 0.2 mg/kg atropine sulfate was given intravenously. After the subjects were intubated with an endotracheal tube (size no. 9) under general anesthesia, they were placed in a

supine position on the surgery table. Their front and side chests were shaved, and antiseptic betadine was applied to this area. Oxygen support was provided throughout anesthesia. Vital signs were noninvasively monitored using a transcutaneous measurement device for heart rate. All subjects were sacrificed with a high dosage of ketamine HCL after the required measurements were taken.

2.2. Induction of the penetrating thorax injury and the insertion of tubes and catheters

Subjects were randomly assigned to 1 of the 2 groups, each with 3 swine. A hemopneumothorax was caused in all animals by a penetrating injury on the frontal axis of the sixth intercostal space (ICS) on the right hemithorax with a scalpel (20 cm long) by the same researcher. The subjects were allowed to rest for 5 min, and then a tube or catheter was inserted. Upon completion of the procedure on the right hemithorax, the same procedure was repeated on the left hemithorax and another tube thoracostomy or thorax drainage catheter was inserted on that side. The same researcher performed the tube thoracostomy and thorax drainage catheter at the seventh ICS and midaxis with a 14-F tube/catheter. In Group 1, at the right and left

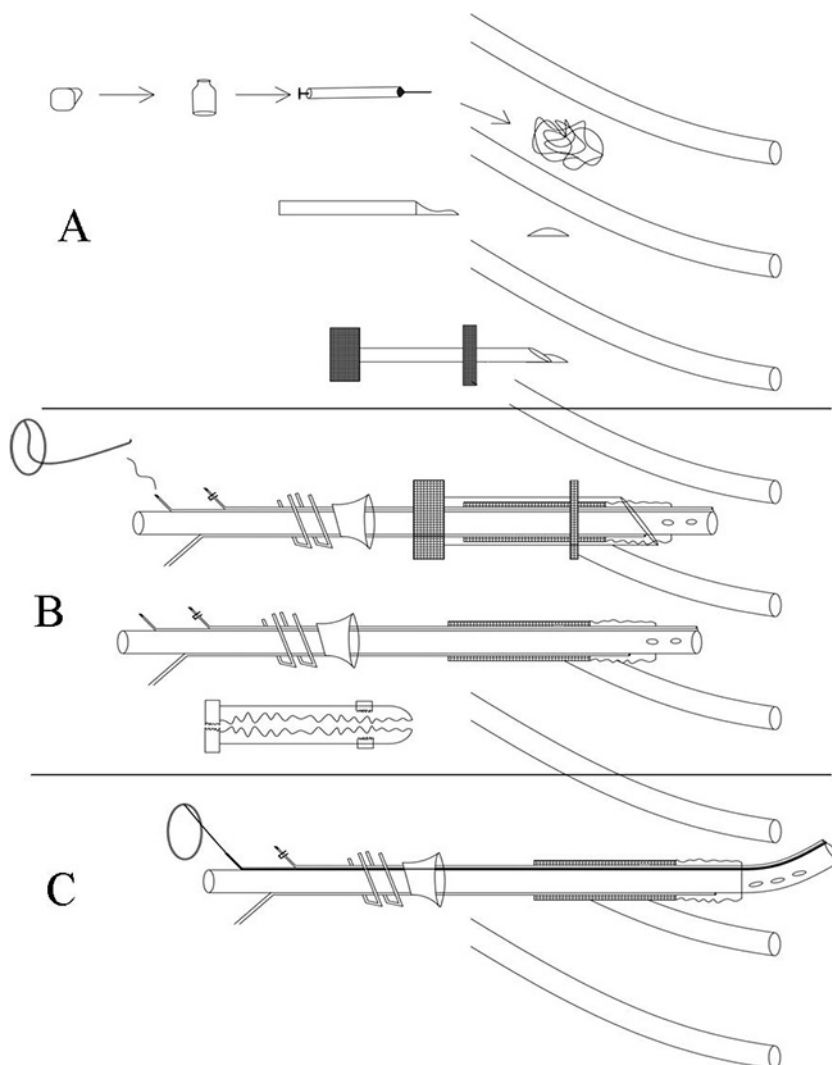


Figure 2. The drawing of the procedure for the insertion of the newly designed thoracic catheter (A–C). A) Disinfect and apply local anesthesia. B) If needed, make an incision in the skin with a scalpel. Then hold the guide pipe with the sharp edge at the end and pass through the cutaneous and subcutaneous layers of the thoracic wall. C) Insert the catheter into the thoracic cavity through the guide pipe with the help of the guide wire.

hemithoraces of subjects, a tube thoracostomy and thorax drainage catheter were inserted, respectively, and in Group 2, the same procedures on the opposite sides was repeated after penetrating injury to the frontal axis of the sixth ICS on the left (Tables 1 and 2). The time periods for the interventions were recorded. After the procedures, both chest cavities of the subjects were opened by transverse thoracotomy, and their thoracic internal organs were examined to see whether any iatrogenic injuries existed.

2.3. Statistical analysis

Numerical data are presented as mean \pm standard deviation, t-tests were used, and $P < 0.05$ was considered evidence of statistical significance. All computations were performed using SPSS 10.0 (SPSS Inc., Chicago, IL, USA).

3. Results

According to the times obtained in terms of elapsed time and the periods required for performing the tube thoracostomy procedure on the right and left hemithoraces, there was no statistically significant difference ($P > 0.05$). For the insertion of the thorax drainage catheter procedure on the right and left hemithoraces, we also did not find any statistically significant difference ($P > 0.05$).

In the experiment performed on the subjects, the thorax drainage catheter was inserted in a shorter period than the tube thoracostomy. In terms of length of time for the invasive procedure, a statistically significant difference between the tube thoracostomy and the thorax drainage catheter application was identified ($P < 0.05$).

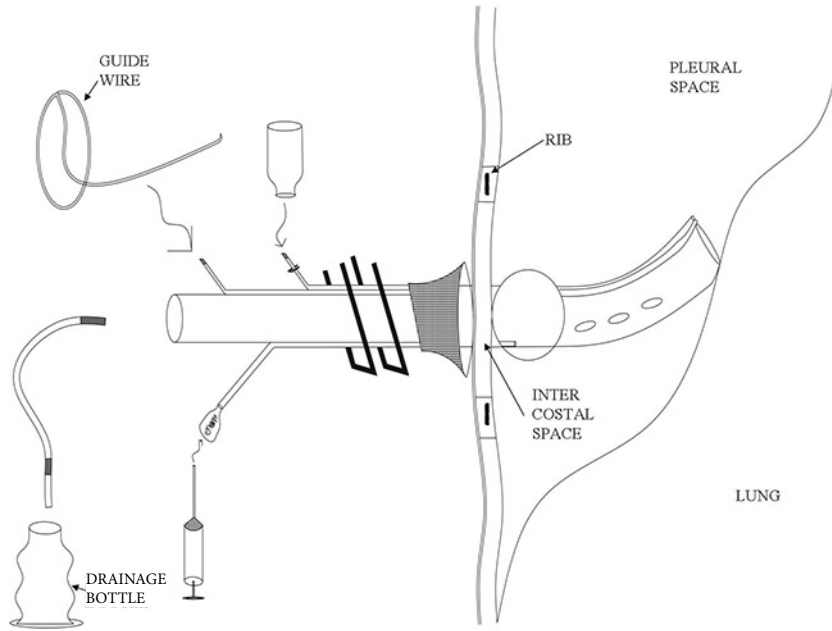


Figure 3. The drawing of procedure for affixing the newly designed thoracic catheter in the pleural space. After insertion of catheter, inflate the balloon through the air channel to prevent the catheter from getting out of the thoracic cavity. Then locate the cover and lock it by the clips to fix the catheter at its location. This ensures that the discharge of air, blood, or other fluid will flow through the holes of the catheter into the drainage bottle.

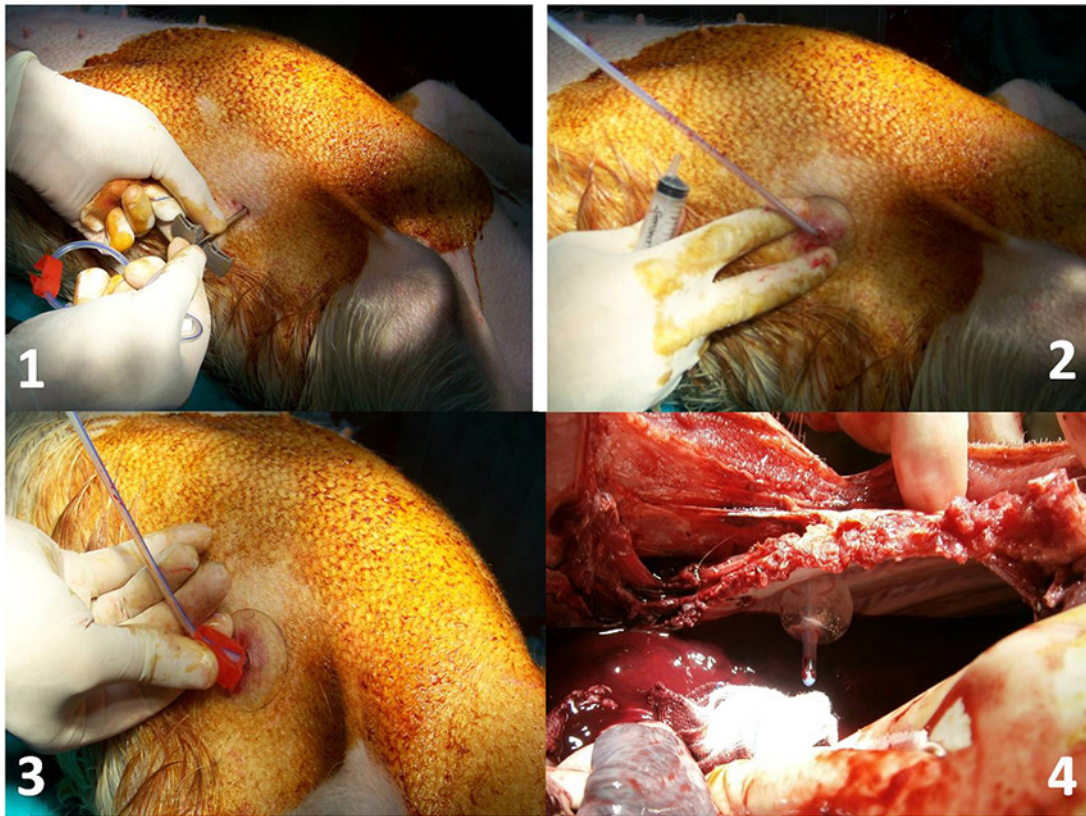


Figure 4. The procedure for insertion of the newly designed thoracic catheter during experimental study [1–4].

Table 1. The location and time duration of procedure for tube thoracostomy in both study groups.

Groups	Group 1			Group 2		
Subject	No. 1	No. 2	No. 3	No. 4	No. 5	No. 6
Side	Right	Right	Right	Left	Left	Left
Location (ICS)	7	7	7	7	7	7
Duration of procedure (min.s)	7.25	6.53	6.35	5.52	6.18	5.38
Mean time (min.s)	6.71 ± 0.48			5.69 ± 0.43		

ICS = Intercostal space.

Table 2. The location and time duration of procedure for newly designed thorax drainage catheter in both study groups.

Groups	Group 1			Group 2		
Subject	No. 1	No. 2	No. 3	No. 4	No. 5	No. 6
Side	Left	Left	Left	Right	Right	Right
Location (ICA)	7	7	7	7	7	7
Duration of procedure (min.s)	2.16	2.28	3.10	2.21	2.34	2.29
Mean time (min.s)	2.51 ± 0.51			2.28 ± 0.07		

ICS = Intercostal space.

After the procedures, both chest cavities of the subjects were opened by transverse thoracotomy, and internal organs were assessed to see whether intervention-related iatrogenic injuries existed. In both groups, with the exception of the planned work model injury, no organ injuries were observed.

While the researcher utilized surgical set and suture material during the tube thoracostomy procedure, there was no need for these materials during the thorax drainage catheter application.

4. Discussion

Following Lilienthal's use of the chest tube in 1922 on patients who had undergone thorax surgery, this approach became the norm for the drainage of the pleural cavity (3). At present, however, none of the current thorax drainage systems are ideal. For surgeons, two characteristics are important: 1) the system should meet the physiologic and therapeutic needs of the patient, and 2) it should be designed so that it is functional and can be easily used by the entire surgical team (1).

Tube thoracostomy is recognized as the process of placing chest tubes into the pleural cavity for the drainage of air or fluid under sterile conditions. For this reason, tube-type

drainers and chest tube passers are used most frequently. When vials containing a certain amount of normal saline solution are attached to the tips of these drainers, the system is referred to as underwater drainage connected with a chest tube (2). There are complications from chest tube placement, and the morbidity is between 9% and 21%. The most frequently seen complications are tube inadequacy for the effusion or drainage of fluids, pain at point of entry, emphysema, injury to proximal organs or the lung, wrong or inappropriate placement of the tube, and recurrent pneumothorax or effusion (4,5). As in other intrathoracic procedures, if the procedure is indicative, well planned, and carefully executed, and if the surgeon is experienced in the technique and knowledgeable of intercostal space anatomy, then the incidences of complication are kept to a minimum (1). In a retrospective study, Etoch et al. demonstrated that the complication rate among trauma patients who received a tube thoracostomy in the emergency department is much higher compared to when the tube thoracostomy is performed by a surgeon (13% versus 6%). Based on this finding, it is recommended that this technique should only be performed by experienced clinicians (6).

In conclusion, our experimental study was performed on swine subjects with the prototype of our newly developed

thorax drainage catheter, and we determined that the procedure is faster, the need for surgical set is eliminated, and there is no difference in terms of additional iatrogenic injury. We are of the opinion that, due to this design's ease of application by emergency physicians and other surgeons outside of chest surgery, it exhibits significant potential

for wide use in prehospital, emergency, and in-hospital settings. Prospective controlled random investigations following advanced production of the prototype and the issuance of required permits are planned for the near future.

References

1. Yıldızeli B, Yüksel M. Plevra hastalıklarında cerrahi teknikler. *Toraks Derg* 2002; 3: 27–41 (in Turkish).
2. Tokur M, Kürkçüoğlu İC, Koç HT. Plevral boşluğun drenaj yöntemleri, dren çeşitleri ve dren takip esasları. *JCAM* 2012; 79–85 (in Turkish).
3. Lilienthal H. Resection of the lung for suppurative infections with a report based on 31 operative cases in which resection was done or intended. *Ann Surg* 1922; 75: 257–320.
4. Mathur PN. Therapeutic local procedures: chest tubes and therapeutic thoracentesis. *Eur Respir Mon* 2002; 22: 297–310.
5. Laws D, Neville E, Duffy J. BTS guidelines for the insertion of a chest drain. *Thorax* 2003; 58: 53–59.
6. Etoch SW, Bar-Natan MF, Miller FB, Richardson JD. Tube thoracostomy: factors related to complication. *Arch Surg* 1995; 130: 521–525.