

The effect of low-dose methotrexate on autologous fat graft survival

Elif SARI^{1*}, Bülent BAKAR², Bahram SARKARATI³, Önder BOZDOĞAN⁴, Tarık ÇAVUŞOĞLU⁵

¹Department of Plastic, Reconstructive, and Aesthetic Surgery, Faculty of Medicine, Kırıkkale University, Kırıkkale, Turkey

²Department of Neurosurgery, Faculty of Medicine, Kırıkkale University, Kırıkkale, Turkey

³Department of Biochemistry, Faculty of Medicine, Hacettepe University, Ankara, Turkey

⁴Department of Pathology, Faculty of Medicine, Kırıkkale University, Kırıkkale, Turkey

⁵Plastic, Reconstructive, and Aesthetic Surgery Clinic, Memorial Hospital, Ankara, Turkey

Received: 02.03.2015 • Accepted/Published Online: 13.09.2015 • Final Version: 23.06.2016

Background/aim: The survival of autologous fat graft tissue is dependent on various factors such as vascularization and inflammation. The aim of the present study was to evaluate the possible beneficial effects of low-dose methotrexate (LD-MTX) on fat graft volume and survival.

Materials and methods: A total of 13 male Wistar albino rats were divided into two groups, a control group and an LD-MTX group. An autologous fat graft obtained from the inguinal region of each rat was transferred to its back. LD-MTX was administered intraperitoneally in the LD-MTX group once a week for 4 weeks after the surgical procedure. The control group underwent surgery but was not administered MTX. Fat grafts were harvested for analyses.

Results: The results showed that 2 months postoperatively the fat graft weights of the control and LD-MTX groups were not significantly different. In addition, the vascularity of the grafts was higher in the LD-MTX group than it was in the control group. The mean lipid peroxidation levels were essentially the same in the two groups, but myeloperoxidation was significantly lower in the LD-MTX group than it was in the other group.

Conclusion: The results showed that LD-MTX administration may not preserve the quality and volume of transplanted fat tissue in rats.

Key words: Fat graft, fat graft survival, methotrexate

1. Introduction

Fat tissue, which is nontoxic, nonallergic, and simply harvested, is confirmed as an ideal autologous soft tissue filler (1,2). It can be used in several procedures such as facial aesthetic surgery, body contouring, scar revisions, and velopharyngeal insufficiency (3,4). However, unpredictable long-term survival is a disadvantage of this natural tissue because the grafted fat tissue frequently encounters inflammation, ischemia, and apoptosis in the recipient area (5). To solve this problem, vascular endothelial growth factor (VEGF) (6), platelet-rich plasma (7), and platelet-rich fibrin (7) have been used in autologous fat tissue transfers to increase the vascularity of the fat graft. Additionally, antitumor necrosis factor alpha (anti-TNF- α) and washing of the fat graft could decrease inflammatory mediators and have been used to prevent inflammation of the transplanted fat graft (8).

Low-dose methotrexate (LD-MTX) has become popular in the treatment of inflammatory diseases such

as rheumatoid arthritis and graft-versus-host diseases, since it has been demonstrated that LD-MTX can reduce the destructive effects of the leukocytes and inhibit proliferation of the lymphocytes at the inflammatory site (9). The immunomodulatory effects of LD-MTX are related with increasing adenosine levels in the inflammatory area. High levels of adenosine inhibit the production of TNF- α , interleukin 1 (IL-1), IL-6, IL-8, interferon gamma (IFN- γ), superoxide, and nitric oxide (10). Furthermore, adenosine is a cytoprotective molecule due to decreasing toxic oxygen metabolites (11).

The aim of this experimental study was to investigate the possible beneficial effects of LD-MTX on fat graft survival.

2. Materials and methods

2.1. Materials

All the experimental animals were handled according to the guidelines of the care and use of laboratory animals

* Correspondence: drelifsanli@hotmail.com

as stated by the Ankara Education and Research Hospital Experimental Animal Laboratory Ethical Committee (Number: 0015 / 229).

A total of 13 male Wistar albino rats weighing between 250 and 300 g were taken for the study. Methotrexate (MTX; Koçak Farma 50 mg/5 mL, İstanbul, Turkey) was used in this study. Its intraperitoneal LD₅₀ is 6 mg/kg in rats.

Anesthesia was performed with an intraperitoneal (IP) administration of 40 mg/kg ketamine HCl (Ketalar; Pfizer Inc., USA) and 5 mg/kg xylazine HCl (Rompun 2%; Bayer HealthCare AG, Germany).

The animals were divided into two groups randomly:

- Control group (only fat transplantation was performed and no experimental drug was administered to the rats) (n = 6),

- LD-MTX group (0.01 mL of methotrexate dissolved in 0.09 mL of saline was administered intraperitoneally once a week for 4 weeks) (n = 7).

2.2. Surgery

After ketamine HCl and xylazine HCl induced anesthesia, the animals were placed in a supine position. The left inguinal area of the rat was cleaned with betadine solution. No local anesthetic or adrenaline was injected before the fat dissection. An oblique 3-cm incision was made to the left inguinal area (Figure 1). The fat tissue dissected from the inguinal area was excised, dried with sterile gauze, and weighed with a precision scale (Shimadzu AX-200, USA) before the transfer. The value of each fat graft weight obtained from the inguinal area (i.e. in the time period called 'before') was noted separately. After the removal of the fat grafts, the inguinal incision was sutured with 2/0 silk and the animals were placed in a prone position.

After cleaning the surgical field with betadine solution, a 1-cm incision was made to the dorsal interscapular area and a 1 × 1 cm pocket was prepared over the panniculus carnosus for fat grafts (Figure 1). The harvested autologous fat tissues were washed with saline and cut into pieces approximately 2–4 mm in length in all dimensions with microscissors, and then each autologous fat graft cut into pieces was inserted into the pockets (6). The LD-MTX group was administered 0.01 mL of methotrexate diluted in 0.09 mL of saline intraperitoneally once a week for 4 weeks; the control group was not administered any drugs.

Two months after the fat grafting, all animals were reseeded by the same procedure and they were sacrificed using the cardiac air embolization technique. The fat grafts were then removed carefully from the recipient pockets and dried. Each fat tissue was weighed again with the same precision scale and the results (i.e. for the time period called 'after') were noted. The fat graft that was harvested from each animal was then divided into two equal portions: half of the specimen was put into 10% buffered formaldehyde for histopathological examination, and the remaining half was immediately stored at -30 °C in dry air for biochemical evaluation.

2.3. Histopathological analysis

For histopathological examination, all tissue samples were fixated in 10% buffered formaldehyde and processed according to the routine light microscopic tissue processing technique. Serial sections of 5 µm in thickness stained with hematoxylin and eosin were examined and photographed. Images were obtained with a digital camera connected to a microscope equipped with an automatic scanning table (DSRi1, Nikon's inverted Eclipse Ti, Nikon France S.A., France). The area of adipocytes in each group

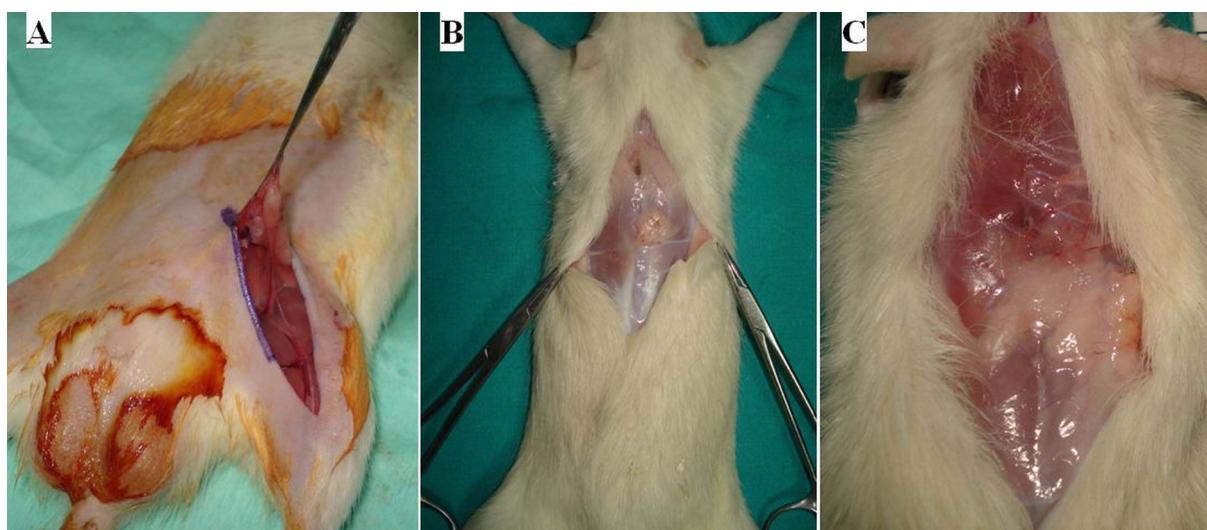


Figure 1. The surgical procedures. (A) An incision was made to the inguinal region to obtain the fat graft. The photographs reveal the fat graft before removal from the (B) control group and the (C) LD-MTX group, respectively.

was measured separately using 40× magnification of the graft by using a software program (Nikon NIS- Elements Advanced Research (AR), version 4.0, Nikon Instruments, Japan). A total of 5 random fields were examined, totaling 25 points per slide. The total areas of the adipocytes and fibrotic areas were calculated as an average per rat. The percentage rate of fat tissue area compared with the total microscope viewing area was calculated. This ratio was defined as the relative adipocyte index (Figure 2). The vessel count was done using a microscope (Olympus BX50) to view a 10× magnification of the graft, and the total vessel number (i.e. vascularity level) was calculated for each rat. A total of 4 random fields were examined, totaling 20 points per slide. Inflammation degree was measured by an inflammation scale (Table 1). Fat necrosis was another histological parameter determined with the same microscope as presence of fat necrosis (point 1) or absence (point 0) subjectively. All specimens were evaluated by an experienced histopathologist (ÖB) blinded to the study groups and experimental material.

2.4. Biochemical analysis

Myeloperoxidase (MPO) and lipid peroxidase (LPO) levels of the fat graft tissues obtained from the dorsal pockets of the animals were measured by spectrophotometry (Shimadzu UV-1700 Spectrophotometer) (12,13). All specimens were evaluated by an experienced biochemist (BS) blinded to the study groups and experimental material. Biochemical analyses were performed with a thiobarbituric acid application and then 532 nm spectrophotometry was used to measure the LPO levels in nanomoles per gram of wet tissue. Tetramethylbenzidine was applied to the tissues and then 655 nm spectrophotometry was used to measure the MPO levels calculated as units per gram of wet tissue according to the amount of absorbance change (12,13).

2.5. Statistical analysis

Statistical analyses were performed using the SPSS 17.0. A normality test was performed in the beginning of the

statistical analysis. The results that were normally distributed and homogeneous variations were statistically analyzed by an independent-samples t-test. Nonnormally distributed results and nonhomogeneous variations were analyzed by the Mann–Whitney U test. Furthermore, a paired-samples t-test was performed to determine the statistical differences between the fatty tissue weight values for each group.

3. Results

The values of the fat graft weights ‘before’ and ‘after’, the vascularity level of ‘after’, and the LPO level values of ‘after’ were normally distributed and variations were homogeneous between the groups. Therefore, they were statistically analyzed by an independent-samples t-test. The tests revealed that the inflammation grade, fat necrosis grade, fibrotic area level, adipocyte index percentages, and tissue MPO level values of ‘after’ were not normally distributed and the variation was not homogeneous between the groups. Therefore, these values were analyzed by use of the Mann–Whitney U test. Furthermore, a paired-samples t-test was performed to determine the statistical differences between the fatty tissue weight values of ‘before’ and ‘after’ for each group.

3.1. Macroscopic findings

Upon macroscopic inspection, no local inflammation or abscess was observed at the surgical areas, and the vascularities of the control and LD-MTX groups were almost the same. The preserved fat tissue volumes were also almost equal in both groups. During the sample collection period, a fibrous capsule formation, which separated the grafted fat tissue from the adjacent soft tissue, was observed around all graft tissues (Figure 1).

3.2. Light microscopy

Upon light microscopy, there was evident vascular congestion in the LD-MTX group. However, inflammation grades and viable adipocyte distributions were similar in both groups (Figure 2).

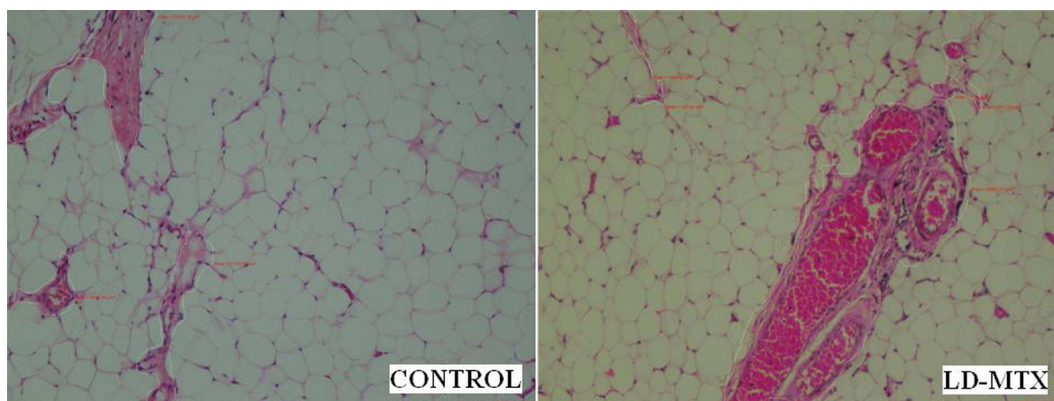


Figure 2. Histopathological measurement method of the relative adipocyte index in the two groups. A dense vascularization of the graft tissue can be easily seen in the LD-MTX group.

Table 1. Histopathological inflammation scale for the detection of inflammation levels of the groups.

Grade	Description
Grade 0	No inflammation or a few scattered lymphocytes.
Grade 1	One small group of lymphocytes (10–20).
Grade 2	One large group of lymphocytes (>20), or two small groups.
Grade 3	Diffuse lymphocyte infiltration or more than one large group of lymphocytes.

3.3. Fat graft weight values

Fat graft weight values were compared both between the groups and inside of each group. At the beginning of the experiment ('before'), there was statistically no difference between the groups for the weight of the fat graft obtained from the inguinal region of the rat ($P = 0.072$). At the end of the study ('after'), the weight values of the fat graft were again not statistically different between the groups ($P = 0.098$) (Tables 2 and 3; Figure 3). However, when the mean values of the fat graft weights of the two groups were compared, the values of 'before' were significantly different from those of 'after' in the control group ($P = 0.046$) and in the LD-MTX group ($P = 0.008$) (Table 3).

3.4. Histopathological findings

The fibrotic tissue diameter values around the fat grafts ($P = 0.775$), inflammation grade values ($P = 0.876$), fat necrosis values ($P = 0.409$), and adipocyte index percentage values ($P = 0.775$) were not significantly different between the groups (Tables 2 and 4; Figure 4). However, the vascularity level values were statistically significantly higher in the

LD-MTX group than the control group ($P = 0.007$) (Tables 2 and 5; Figure 4).

3.5. Biochemical findings

LPO level values were not statistically different between the groups ($P = 0.273$), although the MPO level values were statistically significantly lower in the LD-MTX group than the control group ($P = 0.022$) (Tables 4 and 6; Figure 5).

4. Discussion

LD-MTX was recently reported to be an inhibitor of lymphocyte proliferation and the destructive capacity of leukocytes that reach the inflammatory area (14). It also promotes extracellular adenosine accumulation at the inflammatory site, which inhibits some cytokines, superoxide, nitric oxide, and TNF- α (14,15). Adenosine is a cytoprotective molecule due to its inhibitor effect on toxic oxygen metabolites created from the adhesion of stimulated neutrophils to the endothelium (11,16). Decreasing the inflammation and apoptosis at the fat graft area is a recently investigated method to increase long-

Table 2. Descriptive table of the fat graft weights, inflammation grade, fat necrosis grade, vascularity level, fibrotic area, and adipocyte index values of each group (N: number of cases, SD: standard deviation).

Groups	Time	N	Mean	SD
Control	'Before' weight value	6	0.446	0.18
	'After' weight value	6	0.198	0.09
	Inflammation level	6	1.17	0.98
	Fat necrosis level	6	0.33	0.52
	Vascularity level	6	27.43	6.25
	Fibrotic area	6	588,489.83	448,611.56
	Adipocyte index	6	79.26	15.82
LD-MTX	'Before' weight value	7	0.679	0.23
	'After' weight value	7	0.337	0.17
	Inflammation level	7	1.00	0.82
	Fat necrosis level	7	0.57	0.53
	Vascularity level	7	45.41	12.02
	Fibrotic area	7	463,778.51	140,894.40
	Adipocyte index	7	83.67	4.95

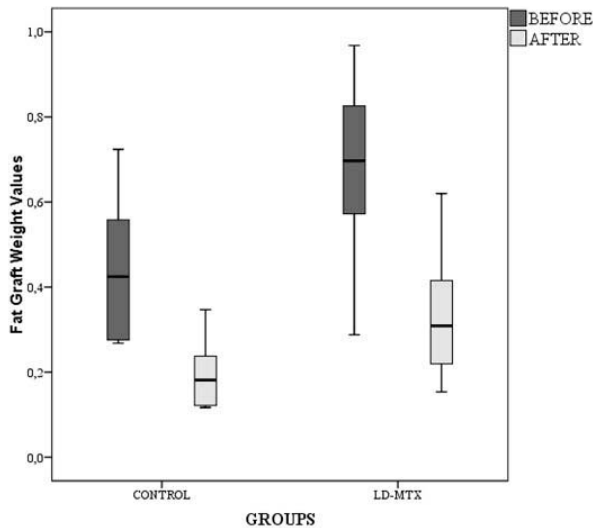


Figure 3. The mean values of the fat graft weights of the LD-MTX group compared to the control group. Each error bar shows the minimum and maximum of the fat graft weight values.

term fat graft survival (5). Yang et al. evaluated the TNF- α antibody in fat transplantation and found that anti-TNF- α could be effective in increasing the fat graft survival due to its antiapoptotic and antinecrotizing effects (8). Based on these findings, we investigated the influence of LD-MTX on fat graft survival.

In the present study, the fat graft weight values of both groups were similar for 'before' and 'after'. However, at the end of the study, the mean value of 'after' was lower than the mean value of 'before' for each group. Unfortunately, these results may suggest that LD-MTX administered intraperitoneally is not effective in preserving the graft volumes.

To the best of our knowledge, the effect of LD-MTX on vascularity of soft tissues has not been investigated in the literature yet. In the present study, the vascularity level values were higher in the LD-MTX group than they were in the control group. Perhaps LD-MTX may have a positive effect on growth factors (such as VEGF) that enhance fat graft vascularization. However, more

Table 3. This table demonstrates that the fat graft values of the 'before' tests were significantly statistically different from the 'after' tests' values in both groups

Group	P
Control	0.046
LD-MTX	0.008

P < 0.05.

Table 4. This table reveals that the fibrotic tissue diameter values around the fat grafts, inflammation grade values, fat necrosis values, and adipocyte index percentage values did not differ statistically between the groups. On the contrary, MPO levels were significantly lower in the LD-MTX group than in control group (Z = Z score of the statistical analysis).

Variable	Z	P
Inflammation level	-0.157	0.876
Fat necrosis level	-0.825	0.409
Fibrotic area	-0.286	0.775
Adipocyte index	-0.286	0.775
MPO	-2.286	0.022

P < 0.05.

detailed studies should be done to support this hypothesis. Chronstein et al. (9) showed that LD-MTX can inhibit proliferation of lymphocytes and activity of leukocytes. However, adipocyte index, inflammation, and fat necrosis values were not significantly different between the groups in our study. According to these results, it can be argued that vascularization alone is not sufficient to increase the fat graft survival.

Fat graft loss is caused by the development of hypoxic and ischemic conditions because of the decreased vascular supply around the free fat graft tissue (17–20). Hypoxia generates potent oxidizing species (e.g., superoxide radicals, hydroxyl radicals, and hydrogen peroxide), which mediate the lethal cell injury by initiating the peroxidative decomposition of phospholipids, both in the cellular and the mitochondrial membranes. MPO activity was previously shown to correlate with the absolute number of phagocytes and their activation in the inflamed tissue. Neutrophils and other phagocytes (e.g., macrophages) produce hypochloride, a strong oxidant that acts on hydrogen peroxide and chloride ions during MPO (21,22). LPO plays an important role in the pathogenesis of lethal cell injury by degrading cellular and mitochondrial membranes (22). It was demonstrated in the literature that LD-MTX has different effects on LPO levels in different studies (23,24). However, these studies were about spinal cord injury. The biochemical findings of the present study revealed that LD-MTX could not decrease the LPO levels in fat graft tissue. Although this study did not employ more specific biochemical analysis methods (such as measurements of nitric oxide, glutathione, superoxide dismutase levels, etc.), this result may mean that this material cannot decrease the free radicals and their destructive effects in fat grafts in rats.

There are different results about the effect of LD-MTX on MPO levels in the literature. Although LD-MTX could

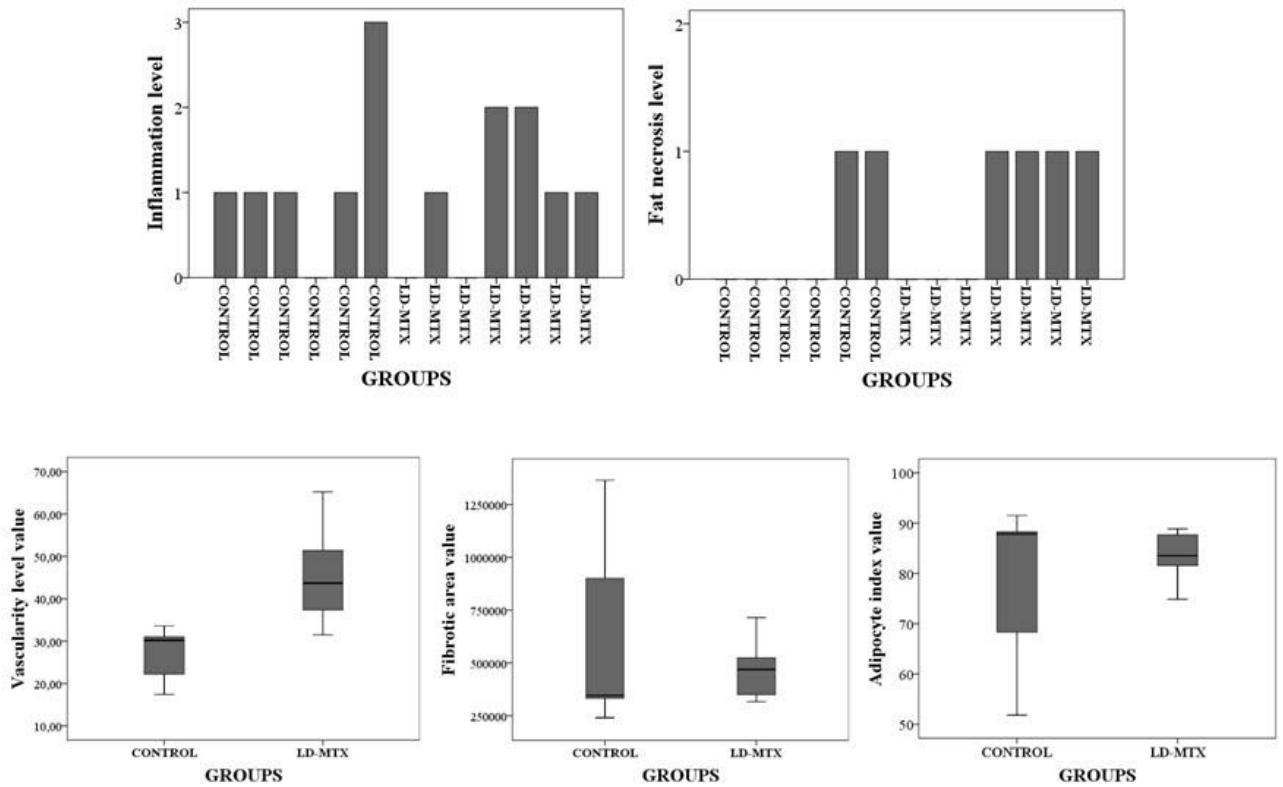


Figure 4. Inflammation, fat necrosis, vascularity, fibrosis levels, and adipocyte index values of the LD-MTX group compared to the control group. Each error bar shows the minimum and maximum values of the vascularity and fibrotic area diameter. Each bar shows the inflammation level and fat necrosis.

not affect the MPO levels in spinal cord injury according to the study of Bakar et al. (23), MPO levels were decreased in another study about spinal cord injury (24). However, it did lead to a decrease in the MPO levels in the LD-MTX group in the present study. This may mean that LD-MTX could decrease or block the myeloperoxidase enzyme activation originating from the lysosomes of the inflammatory cells. However, the lipid peroxidation level values were not statistically different between the groups and the fat graft weight volumes could not support this theory.

Table 5. This table shows that only the vascularity level values were statistically different between the groups.

Variable	P
'Before' weight value	0.072
'After' weight value	0.098
Vascularity level	0.007
LPO	0.273

P < 0.05.

Our study has some limitations. First, more sophisticated biochemical analyses used to identify the inflammatory pathways that influence fat graft survival and volume (e.g., apoptosis, glutathione and nitrite/nitrate levels, and oxidase activity) were not possible in our laboratory. Thus, the mechanism of the effect of LD-MTX on LPO and MPO cascades remains to be determined. Second, excised and aspirated adipose tissues have different characteristics in clinical practice (25). Therefore, aspirated fat tissue with vasoconstrictor solutions can be evaluated in future studies. Third, saline was not

Table 6. Descriptive table of the biochemical analyses findings of each group (LPO: lipid peroxidation; MPO: myeloperoxidation; SD: standard deviation; N: number of cases).

Groups	Variable	N	Mean	SD
Control	LPO	6	46.237	11.70
	MPO	6	41.267	53.56
LD-MTX	LPO	7	63.847	35.56
	MPO	7	6.557	5.11

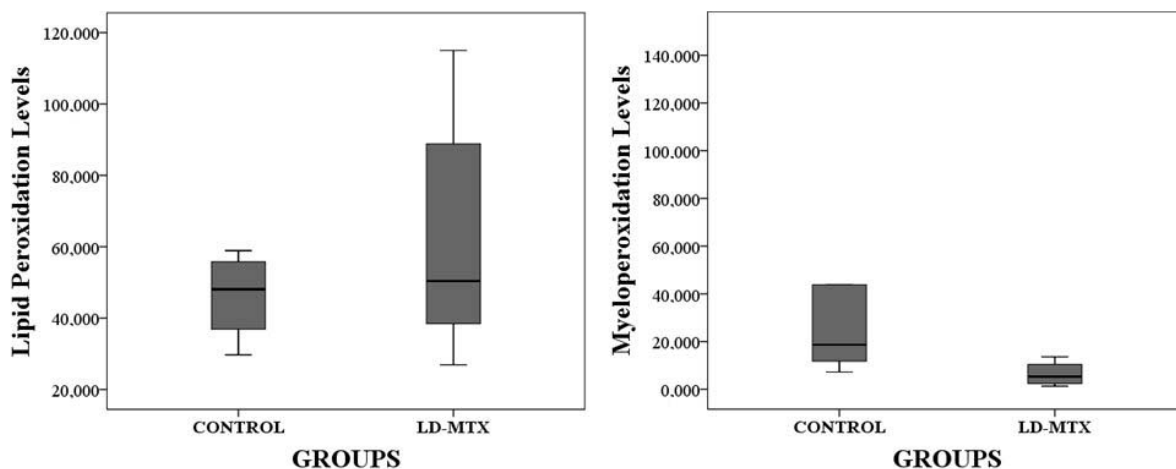


Figure 5. The main values of the lipid peroxidation and myeloperoxidase level of the LD-MTX group compared to the control group. Each error bar shows the minimum and maximum values of lipid peroxidation and myeloperoxidase level.

administered intraperitoneally to the control group in our study. Therefore, the effect of the stress hormones could not be eliminated in our study.

In conclusion, although LD-MTX could increase the vascularization of transplanted fat tissue and decrease the

MPO levels, it could not adequately protect the fat graft from resorption. However, further detailed studies in larger animal groups could be done in the future.

References

1. Coleman SR. Structural fat grafts: the ideal filler? *Clin Plast Surg* 2001; 28: 111-119.
2. Coleman SR. Structural fat grafting: more than a permanent filler. *Plast Reconstr Surg* 2006; 118 (Suppl. 3): 108S-120S.
3. Bishop A, Hong P, Bezuhly M. Autologous fat grafting for the treatment of velopharyngeal insufficiency: state of the art. *J Plast Reconstr Aesthet Surg* 2014; 67: 1-8.
4. Liao HT, Marra K, Rubin PJ. Application of platelet-rich plasma and platelet-rich fibrin in fat grafting: basic science and literature review. *Tissue Eng Part B Rev* 2014; 20: 267-276.
5. Nishimura T, Hashimoto H, Nakanishi I, Furukama M. Microvascular angiogenesis and apoptosis in the survival of free fat grafts. *Laryngoscope* 2000; 110: 1333-1338.
6. Topcu A, Aydin OE, Ünlü M, Barutcu A, Atabey A. Increasing the viability of fat grafts by vascular endothelial growth factor. *Arch Facial Plast Surg*. 2012; 14: 270-276.
7. Rodríguez-Flores J, Palomar-Gallego MA, Enguita-Valls AB, Rodríguez-Peralto JL, Torres J. Influence of platelet-rich plasma on the histologic characteristics of the autologous fat graft to the upper lip of rabbits. *Aesthetic Plast Surg*. 2011; 35: 480-486.
8. Yang M, Zhang F, Sailes FC, Zhang EW, Lin S, Das SK. Role of anti-TNF- α therapy in fat graft preservation. *Ann Plast Surg*. 2012; 68: 531-535.
9. Cronstein BN, Naime D, Ostad E. The antiinflammatory mechanism of methotrexate. Increased adenosine release at inflamed sites diminishes leukocyte accumulation in an in vivo model of inflammation. *J Clin Invest* 1993; 92: 2675-2682.
10. Imamura M, Hashino S, Kobayashi H, Kubayashi S, Hirano S, Minagawa T, Tanaka J, Fujii Y, Kobayashi M, Kasai M et al. Serum cytokine levels in bone marrow transplantation: synergistic interaction of interleukin-6, interferon- γ , and tumor necrosis factor- α in graft-versus-host disease. *Bone Marrow Transplant* 1994; 13: 745-751.
11. Montesinos MC, Takedachi M, Thompson LF, Wilder TF, Fernández P, Cronstein BN. The antiinflammatory mechanism of methotrexate depends on extracellular conversion of adenine nucleotides to adenosine by ecto-5'-nucleotidase: findings in a study of ecto-5'-nucleotidase gene-deficient mice. *Arthritis Rheum* 2007; 56: 1440-1445.
12. Mihara M, Uchiyama M. Determination of malonaldehyde precursor in tissues by thiobarbituric acid test. *Anal Biochem* 1977; 86: 271-278.
13. Suzuki K, Ota H, Sasagawa S, Sakatani T, Fujikura T. Assay method for myeloperoxidase in human polymorphonuclear leucocytes. *Anal Biochem* 1982; 127: 346-350.
14. Katchamart W, Trudeau J, Phumethum V, Bombardier C. Efficacy and toxicity of methotrexate (MTX) monotherapy versus MTX combination therapy with non-biological disease-modifying antirheumatic drugs in rheumatoid arthritis: a systematic review and meta-analysis. *Ann Rheum Dis* 2009; 68: 1105-1112.
15. Chan ES, Cronstein BN. Molecular action of methotrexate in inflammatory diseases. *Arthritis Res* 2002; 4: 266-273.

16. Storb R, Deeg HJ, Whitehead J, Appelbaum F, Beatty P, Bensinger W, Buckner CD, Clift R, Doney K, Farewell V. Methotrexate and cyclosporine compared with cyclosporine alone for prophylaxis of acute graft versus host disease after marrow transplantation for leukemia. *N Engl J Med* 1986; 314: 729-735.
17. Nguyen A, Pasyk KA, Bouvier TN, Hassett CA, Argenta LC. Comparative study of survival of autologous adipose tissue taken and transplanted by different techniques. *Plast Reconstr Surg* 1990; 85: 378-386.
18. Billings E, May JW Jr. Historical review and present status of free fat graft autotransplantation in plastic and reconstructive surgery. *Plast Reconstr Surg*. 1989; 83: 368-381.
19. Nishimura T, Hashimoto H, Nakanishi I, Furukawa M. Microvascular angiogenesis and apoptosis in the survival of free fat grafts. *Laryngoscope* 2000; 110: 1333-1338.
20. Bartynski J, Marion M, Wang T. Histopathologic evaluation of adipose autografts in a rabbit ear model. *Otolaryngol Head Neck Surg* 1990; 102: 314-321.
21. Kanner J, German JB, Kinsella JE. Initiation of lipid peroxidation in biological systems. *Crit Rev Food Sci Nutr*. 1987; 25: 317-364.
22. Farber JL. Mechanisms of cell injury by activated oxygen species. *Environ Health Perspect* 1994; 102 (Suppl. 10): 17-24.
23. Bakar B, Köse EA, Kupana Ayva S, Sarkarati B, Kasımcı MO, Kılınc K. Effects of low-dose methotrexate in spinal cord injury in rats. *Ulus Travma Acil Cerrahi Derg* 2013; 19: 285-293.
24. Sanlı AM, Serbes G, Sargon MF, Caliřkan M, Kilińç K, Bulut H, Sekerci Z. Methotrexate attenuates early neutrophil infiltration and the associated lipid peroxidation in the injured spinal cord but does not induce neurotoxicity in the uninjured spinal cord in rats. *Acta Neurochir (Wien)* 2012;154: 1045-1054.
25. Eto H, Suga H, Matsumoto D, Inoue D, Aoi N, Kato H, Araki J, Yoshimure K. Characterization of structure and cellular components of aspirated and excised adipose tissue. *Plast Reconstr Surg*. 2009;124: 1087-1097.