

Efficacy of mitomycin-C and infliximab in reducing adhesion and fibrosis following strabismus surgery*

Emin Serbüent GÜÇLÜ¹, Ayşe Ayça SARI², Erdem DİNÇ^{2,**}, Tuba ÖZCAN METİN³, Banu ÇOŞKUN YILMAZ³, Bahar TAŞDELEN⁴

¹Eye Clinic, Ersin Arslan State Hospital, Gaziantep, Turkey

²Department of Ophthalmology, Faculty of Medicine, Mersin University, Mersin, Turkey

³Department of Histology and Embryology, Faculty of Medicine, Mersin University, Mersin, Turkey

⁴Department of Biostatistics, Faculty of Medicine, Mersin University, Mersin, Turkey

Received: 10.06.2015 • Accepted/Published Online: 02.01.2016 • Final Version: 17.11.2016

Background/aim: The present study aimed to investigate the efficacy of mitomycin-C (MMC) and infliximab (INF) in reducing adhesion and fibrosis following strabismus surgery.

Materials and methods: Forty eyes of 20 albino rabbits were separated into MMC and INF groups. Right and left eyes of rabbits were assigned to the drug and control groups, respectively. The superior rectus muscle was disinserted, the drug was administered to the surgical area for 5 min in the drug eyes (MMC 0.2 mg/mL or INF 5 mg/mL), and physiological saline was administered to the control eyes. Surgical areas were rinsed with 10 mL of physiological saline. The disinserted muscle was then sutured to the same area using 6.0 Vicryl. The rabbits were sacrificed after 4 weeks for histopathological examination.

Results: Significant reduction was observed in fibrosis in the INF group as compared to the control group ($P = 0.005$). Although adhesion formation in the drug eyes reduced in the MMC and INF groups as compared to the control group, the difference was not significant ($P = 0.280$ and $P = 0.579$, respectively).

Conclusion: This study demonstrated the fibrosis-preventing efficacy of IFN; thus, it can be a good option in reducing fibrosis in strabismus surgery.

Key words: Strabismus surgery, adhesion, fibrosis, infliximab, mitomycin-C

1. Introduction

Adhesion, fibrosis, and scarring formation following strabismus surgery are among the most important problems that unfavorably influence surgical success. The exact incidence of scars, adhesion, and fibrosis has not been reported but Ludwig retrospectively reviewed 134 reoperations in which a stretched scar was discovered and estimated that stretched scar tissue was a contributing factor in 10% of all strabismus reoperations and 50% of late overcorrections (1). Adhesion is the attachment that occurs in some tissues including the conjunctiva, Tenon's capsule, the intermuscular membrane, orbital adipose tissue, the sclera, and extraocular muscular tissue due to any reason during or after strabismus surgery. These adhesions may result from inappropriate surgical approach, excessive bleeding, cautery usage, suture reaction, postoperative infection, muscular capsule injury, migration of adipose

tissue to the surgical area due to the laceration of the orbital septum, and multiple procedures performed in the same region (2). Fibrosis is the contracture occurring after inflammation of extraocular muscles. Appropriate surgical techniques should be performed to avoid postoperative adhesion and fibrosis and subsequent scarring (2,3).

Adhesion, fibrosis, and scar formation after strabismus surgery bring along unfavorable consequences for both the patient and the surgeon. Need for a second surgery not only psychologically influences the patient negatively but also leads to further tissue injury during the second intervention and causes additional expense. Reducing adhesion, fibrosis, and scarring after strabismus surgery would provide results that are more satisfactory for both patients and surgeons by enhancing anatomical success. For this purpose, many materials and drugs have been studied in experimental or clinical trials; nevertheless, no

* This study was presented at the 2nd World Congress of Pediatric Ophthalmology and Strabismus, Milan, 2012.

** Correspondence: erdem_dinc@hotmail.com

method has yet become popular enough (4). The aim of the present study is histopathological investigation of effects of two well-known antiinflammatory agents, mitomycin-C (MMC) and infliximab (INF), on fibrosis, adhesion, and scar formation in the surgical area in the eyes of rabbits that underwent experimental strabismus surgery.

2. Materials and methods

After obtaining the approval of the Mersin University Faculty of Medicine Ethics Committee for animal experiment, all animals used in the study received humane care in compliance with the guidelines established by the committee, and all experiments were conducted in accordance with the Animal Care and Use Committee and the ARVO statement for the use of animals in ophthalmic and vision research. A prospective observer-masked controlled study was performed on 40 eyes of 20 New Zealand albino rabbits (weighing 3 to 5 kg). The rabbits were randomized and separated into 2 groups as MMC (n = 10) and INF (n = 10) groups. In each group, the right eyes of the rabbits were assigned to the drug group and the left eyes were assigned to the control group.

Before the surgical procedure was carried out anesthesia was administered with 50 mg/kg ketamine hydrochloride (Ketalar, Eczacıbaşı, İstanbul, Turkey) and 3.5 mg/kg xylazine hydrochloride (Rompun, Bayer, İstanbul, Turkey). After the skin was cleaned with povidone-iodine following the anesthesia, a lid speculum was placed and 5% diluted povidone-iodine was dropped into the eyes with a waiting period of 3 min. Thereafter, the eyes were rinsed with physiological saline and made ready for strabismus surgery. In all eyes, the conjunctiva was opened through the limbal route. As it is easy to isolate, the superior rectus muscle was preferred and exposed with the help of a muscle hook. The superior rectus muscle was secured with 6.0 Vicryl sutures as is done in standard strabismus surgery and separated from its insertion. The drugs (0.2 mg/mL in the MMC group and 5 mg/mL in the INF group) were soaked into triangular sponges and were administered for 5 min under the insertion place of the superior rectus muscle of the right eyes of rabbits. At the end of this period, the wound site was rinsed with 10 mL of physiological saline and the muscle was sutured to its original insertion site. The conjunctiva was closed using two 6.0 Vicryl sutures and the surgery was completed. The left eyes of the rabbits were considered as the control group and a physiological saline-soaked sponge was administered for 5 min after the disinsertion of the muscle to the insertion site. Subsequently, a rinsing procedure was performed using 10 mL of physiological saline, the muscle was sutured, and the surgery was completed.

Topical gentamycin sulfate (Genta 0.3% eye drops, İ.E. Ulagay, İstanbul, Turkey) was postoperatively administered

in all eyes at a dose of one drop three times daily for 1 week. The eyes were examined in terms of infection and other likely complications every 2 days in the first week and every week thereafter. No suture detachment or infection was observed in any of the eyes during the follow-up period. Four weeks later, the rabbits were sacrificed for histopathological examination using intravenous sodium pentothal and the eyes were enucleated via a dissection made through the bulbus providing that the conjunctiva-muscle-sclera attachment place in the superior aspect not be damaged. Statistical analyses were performed using SPSS 17.0 for Windows (SPSS Inc., Chicago, IL, USA). Comparison of the groups was performed by Mann-Whitney U test. $P < 0.05$ was considered statistically significant.

2.1. Histologic tissue processing

The removed tissues were fixed in a 10% formaldehyde solution for 24–48 h. These tissues were then washed under running water for 2 h and passed through a series of increasing alcohol concentrations for dehydration. Xylol was used to make the tissues pellucid and the tissues were kept in the mixture of paraffin and xylol and then embedded into paraffin. Ten sections, each of which was 5 μ m in thickness, were obtained at equal intervals from each paraffin block using a microtome including the muscle-sclera junction area. The sections were stained with Masson's trichrome to evaluate muscular adhesion and fibrosis. Stained sections were examined and digital images were obtained using a Nikon Coolpix 5000 digital camera (Nikon Corp., Tokyo, Japan) attached to an Olympus BX50 light microscope (Olympus GmbH, Hamburg, Germany). All tissue samples were evaluated by the same histologist, who was blinded to the groups.

2.2. Histopathologic evaluation

The assessment of both adhesion and fibrosis was done based on previous studies (5). Assessment of adhesion was performed as follows: 0 - no adhesion; 1 - weak adhesion that could be easily detached by dissection (muscle and sclera adhesion is minimum); 2 - moderate adhesion (muscle and sclera adhesion is moderate); 3 - strong adhesion (it is difficult or impossible to detach by dissection; muscle and sclera appear as a whole).

Assessment of fibrosis was performed as follows: 0 - no fibrosis; 1 - moderate perimuscular fibrotic reaction; 2 - thick collagen bands that could be easily determined; 3 - well-developed massive collagen bands; 4 - serious fibrotic response that fills large areas.

3. Results

In the present study, the drug-administered eyes were compared with their corresponding control eyes in either the MMC or the INF group. The drugs were experimentally evaluated in terms of adhesion between

the muscle and sclera and muscular fibrosis in the surgical area of the superior rectus muscle. There was a significant decrease between the INF and control groups in terms of fibrosis formation ($P = 0.005$). There was also a decrease in adhesion formation after administering INF and MMC to the surgical area between their control groups, but the decreases were not significant. All results are listed in the Table.

Histopathological findings for fibrosis and adhesion areas after strabismus surgery are demonstrated in Figures 1A–1C.

4. Discussion

Today, none of the materials and drugs currently used to reduce adhesion, fibrosis, and related scarring following strabismus surgery are convenient enough. Therefore, new agents that are easily available and applicable, are more specific and effective in reducing adhesion and fibrosis formation, and have minimum or no systemic and local adverse events are needed.

The idea of reducing adhesion and fibrosis following strabismus surgery began in the late 1960s. For the first time in 1967, Dunlap (6) propounded the use of plastic

implants in extraocular muscle surgery. This idea was developed in subsequent years and different materials were tried. The initially used materials were Supramid sheaths and silicone sheaths (7). These materials were not absorbable and studies determined that they had insufficient efficacy and caused complications such as redness and infection in the eye and prolapse from the wound site due to foreign body reaction; thus, their usage was discontinued. After that, researchers tried absorbable mechanical barriers. For this purpose, polydioxanone, polytetrafluoroethylene, Sefrafilm, polyglactin 910 sheath, SurgiWrap, and sodium hyaluronate and hydroxypropyl methylcellulose among viscoelastic materials have been used (8–14). Complications such as foreign body reaction and infection have been encountered minimally with these materials; however, their efficacy against adhesion formation was found to be inadequate. In an experimental study, De Carvalho et al. (15) demonstrated that triamcinolone administered during surgery significantly reduced postoperative inflammation and prevented fibrosis and scar formation; however, they encountered complications such as increased intraocular pressure and cataracts in particular. Choi et al. (4) conducted a study

Table. Adhesion and fibrosis in the study groups.

	Mitomycin-C group		P	Infliximab group		P
	Drug eye (n = 10)	Control eye (n = 10)		Drug eye (n = 10)	Control eye (n = 10)	
Fibrosis score	2.9 (2.2–3.6)	2.9 (2.3–3.5)	0.853	1.7 (1.3–2.1)	3.0 (2.4–3.6)	0.005
Adhesion score	1.8 (1.3–2.3)	2.1 (1.6–2.6)	0.280	2.0 (1.5–2.5)	2.2 (1.6–2.8)	0.579

Data are expressed as median (minimum–maximum); comparison of the groups was performed by Mann–Whitney U test.

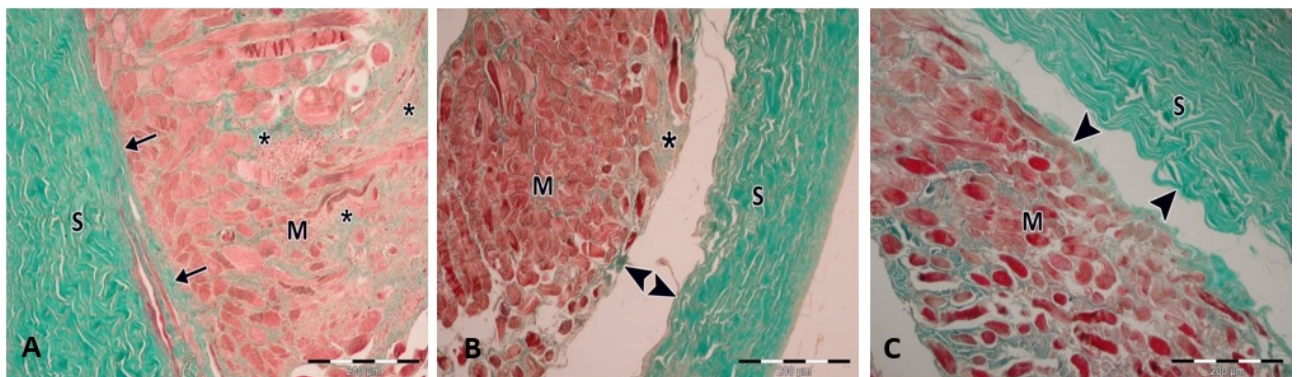


Figure 1. A) There is a significant amount of adhesion and fibrosis in the control eye. Sclera (S), muscle (M), adhesion (arrows), fibrosis (*). Masson's trichrome, 300×. B) There is no significant decrease in either fibrosis or adhesion formation in the MMC group. Sclera (S), muscle (M), area between muscle and sclera (arrow heads). Masson's trichrome, 300×. C) There is a significant decrease of fibrosis formation and no significant decrease in adhesion formation in the INF group. Sclera (S), muscle (M), area between muscle and sclera (arrow heads), fibrosis (*). Masson's trichrome, 300×.

using bevacizumab, an antivascular endothelial growth factor agent, and determined a decrease in inflammatory cells in the early postoperative period; however, bevacizumab was not found to be effective in preventing adhesion formation. Amniotic membrane is one of the most frequently studied materials in reducing adhesion, fibrosis, and scar formation after strabismus surgery. It has an enhancing effect on epithelization and prevents inflammation, scarring, fibrosis, and neovascularization. Because of its weak immunity and good harmony with the surrounding tissues, amniotic membrane has been used in many clinical studies and reported in case reports (16,17).

The use of some of these materials has been limited because they are prone to infection and unpractical. Some of these materials were used to benefit directly from their mass effects, whereas some were used for their antifibrotic effect in scar prevention. MMC and 5-fluorouracil (5-FU) are the most commonly studied agents in reducing adhesion formation (18,19).

MMC is a drug with a wide anticancer spectrum and has been prepared to be used via the intravenous route. MMC is known to be effective against gastrointestinal system cancers, bladder cancer, lung cancer, uterus cancer, head and neck cancer, and chronic leukemias. It is frequently used in ophthalmology to prevent haze formation in corneal refractive surgery and to reduce recurrence in pterygium surgery (20), in glaucoma surgery (18,21), for malignant tumors of conjunctiva (22), for corneal neoplasms (22), and to prevent closure of osteotomy areas and to reduce relapses in nasolacrimal canal surgeries (23). In many studies, it was used to reduce fibrosis and adhesion formation following strabismus surgery owing to its antiinflammatory, antiangiogenic, and antiscarring properties (19,24–28). In a study by Kersey and Vivian (28), conducted with two patients with restrictive strabismus undergoing multiple surgeries, they reported a decrease in adhesion and fibrosis with the use of amniotic membrane in combination with MMC. Chen et al. (27) reported a study comprising 14 cases of restrictive strabismus; they found standard-dose (0.2 mg/mL) MMC administration to be successful in reducing adhesion and reported no complications. Eşme et al. (19) carried out a study in an animal model and determined significant decrease in postoperative adhesion formation with both MMC and 5-FU, being higher with MMC. Cruz and Matkovich (25) conducted an animal study and reported that topical MMC was successful in reducing postoperative adhesion.

There are studies reporting that MMC is ineffective on fibrosis formation (29,30). Brooks et al. (30) performed an animal study, determined an increase in postoperative fibrosis formation in rabbits receiving MMC at a dose of 0.5 mg/mL, and attributed this increase to the difference

in the behaviors of episcleral fibroblasts. Demirel et al. (17) reported an experimental study and found that MMC significantly reduced adhesion formation as compared to the control group. In that particular study, although MMC was found to be successful also in reducing fibrosis formation as compared to the control group, this difference was not statistically significant. That particular study was conducted by deep sclerotomy technique to increase surgery-related adhesion and fibrosis. In the present study, we considered it unnecessary to increase adhesion and fibrosis because the materials compared were those aimed to be used in strabismus patients in standard surgeries. Minguini et al. (29) conducted an animal study and reported that 0.4 mg/mL MMC administered during surgery did not reduce adhesion; however, fibrosis formation was increased. In the present study, we observed that MMC reduced adhesion formation after an experimental model of strabismus surgery as compared to the control group. However, this decrease was not significant. There was no significant difference between the MMC and control groups in terms of fibrosis formation.

Infliximab is a tumor necrosis factor (TNF)-alpha inhibitor. TNF-alpha is a cytokine synthesized by macrophages and stimulates collagen biosynthesis, prostaglandin secretion, fibroblast activity, and angiogenesis. INF has antifibroblastic and antiangiogenic effects. INF is a water-soluble, human-murine monoclonal antibody. Inhibition of TNF-alpha, which is known to be a premodulator for wound healing, causes delay in wound healing (31). INF is used as an alternative to steroids in Behçet's disease, psoriasis, sarcoidosis, seronegative spondylarthropathies, and persistent childhood uveitis and in the treatment of systemic and ocular symptoms in juvenile idiopathic arthritis (32–38). INF was considered beneficial in the treatment of xerophthalmia symptoms secondary to inflammation and ocular symptoms of thyroid orbitopathy (36–38). INF has lower systemic and ocular adverse event profile as compared to other antifibroblastic agents such as 5-FU and MMC (31). Ferrair et al. (39) used topical INF at 10 mg/mL in an experimental ocular surface scarring model and found that topical INF is safe, nontoxic, and effective in decreasing inflammation and fibrosis.

Uçar et al. (31) used INF in filtering glaucoma surgery and investigated its effects on fibroblastic activities in conjunctiva and Tenon's tissues. At the end of the study, they observed that fibroblastic activity of Tenon's tissue and conjunctiva was dose- and time-dependently decreased by topical INF administration (i.e. application of an INF-impregnated sponge to the surgical area); no decrease occurred in fibroblastic activity with subconjunctival administration. In the present study, INF was administered via sponge at a dose of 5 mg/mL for 5

min under the extraocular muscle in the surgical area. No ocular or systemic adverse event was encountered at the administered dose. There was a decrease in adhesion formation after administering INF to the surgical area as compared to the control group, although the difference was not significant. However, this decrease in adhesion was not as large as that obtained with MMC. Fibrosis formation in the INF group was lower than that in both the MMC and control groups.

Fibrosis-preventing efficacy of INF was found significant in the present study. The properties of INF, a TNF-alpha blocker, including antifibroblastic effect, low systemic and ocular adverse event profile, specific efficacy to the target area, and being easily applicable, suggest that it may be a good option in reducing adhesion and fibrosis in strabismus surgery. Nevertheless, we think

that ocular toxic effects should still be investigated with more advanced evaluations as there are not many studies regarding this molecule. The high cost of the drug and difficulty in availability are its disadvantages.

In conclusion, for extensive use of INF in strabismus surgery, electron microscopic studies together with immunostaining for fibrosis and inflammation evaluation on larger numbers of animals particularly in terms of toxicity and potential ocular adverse events are required and these studies should subsequently be supported by clinical trials.

Acknowledgment

This study was supported by the Mersin University Scientific Research Fund (Grant No: BAP-TF CTB (ESG) 2011-5 TU).

References

- Ludwig IH. Scar remodeling after strabismus surgery. *Trans Am Ophthalmol Soc* 1999; 97: 583-651.
- Dunlap EA. Surgery of muscle adhesions and effects of multiple operations. *Br J Ophthalmol* 1974; 58: 307-312.
- Simon JW. Complications of strabismus surgery. *Curr Opin Ophthalmol* 2010; 21: 361-366.
- Choi HY, Lee JH, Lee JE, Jung JH. Effect of bevacizumab on strabismus surgery in rabbits. *Invest Ophthalmol Vis Sci* 2010; 51: 4585-4588.
- Ryu WY, Jung HM, Roh MS, Kwon YH, Jeung WJ, Park WC, Rho SH, Ahn B. The effect of a temperature-sensitive poloxamer-alginate-CaCl₂ mixture after strabismus surgery in a rabbit model. *J AAPOS* 2013; 17: 484-489.
- Dunlap EA. Plastic implants in muscle surgery: a study of the possible use of plastic materials in the management of extraocular motility restrictions. *Trans Am Ophthalmol Soc* 1967; 65: 393-470.
- Sondhi N, Ellis FD, Hamed LM, Helveston HM. Evaluation of an absorbable muscle sleeve to limit postoperative adhesions in strabismus surgery. *Ophthalmic Surg* 1987; 18: 441-443.
- Sondhi N, Koseoglu ST, Bonnin JM, Fahad B. Polydiaxonon prevents adhesions in the rabbit model: a pilot report. *J AAPOS* 1998; 2: 214-217.
- Hwang JM, Chang BL. Delayed reattachment of extraocular muscles in rabbits using thin polytetrafluoroethylene. *Ophthalmic Surg Lasers* 1997; 28: 59-64.
- Ozkan SB, Kir E, Culhaci N, Dayanir V. The effect of Seprafilm on adhesions in strabismus surgery-an experimental study. *J AAPOS* 2004; 8: 46-49.
- Hwang JM, Chang BL. Use of physical barriers for delayed adjustable strabismus surgery: the effect of Interceed and polyglactin 910 mesh. *Br J Ophthalmol* 1996; 80: 759-762.
- Choung HK, Hwang JM. The use of Surgi Wrap in delayed adjustable strabismus surgery. *Am J Ophthalmol* 2005; 140: 433-436.
- Fulga V, Koren R, Ezov N, Gal R, Nimrod A, Savir H. Sodium hyaluronate as a tool in strabismus surgery in rabbits. *Ophthalmic Surg Lasers* 1996; 27: 228-233.
- Ferreira RC, Lamberts M, Moreira JB, Campos MS. Hydroxypropylmethylcellulose and sodium hyaluronate in adjustable strabismus surgery. *J Pediatr Ophthalmol Strabismus* 1995; 32: 239-242.
- de Carvalho LE, Alves MR, da Silva MA, Gaal Vadas MF. Experimental strabismus surgery using triamcinolone: outcomes and effects on inflammatory response. *Arq Bras Oftalmol* 2007; 70: 209-215.
- Strube YN, Conte F, Faria C, Yiu S, Wright KW. Amniotic membrane transplantation for restrictive strabismus. *Ophthalmology* 2011; 118: 1175-1179.
- Demirel S, Atilla H, Okcu Heper A, Erkam N. Effects of amniotic membrane on wound healing and adhesions in experimental strabismus surgery. *Eur J Ophthalmol* 2009; 19: 899-904.
- Lama PJ, Fechtner RD. Antifibrotics and wound healing in glaucoma surgery. *Surv Ophthalmol* 2003; 48: 314-346.
- Eşme A, Yildirim C, Tatlipinar S, Düzcan E, Yaylali V, Ozden S. Effects of intraoperative sponge mitomycin C and 5-fluorouracil on scar formation following strabismus surgery in rabbits. *Strabismus* 2004; 12: 141-148.
- Abraham LM, Selva D, Casson R, Leibovitch I. Mitomycin: clinical applications in ophthalmic practice. *Drugs* 2006; 66: 321-340.
- Onol M, Aktaş Z, Hasanreisoglu B. Enhancement of the success rate in trabeculectomy: large-area mitomycin-C application. *Clin Experiment Ophthalmol* 2008; 36: 316-322.

22. Dudley BW, Malecha MA. Limbal stem cell deficiency following topical mitomycin C treatment of conjunctival-corneal intraepithelial neoplasia. *Am J Ophthalmol* 2004; 137: 950-951.
23. Yildirim C, Yaylali V, Esmé A, Özden S. Long-term results of adjunctive use of mitomycin C in external dacryocystorhinostomy. *Int Ophthalmol* 2007; 27: 31-35.
24. Urban RC Jr, Kaufman LM. Mitomycin in the treatment of hypertrophic conjunctival scars after strabismus surgery. *J Pediatr Ophthalmol Strabismus* 1994; 31: 96-98.
25. Cruz OA, Matkovich L. Effects of intraoperative topical mitomycin-C on strabismus surgery in the rabbit: a preliminary study. *Ophthalmic Surg* 1995; 26: 237-240.
26. Cruz OA. Evaluation of mitomycin to limit postoperative adhesions in strabismus surgery. *J Pediatr Ophthalmol Strabismus* 1996; 33: 89-92.
27. Chen PL, Chen WY, Lu DW. Evaluation of mitomycin C in reducing postoperative adhesions in strabismus surgery. *J Ocul Pharmacol Ther* 2005; 21: 406-410.
28. Kersey JP, Vivian AJ. Mitomycin and amniotic membrane: a new method of reducing adhesions and fibrosis in strabismus surgery. *Strabismus* 2008; 16: 116-118.
29. Minguini N, Monteiro de Carvalho KM, Akaishi PM, De Luca IM. Histologic effect of mitomycin C on strabismus surgery in the rabbit. *Invest Ophthalmol Vis Sci* 2000; 41: 3399-3401.
30. Brooks SE, Ribeiro GB, Archer SM, Elner VM, Del Monte MA. Fat adherence syndrome treated with intraoperative mitomycin-C: a rabbit model. *J Pediatr Ophthalmol Strabismus* 1996; 33: 21-27.
31. Uçar D, Ocakoğlu Ö, Solakoğlu S. Histological evaluation of local TNF alpha inhibition on conjunctiva and tenon fibroblastic activity in surgical wound healing of rabbit eyes (experimental prestudy). *Turk J Ophthalmol* 2009; 39: 197-204 (in Turkish with English abstract).
32. Takamoto M, Kaburaki T, Numaga J, Fujino Y, Kawashima H. Long-term infliximab treatment for Behçet's disease. *Jpn J Ophthalmol* 2007; 51: 239-240.
33. Suhler EB, Smith JR, Wertheim MS, Lauer AK, Kurz DE, Pickard TD, Rosenbaum JT. A prospective trial of infliximab therapy for refractory uveitis: preliminary safety and efficacy outcomes. *Arch Ophthalmol* 2005; 123: 903-912.
34. Ali A, Samson CM. Seronegative spondyloarthropathies and the eye. *Curr Opin Ophthalmol* 2007; 18: 476-480.
35. Mange H, Heinzl B, Grubbauer HM, El-Shabrawi Y, Schauenstein K. Therapeutic experience with infliximab in a patient with polyarticular juvenile idiopathic arthritis and uveitis. *Rheumatol Int* 2003; 23: 258-261.
36. Cordero-Coma M, Anzaar F, Sobrin L, Foster CS. Systemic immunomodulatory therapy in severe dry eye secondary to inflammation. *Ocul Immunol Inflamm* 2007; 15: 99-104.
37. Durrani OM, Reuser TQ, Murray PI. Infliximab: a novel treatment for sight-threatening thyroid associated ophthalmopathy. *Orbit* 2005; 24: 117-119.
38. Li Z, Choi W, Oh HJ, Yoon KC. Effectiveness of topical infliximab in a mouse model of experimental dry eye. *Cornea* 2012; 31: 25-31.
39. Ferrari G, Bignami F, Giacomini C, Franchini S, Rama P. Safety and efficacy of topical infliximab in a mouse model of ocular surface scarring. *Invest Ophthalmol Vis Sci* 2013; 54: 1680-1688.