

Superiorly based nasolabial island flap for reconstruction of the lateral lower eyelid

Sedat TATAR^{1*}, Yalçın YONTAR¹, Selahattin ÖZMEN²

¹Department of Plastic, Reconstructive, and Aesthetic Surgery, Kayseri Training and Research Hospital, Kayseri, Turkey

²Department of Plastic, Reconstructive, and Aesthetic Surgery, Faculty of Medicine, Koç University, İstanbul, Turkey

Received: 26.01.2017 • Accepted/Published Online: 16.05.2017 • Final Version: 19.12.2017

Background/aim: Various flap procedures have been described and used for the lower eyelids; however, the nasolabial flap is rarely employed. We herein aimed to present the clinical results of using the superiorly based nasolabial island flap for repair of surgical defects extending to the lateral lower eyelid.

Materials and methods: Nine patients with a mean age of 62 ± 6 years underwent surgery for reconstruction of the lower eyelid.

Results: The diagnosis of lesions was nodular basal-cell carcinoma (n = 5), superficial basal-cell carcinoma (n = 1), well-differentiated squamous-cell carcinoma (n = 1), and basosquamous-cell carcinoma (n = 2). According to the classification reported by Spinelli and Jelks, 6 surgical defects were located at zones II and IV, while 3 were at zones II and V. Five patients required posterior lamellar reconstruction. Lagophthalmos (n = 1), ectropion (n = 1), and transient numbness of the ipsilateral upper lip (n = 1) were noted as postoperative complications.

Conclusion: Despite the low number of patients, the present series demonstrated that lower eyelid defects involving zone IV or zone V can be repaired safely and reliably with the superiorly based nasolabial island flap, along with its use shown in the literature for zone II or zone III defects. The technique for raising the flap is fairly simple, with predictable surgical results. In addition, the superiorly based nasolabial island flap provides a reliable means of obtaining good wound healing with acceptable aesthetics, as well as functional results of both the donor site and reconstructed area.

Key words: Nasolabial flap, island flap, subcutaneous pedicle, lower eyelid, eyelid reconstruction

1. Introduction

Reconstruction of the eyelids is a challenging task for plastic and reconstructive surgeons and is mostly performed due to trauma, tumor resection, or, less commonly, congenital abnormalities (e.g., coloboma, Tessier no. 3–6 clefts) (1,2). The decision as to the most appropriate reconstructive option depends on assessment of the eyelid defect in terms of its size, extent, orientation, and, most importantly, location. A method of classifying periocular defects according to location was developed by Spinelli and Jelks (3), in which the eyelid was divided into 5 zones: zone I, the upper eyelid; zone II, the lower eyelid; zone III, the medial canthal region; and zone IV, the lateral canthal region. Furthermore, any area outside zones I–IV but contiguous with the eyelids was described as zone V in this classification system (Figure 1).

Full-thickness defects up to 25% of the width of the lower eyelid can be repaired via direct closure. Lateral canthotomy and cantholysis can provide 25% additional horizontal length, leading to tissue advancement and

rotation to aid in closure of larger defects (1,3,4). When primary closure is not feasible, various flap alternatives developed with the aims of functional restoration and aesthetic improvement of the lower eyelid zones can be employed, such as the semicircle (Tenzel) flap (5), superiorly based tarsoconjunctival advancement (Hughes) flap (6), upper eyelid myocutaneous (Tripier) flap (7), transposed cheek (McGregor) flap (8), cheek rotation and advancement (Mustardé) flap (9), and supraorbital (Fricke) flap (10).

Nasolabial flap is rarely employed for the reconstruction of the lower eyelid. It is a random-pattern cutaneous flap with redundant blood supply from the perforating branches of the facial and angular arteries and can be used as an inferiorly or superiorly based flap (11,12). It has a wide spectrum of use for nasal and midfacial defects (13,14) and can be used as an island (15) or transposition flap (16–18) for the reconstruction of the lower eyelid.

In this study, we aimed to present the clinical results of using the superiorly based nasolabial island flap for repair

* Correspondence: sedattatarr@gmail.com

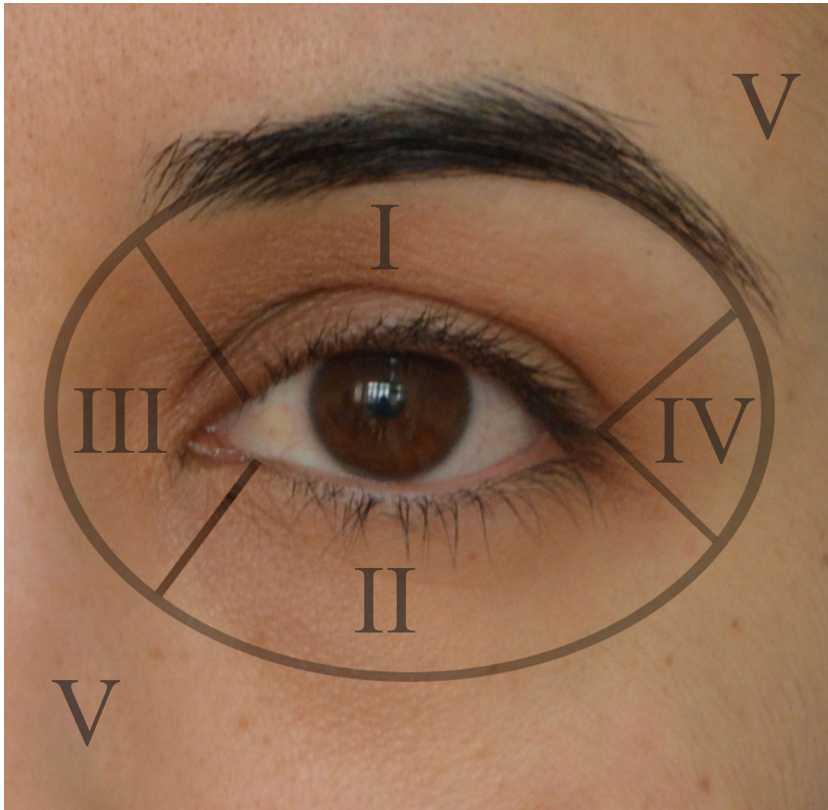


Figure 1. The surgical zones of the periocular region (3).

of surgical defects extending to the lateral aspect of the lower eyelid. As mentioned above, the use of nasolabial flaps in various forms for the reconstruction of the lower eyelids is not a novelty. However, despite the established use of the superiorly based nasolabial island flap for repair of zone II and zone III defects, its use for zone IV and zone V defects has not been described previously. The other aim of this paper is to describe the technique of the procedure, while showing that it is an acceptable alternative to other, better-known flap procedures.

2. Materials and methods

2.1. Study design

This study included a total of 9 consecutive patients who underwent surgery for the reconstruction of the lower eyelid following resection of cutaneous malignancies. In all patients, histopathological diagnosis was made initially by incisional biopsy and confirmed by the histopathological examination of the entire resected specimen after surgery.

All patients gave written informed consent prior to the surgery, and the study was approved by the Institutional Ethics Committee of Erciyes University.

2.2. Operative technique

All procedures were performed under local anesthesia with or without intravenous sedation. Following resection

of the cutaneous malignancy with adequate surgical margins, a template of the defect was fashioned using a suture foil paper and then transferred to the donor site on the ipsilateral nasolabial fold. The skin island of the flap was designed according to the shape and size of the template and located on the nasolabial fold according to the orientation and location of the defect.

The dissection of the flap was started caudally in the subcutaneous plane over the superficial musculo-aponeurotic system (SMAS) and carried towards the pivot point located at the medial canthal region on a subcutaneous pedicle, 1–1.5 cm in width. The dissection of the subcutaneous pedicle was continued until the flap was able to be transferred easily into the lower eyelid defect without tension.

The raised flap was then inset within the area of the defect through a subcutaneous tunnel of sufficient size over the SMAS. It was defatted, and the dermis of the caudal end of the flap was anchored to the lateral canthal tendon or periosteum of the Whitnall's tubercle with 5-0 polypropylene sutures for canthal support. After hemostasis was confirmed, a Penrose drain was placed into the donor site, and primary closure of the donor site and suturing of the flap were performed with 5-0 polydioxanone sutures in the usual fashion.

A composite nasal septal chondromucosal graft was used in patients with full-thickness defect of the lower eyelid following tumor resection. The graft was placed along the defect, and the mucosal layer of the graft was sutured to the remaining conjunctiva with interrupted 6-0 polyglactin 910 sutures. The caudal margin of the cartilage layer was anchored to the periosteum of the infraorbital rim with 5-0 polypropylene sutures. To align the lid margin, the cranial margin of the mucosal layer was sutured to the flap with interrupted 6-0 polyglactin 910 sutures. The donor site was then packed with a strip of Vaseline gauze, and a gentle pressure dressing was applied. In patients requiring tarsal reconstruction, a conchal cartilage graft was used. It was harvested from the ipsilateral ear via an incision at the anterior margin of the anthelix, and anchored to the orbital septum and periosteum of the infraorbital rim with 5-0 polypropylene sutures. Following primary closure of the anthelix incision, the auricle was packed with Vaseline-impregnated gauze, and a bandage was applied.

3. Results

Of the patients, 7 were males, and 2 were females with a mean age of 62 ± 6 (range: 52–70) years. The Table presents detailed characteristics of the patients.

The histopathological diagnosis of the lesions was a nodular basal-cell carcinoma in 5 patients, a superficial basal-cell carcinoma in 1, a well-differentiated squamous-cell carcinoma in 1, and a basosquamous-cell carcinoma in 2. The mean longitudinal diameter of the tumor and mean minimum histological margin were 1.63 ± 0.45 cm (range: 1–2.5 cm), and 6.22 ± 1.09 mm (range: 5–8 mm), respectively. None of the patients had tumor involvement at the radial margins of the resection. Malignant involvement

of the regional lymph nodes was not clinically or radiologically detected in any patients during preoperative and postoperative follow-ups.

According to the classification reported by Spinelli and Jelks (6), 6 surgical defects were located at zones II and IV and 3 at zones II and V. In addition, the flap size ranged from 2×2 cm to 3×3 cm. Of the patients we submitted to surgery, 3 required posterior lamellar reconstruction with a composite nasal septal chondromucosal graft, while 2 required tarsal reconstruction with a conchal cartilage graft.

The mean follow-up of the patients was 7.11 ± 1.05 (range: 6–9) months. Postoperative complications, including tumor recurrence, flap necrosis, wound dehiscence, wound infection, xerophthalmia, entropion, donor site morbidity, or graft failure, were not observed in any patients (Figures 2–4). However, one patient showed scleral show due to ineffective canthal support; the patient underwent re-do surgery at the postoperative sixth month. Another patient had scleral show, which did not prevent complete lid closure and did not require re-do surgery (Figure 2D), while another had transient numbness at the ipsilateral side of the upper lip, which spontaneously resolved within 6 weeks postoperatively.

4. Discussion

Reconstruction of the eyelids requires particular considerations and a comprehensive understanding of the specialized anatomy (3). The eyelids consist of 2 lamellae, and disruption of these anatomical structures due to trauma or tumor resection can result in impaired functioning with poor cosmesis. During the operative procedure, each lamella must be addressed to reconstruct a normal-

Table. Clinic and demographic properties of the patients.

	Age	Sex	Histopathologic diagnosis	Zones	Flap size (cm)	Graft	Anesthesia	Complication
Patient 1	65	M	BSCC	II and IV	2×3	CCG	LA + IVS	Scleral show
Patient 2	56	M	Nodular BCC	II and V	3×3	-	LA	-
Patient 3	52	M	BSCC	II and IV	2×2	SCMG	LA+IVS	-
Patient 4	57	F	Superficial BCC	II and IV	2×2.5	-	LA	-
Patient 5	69	M	Nodular BCC	II and IV	2.5×2.5	-	LA + IVS	-
Patient 6	70	M	Nodular BCC	II and V	2×3	-	LA	-
Patient 7	64	F	Well-differentiated SCC	II and IV	1.5×3	SCMG	LA + IVS	Scleral show (re-do surgery was performed at postoperative sixth month)
Patient 8	63	M	Nodular BCC	II and IV	2.5×3	SCMG	LA + IVS	-
Patient 9	62	M	Nodular BCC	II and V	2×3	CCG	LA + IVS	Transient numbness

M: male; F: female; BSCC: basosquamous cell carcinoma; BCC: basal cell carcinoma; SCC: squamous cell carcinoma; LA: local anesthesia; IVS: intravenous sedation; SCMG: septal chondromucosal graft; CCG: conchal cartilage graft.

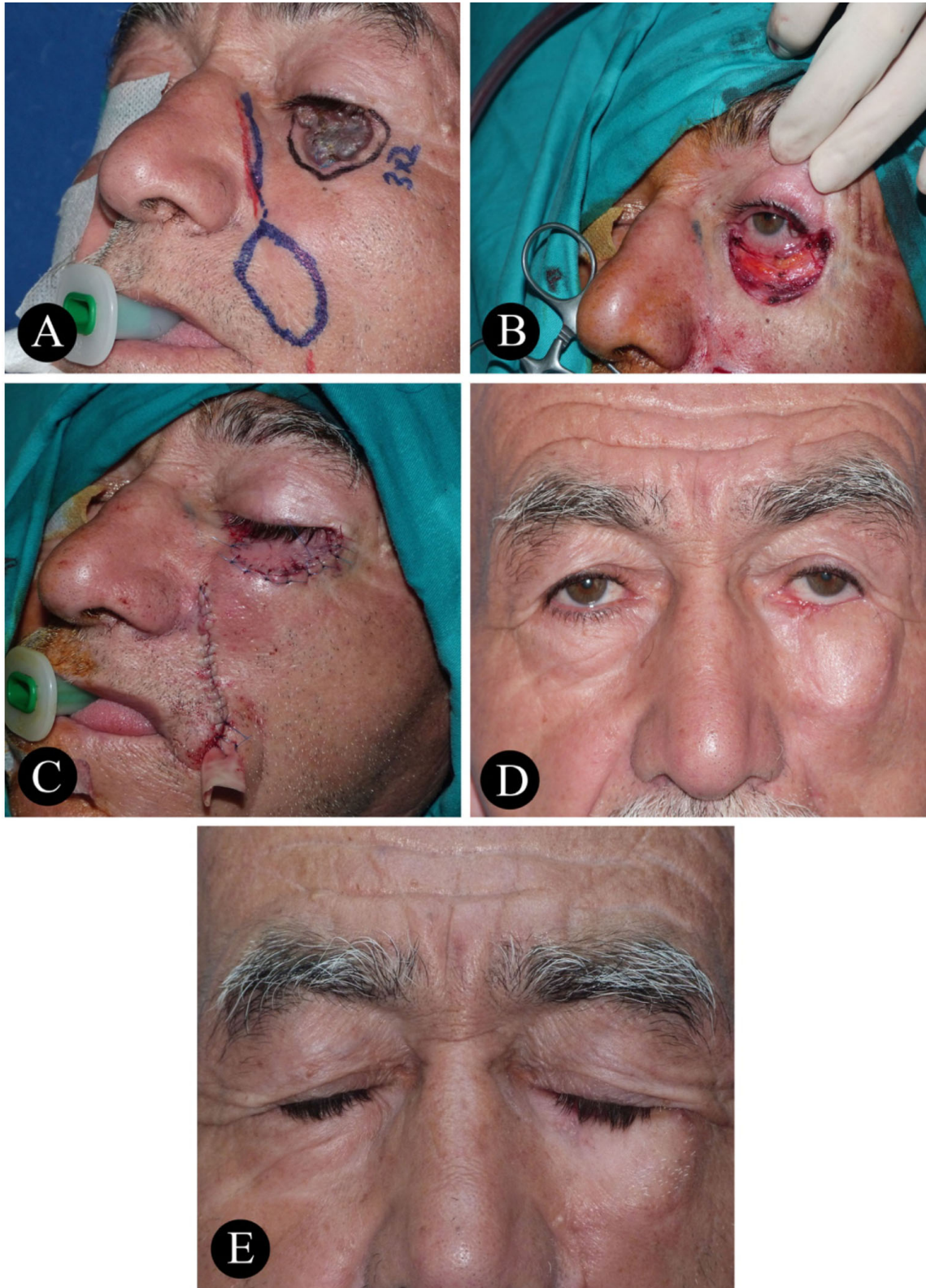

Figure 2. Patient 1. A. A 65-year-old male patient with left-sided basosquamous cell carcinoma; B. lower eyelid defect located at zones II and IV following resection of the cutaneous malignancy; C. immediate postoperative view; D and E. seventh postoperative month view of the patient with scleral show that does not prevent complete closure of the eyelids.

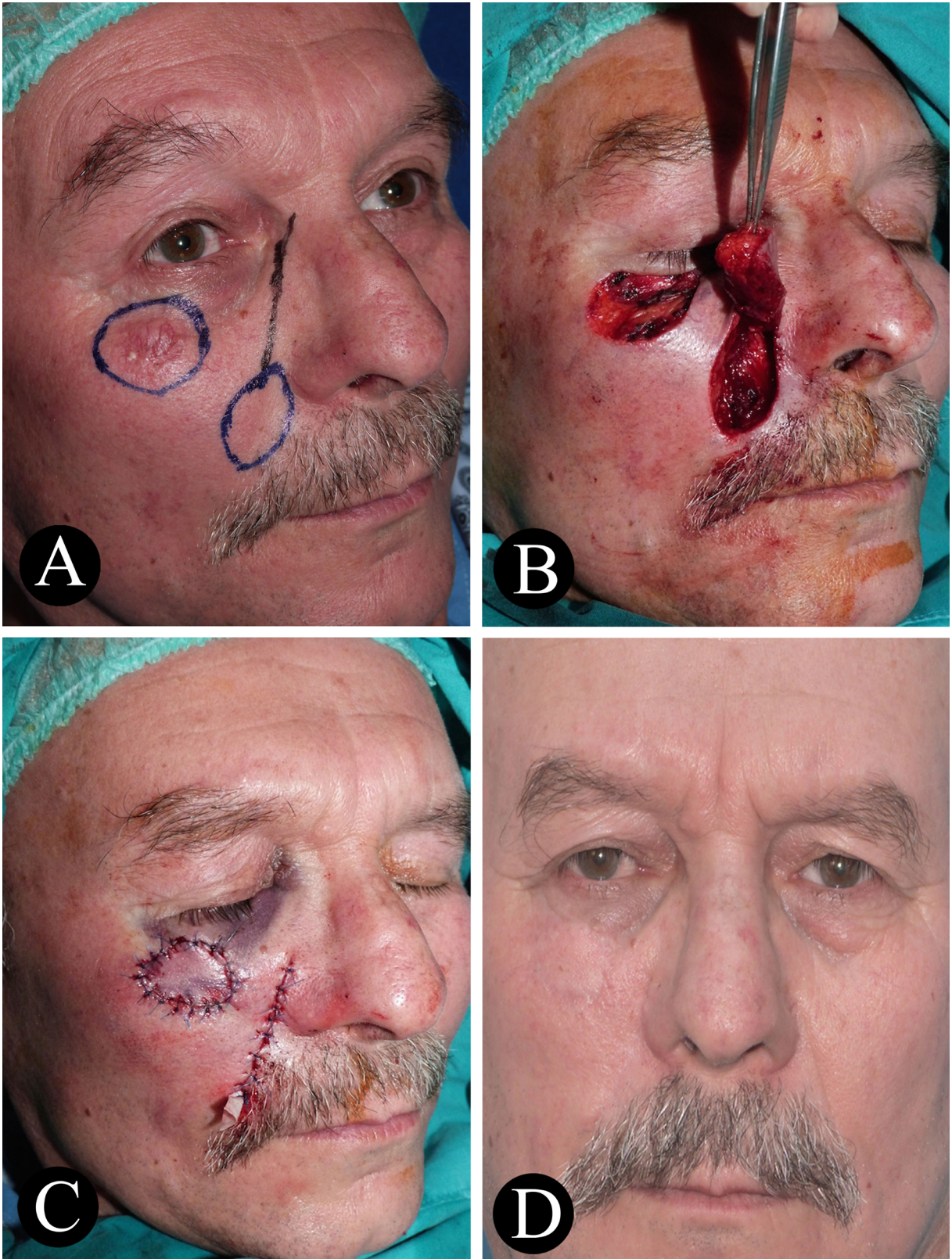


Figure 3. Patient 2. A. A 56-year-old male patient with right-sided nodular basal cell carcinoma; B. raised superiorly based nasolabial island flap to repair the lower eyelid defect located at zones II and V; C. immediate postoperative view; D. sixth postoperative month view of the patient.

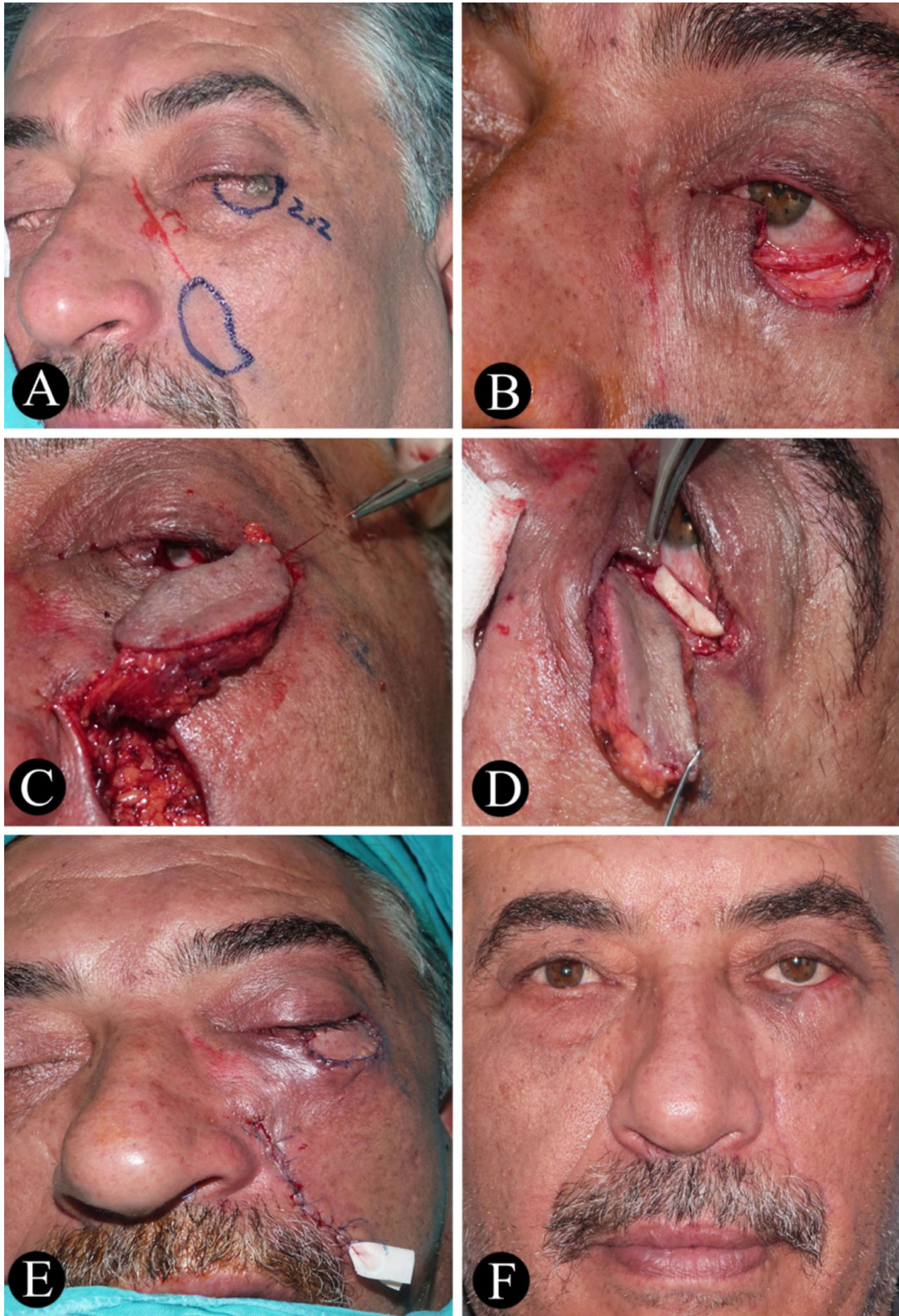


Figure 4. Patient 3. A. A 52-year-old male patient with left-sided basosquamous cell carcinoma; B. lower eyelid defect located at zones II and IV following resection of the cutaneous malignancy; C. raised superiorly based nasolabial island flap; D. posterior lamellar reconstruction by nasal septal chondromucosal graft; E. immediate postoperative view; F. eighth postoperative month view of the patient.

functioning and -appearing eyelid. Reconstruction can be based on a myocutaneous flap incorporating the orbicularis oculi muscle, or on a cutaneous flap in combination with a skin, cartilage, or composite graft, in cases of large full-thickness defects preventing direct closure (1,2).

The Mustardé and Tenzel flaps are workhorses, popular one-stage local flaps for the repair of full-thickness defects extending to the lateral aspect of the lower eyelid. The Mustardé flap can be used for entire full-thickness loss of the lower eyelid, and it has the advantages of good color match and reliable vascularity. However, wide dissection is required for adequate mobilization of the flap, and the surgical procedure is mostly performed under general anesthesia. In addition, ectropion due to gravity or contraction of the scar is one of the main disadvantages of the Mustardé flap (17).

The primary indication for the Tenzel flap is a full-thickness defect up to 50% of the width of the lower eyelid. It can be used for defects up to 70% of the lower eyelid length, if the lower eyelid retractors and inferior orbital septum are severed from their attachments (19–21). However, the Tenzel flap is not appropriate for lower eyelid defects involving zone V. Furthermore, overstretching of the flap during the closure of large defects must be avoided to prevent complications, including lateral canthal webbing, symblepharon, and tissue fullness of the lateral lower eyelid (3,22).

The nasolabial flap is a useful and practical random-pattern cutaneous flap with versatile and robust blood supply. It is an ideal reconstructive modality mostly used for defects of the nasal alar region (10,23) and an invaluable source of local tissue for the reconstruction of the upper and lower lips (24). Along with its common use for midfacial defects, the use of the nasolabial flap for the reconstruction of the lower eyelids has various advantages: 1) ease of dissection of the flap, 2) ease of access of the flap to zones II–V, 3) close skin color and texture matches with remaining eyelid tissue, 4) provision of eyelid–cheek transition according to aesthetic norms, and 5) most importantly, minimal donor site morbidity, as the donor

site scar is hidden within the nasolabial fold. Compared to the Tenzel flap, the nasolabial island flap can be used successfully for defects of greater horizontal length, as well as for the defects of zone V. Furthermore, it neither disrupts the lateral canthal region nor carries risk for injury to the frontal branch of the facial nerve, which can occur during the dissection of the Tenzel, and Mustardé flaps. In addition, in contrast to the Mustardé flap, medial transposition of the hair-bearing temporal area is avoided with the use of the nasolabial island flap in male patients (16). However, the superiorly based nasolabial island flap for reconstruction of the lower eyelid has some limitations that deserve consideration: 1) potential for compromise of blood supply to the flap, and 2) potential for ectropion or lagophthalmos. The subcutaneous tunnel created should be large enough and the pedicle of the flap should be sufficiently long to avoid disturbance of the blood supply of the flap by compression or undue tension. Furthermore, lateral canthal support should be performed in a meticulous manner by using nonabsorbable suture materials to reduce retention of the flap, and to avoid ectropion or lagophthalmos.

Along with the use of the nasolabial island flap as in the presented technique, nasolabial transposition flaps (16–18) can be used effectively for the repair of lower eyelid defects. However, the skin incisions of the transposition flaps should be performed more superiorly than the nasolabial island flap, which results in a more extensive donor site scar.

Despite the low number of patients, the present series demonstrates that lower eyelid defects involving zone IV or zone V can be repaired safely and reliably with the superiorly based nasolabial island flap, along with its use previously shown in the literature for zone II or zone III defects. The technique for raising the flap is fairly simple, with predictable surgical results. Furthermore, the superiorly based nasolabial island flap provides a reliable means of obtaining good wound healing with acceptable aesthetic and functional results of both the donor site and reconstructed area.

References

1. Nicolas Uzcategui. Eyelid reconstruction. In: Yen MT, editor. *Surgery of the Eyelid, Lacrimal System, and Orbit*. 2nd ed. New York, NY, USA: Oxford University Press; 2011. pp. 37-51.
2. Stein JD, Antonyshyn M. Aesthetic eyelid reconstruction. *Clin Plast Surg* 2009; 36: 379-397.
3. Spinelli HM, Jelks GW. Periocular reconstruction: a systematic approach. *Plast Reconstr Surg* 1993; 91: 1017-1024.
4. Lamont M, Jayaramachandran R, Tyers T. Transposed cheek flap in lower lid reconstruction: a retrospective case note review. *Orbit* 2011; 30: 261-264.
5. Tenzel RR, Stewart WB. Eyelid reconstruction by the semicircle flap technique. *Ophthalmology* 1978; 85: 1164-1169.
6. Hughes WL. A new method for rebuilding a lower lid: report of a case. *Arch Ophthalmol* 1937; 17: 1008-1017.
7. Labbé D, Benateau H, Rigot-Jolivet M. [Homage to Leon Tripiet. Description of the first musculocutaneous flap and current indications]. *Annales Chir Plast Esthet* 2000; 45: 17-23 (article in French with an abstract in English).

8. McGregor IA. Eyelid reconstruction following subtotal resection of upper or lower lid. *Br J Plast Surg* 1973; 26: 346-354.
9. Mustardé JC. Reconstruction of eyelids. *Ann Plast Surg* 1983; 11: 149-169.
10. Barba-Gómez J, Zuñiga-Mendoza O, Iñiguez-Briseño I, Sánchez-Tadeo MT, Barba-Gómez JF, Molina-Frechero N, Bologna-Molina R. Total lower-eyelid reconstruction: modified Fricke's cheek flap. *J Plast Reconstr Aesthet Surg* 2011; 64: 1430-1435.
11. Hofer SO, Mureau MA. Pedicled perforator flaps in the head and neck. *Clin Plast Surg* 2010; 37: 627-640.
12. Rong L, Lin Q, Zhang D, Peng WH. Repair of alar defects using a nasolabial flap and a partial-thickness cartilage complex graft. *Dermatol Surg* 2015; 41: 655-657.
13. Yoon TH, Yun IS, Rha DK, Lee WJ. Reconstruction of various perinasal defects using facial artery perforator-based nasolabial island flaps. *Arch Plast Surg* 2013; 40: 754-760.
14. Shipkov H, Stefanova P, Pazardzhikliev D, Djambazov K. Superiorly based nasolabial island flap: indications and advantages in upper lip reconstruction. *J Craniofac Surg* 2014; 25: 1928-1929.
15. Seo YJ, Hwang C, Choi S, Oh SH. Midface reconstruction with various flaps based on the angular artery. *J Oral Maxillofac Surg* 2009; 67: 1226-1233.
16. Tei TM, Larsen J. Use of the subcutaneously based nasolabial flap in lower eyelid reconstruction. *Br J Plast Surg* 2003; 56: 420-423.
17. Vayvada H, Menderes A, Tan Ö, Yilmaz M. Total lower eyelid reconstruction using paranasal flap. *J Craniofac Surg* 2006; 17: 1020-1026.
18. Paletta FX. Lower eyelid reconstruction. *Plast Reconstr Surg* 1973; 51: 653-657.
19. Kakizaki H, Madge SN, Mannor G, Selva D, Malhotra R. Oculoplastic surgery for lower eyelid reconstruction after periocular cutaneous carcinoma. *Int Ophthalmol Clin* 2009; 49: 143-155.
20. Tenzel RR. Reconstruction of the central one half of an eyelid. *Arch Ophthalmol* 1975; 93: 125-126.
21. Levine MR, Buckman G. Semicircular flap revisited. *Arch Ophthalmol* 1986; 104: 915-917.
22. Miller EA, Boynton JR. Complications of eyelid reconstruction using a semicircular flap. *Ophthalmic Surg* 1987; 118: 807-810.
23. Thornton JF, Griffin JR, Constantine FC. Nasal reconstruction: an overview and nuances. *Semin Plast Surg* 2008; 22: 257-268.
24. Rudkin GH, Carlsen BT, Miller TA. Nasolabial flap reconstruction of large defects of the lower lip. *Plastic Reconstr Surg* 2003; 111: 810-817.