

Neuroendocrine tumors detected in appendectomy specimens: ten-year single-center experience

Fatma ŞENEL^{1*}, Hatice KARAMAN¹, Hacer DEMİR²

¹Department of Pathology, University of Medical Sciences, Kayseri Training Research Hospital, Kayseri, Turkey

²Department of Medical Oncology, University of Medical Sciences, Kayseri Training Research Hospital, Kayseri, Turkey

Received: 10.09.2017 • Accepted/Published Online: 23.12.2017 • Final Version: 23.02.2018

Background/aim: The aim of this study was to investigate neuroendocrine tumors (NETs) detected in appendectomy specimens and the incidence and clinicopathologic characteristics of these tumors in our center.

Materials and methods: A total of 13,863 patients were evaluated retrospectively. All underwent appendectomy operation in the Kayseri Training and Research Hospital and had a histopathological examination at the Pathology Clinic between January 2007 and March 2017. Age, sex, preoperative clinical findings, operation procedure, and histopathological examination results of the cases reported to be NET are presented.

Results: NET was detected in 29 cases (0.2%) in the histopathological examination of 13,863 appendectomy specimens. Of these, 26 were classical carcinoid tumors and 3 were goblet cell carcinoid tumors (GCCTs). For the NET cases, the mean age was 37 years and the male to female ratio was 1.07. Only 68.9% of the patients underwent an appendectomy, and 31% of the patients underwent a secondary right hemicolectomy. Recurrences were not detected in any of the cases. In the present study, coincidence was determined in all of the cases with NET in the appendix.

Conclusion: Contrary to many studies, both NETs of the appendix and GCCT cases were slightly higher among males and advanced age groups in this study. The long-term life expectancy in cases of classical carcinoid tumors of the appendix is quite good.

Key words: Appendix, carcinoid tumor, goblet cell carcinoid tumor, neuroendocrine tumor

1. Introduction

Carcinoid tumors are rare, slow-growing neuroendocrine tumors arising from the enterochromaffin cells disseminated throughout the gastrointestinal and bronchopulmonary system (1). The gastrointestinal system has the largest proportion of neuroendocrine cells (2). However, neuroendocrine tumors (NETs) account for only 2% of all gastrointestinal system malignancies (3). NETs are most commonly observed in the small intestine, followed by the rectum and appendix (4). The biological behavior of these tumors is not fully understood (5). Carcinoid tumors of the appendix are clinically silent and detected incidentally in appendectomy specimens (6).

NETs of the appendix are divided into two categories based on complete or partial neuroendocrine cells: classical carcinoid tumors and goblet cell carcinoid tumors (GCCTs) and their variants (7). Classical carcinoid tumors include neuroendocrine differentiation. Tumors are called GCCT when they contain both glandular and

neuroendocrine differentiations (8). Goblet cell carcinoids originate from pluripotent intestinal stem cells that show both neuroendocrine and mucinous differentiations (9,10). GCCT is also known as adenocarcinoid, mucinous carcinoid, and crypt cell carcinoid tumors (9). The prognosis of classical carcinoid tumors is very good (11). GCCT follows a more aggressive course than classical carcinoid tumors (10).

In this study, we investigated the NETs found in the appendectomy materials of patients who had undergone an appendectomy in our center and the characteristics of these tumors.

2. Materials and methods

A total of 13,863 patients were evaluated retrospectively. All underwent appendectomies in the Kayseri Training and Research Hospital and had histopathological examinations between January 2007 and March 2017. Patients diagnosed with NET were included in the

* Correspondence: drfatmasenel2@gmail.com

study. Patient information was obtained from computer records and phone calls when required. The age, sex, preoperative clinical findings, operative procedure, and histopathological and immunohistochemical findings of these cases were recorded. In terms of treatment, a right hemicolectomy was applied if there was mesoappendix invasion in appendiceal NETs, if the tumor was larger than 2 cm, if there was mesoappendiceal lymph node metastasis, if there was a goblet cell component, or if the tumor continued within the surgical margin of the appendix.

NET cases were followed by ultrasonography and gallium 68 PET-CT in the postoperative 6th and 12th months and then annually while they were followed lifelong for recurrences. The follow-up period was calculated as the period starting from the date of diagnosis to either the date of relapse or the date of the last follow-up. The patients were followed for a mean period of 5 years (0.5–9.5 years)

The study was approved by the local ethics committee of Kayseri Training and Research Hospital (ID: 05).

3. Results

There were 29 NET cases (0.2%) in the 10-year archive. Of these, 26 were classical carcinoid and 3 were GCCT cases. Fifteen patients (51.7%) were male and 14 (48.2%) were female. The mean age was 37 years (range: 12–78 years). All 3 GCCT patients were male and the mean age was 67 years (range: 56–76 years). There was clinically acute appendicitis in 27 NET patients (93%). One patient (3.4%) was operated on due to an ovarian cyst and one (3.4%) was operated on due to a polyp in the colon.

Tumors were located in the distal part of the appendix in 86% of the cases, at the proximal end in 3.4% of cases, and in the middle part in 10.3% of cases. Tumors were smaller than 1 cm in 69% of the cases, between 1 and 2 cm in 27.5% of cases, and larger than 2 cm in 3.4% of cases. The tumor penetration depth was in the submucosa or muscular layer in 51% of the cases, in the serosa in 20.6% of cases, and in the mesoappendix in 27.5% of cases (Table). Fifteen cases (51.7%) were accompanied by acute appendicitis as a histopathological finding.

Table. Clinicopathological characteristics.

	CCT (n = 26)	GCCT (n = 3)	Total (n = 29) (%)
Age, median (range)	37 (12–78)	67 (56–76)	
Sex, no.			
Female	14	0	14 (48.2)
Male	12	3	15 (51.7)
Tumor localization			
Mucosal layer	15	0	15 (51)
Serosal layer	6	0	6 (20.6)
Mesoappendix	5	3	8 (27.5)
Tumor size			
<1 cm	20	0	20 (69)
1–2 cm	5	3	8 (27.5)
>2 cm	1	0	1 (3.4)
Extension			
Distal	22	3	25 (86)
Proximal	1	0	1 (3.4)
Body	3	0	3 (10.3)
Treatment			
Appendectomy	20	0	20 (68.9)
Secondary right hemicolectomy	6	3	9 (31)

CCT: Classical carcinoid tumor.

GCCT: Goblet cell carcinoid tumor.

In histopathological examination, classical carcinoid tumor cases were observed. There were cells with a small round nucleus and narrow cytoplasm forming small islands and cord-like structures (Figure 1). All of the cases were immunohistochemically studied with some neuroendocrine markers such as neuron-specific enolase (NSE) (Figure 2), chromogranin, and synaptophysin; positive staining was observed in all cases. None of the cases had lymphovascular or perineural invasion. The Ki67 index was 1%–2%.

In the GCCT cases, tumors had extensive, eosinophilic, and granular cytoplasm and were characterized by microglandular small goblet cell islands with eccentric nuclei (Figure 3). Positive staining was obtained with both epithelial markers such as CK7 and CK20 (Figure 4A) and chromogranin-A (Figure 4B) and NSE among neuroendocrine markers. Perineural invasion was observed in 2 of the cases. The Ki67 index was 3%–10%.

Of the NET patients, 68.9% underwent appendectomies and 31% underwent secondary right hemicolectomies.

The patients were followed for a mean period of 5 years (0.5–9.5 years) with abdominal ultrasonography and gallium 68 PET-CT in terms of recurrences. Recurrences were not detected in any of the patients. None of the patients died due to NET. One patient died from heart failure 5 years after an appendectomy.

4. Discussion

Carcinoid tumors originate from enterochromaffin cells, a type of neuroendocrine cells in the lamina propria and submucosa (12). The incidence of appendiceal NETs is reported to be between 0.27% and 1.6% (13,14). It is reported that the mean age of patients at diagnosis is the

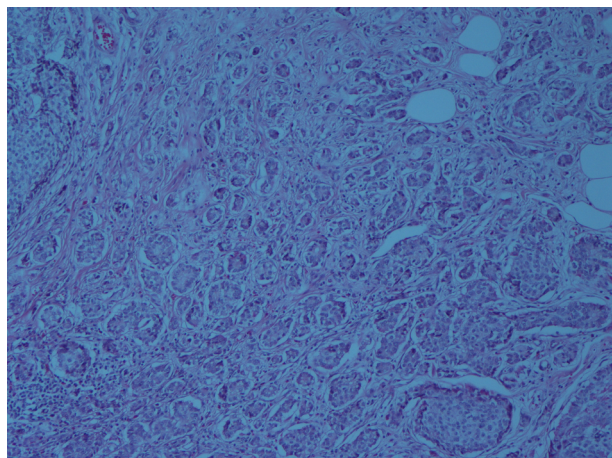


Figure 1: Hematoxylin and eosin-stained sections showing the tumor itself is composed of small round nucleus and narrow cytoplasm forming small islands and cord-like structures (H&E, 200×).

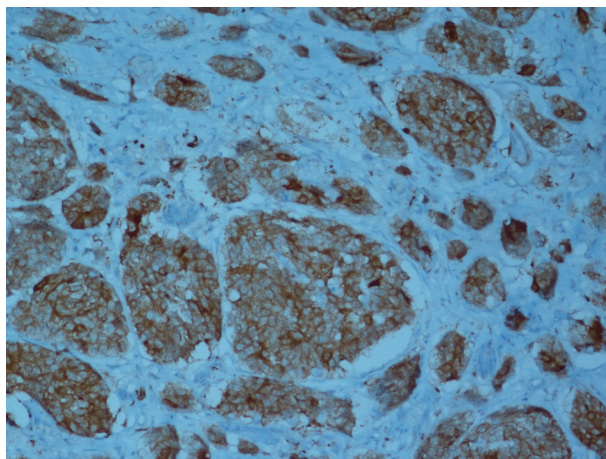


Figure 2. In the immunohistochemical studies, strong positivity for neuroendocrine cell component marker NSE was detected in the tumor (IHC, 200×).

late second decade (4,15) and the ratio of males to females is 1:2–4 (16). The incidence of appendiceal NETs is 0.2% in this study, and the mean age is higher (37 years) and the ratio is slightly higher for males (M:F = 1.07), as highlighted in previous studies (4,15,16).

In the literature, GCCTs are reported to be 6% of all appendiceal NETs (7,17). This rate is higher in the present study, where GCCT cases constitute 10.3% of all appendiceal NETs. It has been reported that GCCTs are observed at the same frequency in both males and females and the mean age at diagnosis is the 5th decade (18). Contrary to these studies, 3 of our GCCT patients are male and are older than average (mean age: 67 years).

The WHO 2010 classification uses the ENETS grading criteria (8). In 2010, the WHO and the European Neuroendocrine Tumor Society (ENETS) divided the grade of NETs into three groups based on the Ki67 proliferation index and the number of mitoses. If there are less than two mitoses in 10 HPF and the Ki67 index is less than 2%, it is called “NET, low grade (Grade 1)”. If there are 2–20 mitoses and a Ki67 index of 3%–20%, it is called “NET, moderate-grade (Grade 2)”. If there are more than 20 mitoses with a Ki67 index greater than 20%, it is classified as “neuroendocrine carcinoma, high grade (Grade 3)” (8,10).

Carcinoid tumors of the appendix are generally asymptomatic due to their small size and are often identified incidentally during the histopathological examination of appendectomy materials (19). Sometimes NETs localized at the base of the appendix, depending on the site, may block the lumen and cause clinical acute appendicitis (15). In this study, 93% of NET patients were operated on with acute appendicitis.

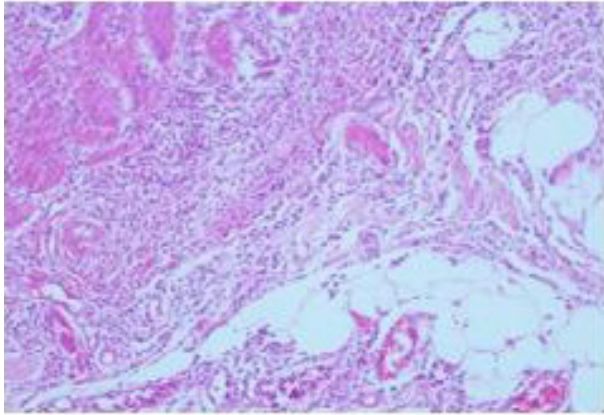


Figure 3. Hematoxylin and eosin-stained sections showing the tumor itself is composed of small uniform tumor nests of goblet cells often arranged in a microglandular fashion (H&E, 200×).

In general, 50% of GCCT patients present with abdominal pain and palpable mass (17). Others are identified incidentally, from the appendectomy materials of patients operated on with a diagnosis of acute appendicitis, like in the present study (9,10). Perforated appendicitis is reported in 27% of GCCT cases (19). Perforated appendicitis was observed in 33% of the GCCT cases in this study. The effect of perforated acute appendicitis in GCCT cases has not been clarified. In a retrospective series of 20 GCCT patients with perforated appendicitis, a lower rate of peritoneal metastases was observed in the perforated group (15%) compared to the nonperforated group (42%) with no difference in peritoneal relapse between the two groups (19). Classical carcinoid cases show neuroendocrine morphology, and GCCT includes goblet cell morphology as well as neuroendocrine morphology.

Both types of carcinoid tumors show neuroendocrine marker expression immunohistochemically. In GCCT, cytokeratins such as CK7 and CK20 are expressed, as in colonic adenocarcinoma, but they are not expressed in classical carcinoid tumors (20). In addition to classical histological images, GCCT cases show extensive invasion and perineural invasion in the mesoappendix, as in our cases (21).

The majority of NETs are observed in the distal part of the appendix, as in the present study, because the majority of neuroendocrine cells are located in this region (22). Approximately 80% of appendiceal NETs are smaller than 1 cm in diameter (23). In the current study, 69% of the appendiceal NETs were of this size.

In terms of treatment, a right hemicolectomy is recommended if there is mesoappendix invasion in appendiceal NETs, if the tumor is larger than 2 cm, if there is mesoappendiceal lymph node metastasis, if there is a goblet cell component, or if the tumor continues within the surgical margin of the appendix. If there is no local metastasis, appendectomy is sufficient for tumors smaller than 2 cm. A right hemicolectomy is recommended in young patients with tumors larger than 2 cm, although there is no lymph node metastasis. A more conservative approach is recommended in elderly patients because the tumor develops more slowly (24).

Appendiceal carcinoid tumors of less than 1 cm in diameter have an excellent prognosis and are adequately treated by appendectomy alone. The risk of metastasis is 0% in appendiceal carcinoid tumors smaller than 1 cm, whereas it is 2%–18% in the small intestine and 0%–20% in the rectum. Moertel found no recurrences and no metastases among 108 patients with a tumor size of less than 1 cm. However, there was a tumor recurrence of 80% in patients with lesions greater than 2 cm in diameter (25).

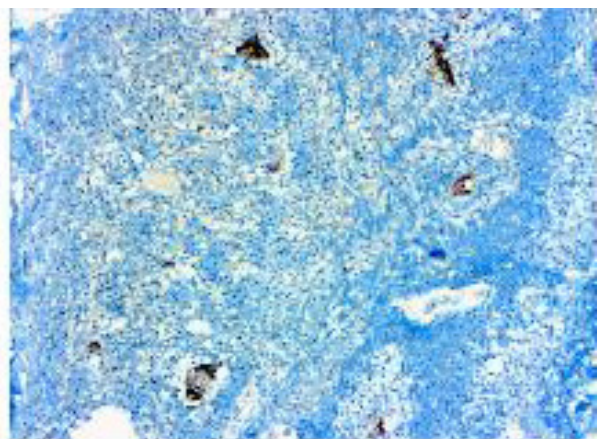
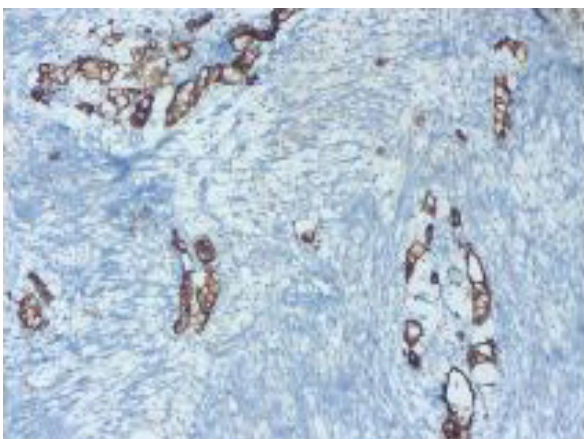


Figure 4. A) Tumor cells exhibit strong immunoreactivity for CK20 (IHC, 200×). B) In the immunohistochemical studies strong positivity was detected in the tumor for neuroendocrine cell component marker chromogranin-A (IHC, 200×).

The recommended treatment for goblet cell carcinoid is a right hemicolectomy, especially if the tumor has spread beyond the appendix or shows a high mitotic count. Although many authors suggest a routine right hemicolectomy for goblet cell carcinoids, this recommendation has been questioned, and some authors believe that appendectomy alone may be sufficient if the appendiceal margin is clear, there is no evidence of spread into the periappendiceal soft tissue, and the mitotic count is no more than two mitoses per 10 HPF (9,26,27). Both the European and the North American Neuroendocrine Tumor Society guidelines recommend a right hemicolectomy after appendectomy due to the high rate of metastases and its impact on prognosis (28).

Twenty of our NET patients underwent only an appendectomy operation. Nine patients underwent a secondary right hemicolectomy. Eight patients underwent a right hemicolectomy due to mesoappendiceal invasion, and 3 of them were GCCT patients. One patient underwent a right hemicolectomy because there was a tumor at the surgical margin of the appendix.

The prognosis for classical carcinoid tumors is very good. If the tumor is localized in the appendix, the 5-year survival rate is 94% (29). The most common metastasis in NETs is the right colon and ileum with the direct

extension, followed by lymph nodes, the peritoneum, and the omentum, respectively (26).

GCCTs follow a more aggressive course than classical carcinoid tumors. If the tumor in a case of GCCT is limited to the appendix, the 5-year survival rate is 50%–80%, but it is less than 10% in the presence of distant metastasis. Approximately 10% of GCCT cases have liver, ovarian, or peritoneal metastasis during diagnosis (10). When a mucinous tumor is observed in the ovary in GCCT cases, it should be kept in mind that this may be the primary tumor of the ovary or the ovarian spread of GCCT. GCCTs of appendiceal origin express elevated *MUC2* and *MUC5AC*. In contrast, mucinous tumors arising from ovarian primaries express only *MUC5AC* (30). This could be beneficial in the determination of the origin of ovarian mucinous malignancy in females (31). In postmenopausal female patients with GCCT, prophylactic bilateral oophorectomy, although not based on evidence, should be considered (18,26).

Finally, appendiceal NETs are asymptomatic. The symptoms resemble those of acute appendicitis. Since the diagnosis is usually established after appendectomy, appendectomy materials should be examined carefully. GCCTs follow a more aggressive course; thus, it is required to be more careful in the diagnosis.

References

1. Pinchot SN, Holen K, Sippel RS, Chen H. Carcinoid tumors. *Oncologist* 2008; 13: 1255-1269.
2. Bernick PE, Klimstra DS, Shia J, Minsky B, Saltz L, Shi W, Thaler H, Guillem J, Paty P, Cohen AM et al. Neuroendocrine carcinoma of the colon and rectum. *Dis Colon Rectum* 2006; 47: 163-169.
3. Estrozi B, Bacchi CE. Neuroendocrine tumors involving the gastroenteropancreatic tract: a clinicopathological evaluation of 773 cases. *Clinics* 2011; 66: 1671-1675.
4. Maggard MA, O'Connell JB, Ko CY. Updated population-based review of carcinoid tumors. *Ann Surg* 2004; 240: 117-122.
5. Gustafsson BI, Kidd M, Modlin IM. Neuroendocrine tumors of the diffuse neuroendocrine system. *Curr Opin Oncol* 2008; 20: 1-12.
6. Modlin IM, Lye KD, Kidd M. A 5-decade analysis of 13,715 carcinoid tumors. *Cancer* 2003; 97: 934-959.
7. Rosai J. Appendix. In: Rosai and Ackerman's Surgical Pathology. 10th ed. Edinburgh, UK: Elsevier; 2011. pp. 714.
8. Bosman F, Carneiro F, Hruban R, Theise N, editors. WHO Classification of Tumours of the Digestive System. Lyon, France: IARC Press; 2010.
9. Doyle LA, Odze RW. Inflammatory disorders of the appendix. In: Odze RD, Goldblum JR, editors. Surgical Pathology of the GI Tract, Liver, Biliary Tract and Pancreas. 2nd ed. Philadelphia, PA, USA: Elsevier; 2015. pp. 512-529.
10. Paşaoğlu E. Apendiksin tümörleri. In: Doğuşoy G, editor. Gastroenteroloji Patoloji. İzmir, Turkey: O'Tip Kitabevi ve Yayıncılık; 2015. pp. 240-259 (in Turkish).
11. Ruoff C, Hanna L, Zhi W, Shahzad G, Gotlieb V, Saif MW. Cancers of appendix: review of the literatures. *ISRN Oncology* 2011; 2011: 728579.
12. Gosset A, Masson P. Tumeurs endocinnes de l'appendice. *La Presse Medicale* 1914; 22: 237-240 (in French).
13. Zvizdić Z, Đuran A, Karavdić K, Jakić A, Milišić E. Carcinoid tumors of the appendix vermiform in children-ten year analysis of 1503 appendectomies. *BH Surgery* 2011; 1: 100-103.
14. Barreto SG, Tiong L, Thomas T, Travers E, Williams RS. Incidental appendiceal carcinoids: is surgery affecting their incidence? *World J Oncol* 2012; 3: 227-230.
15. Goede AC, Caplin ME, Winslet MC. Carcinoid tumour of the appendix. *Br J Surg* 2003; 90: 1317-1322.
16. McGory ML, Maggard MA, Kang H, O'Connell JB, Ko CY. Malignancies of the appendix: beyond case series reports. *Dis Colon Rectum* 2005; 48: 2264-2271.
17. Gramlich J, Petras R. Vermiform appendix. In: Mills S, editor. *Histology for Pathologists*. Philadelphia, PA, USA: Lippincott Williams; 2007. pp. 648-657.

18. Pham TH, Wolff B, Abraham SC, Drelichman E. Surgical and chemotherapy treatment outcomes of goblet cell carcinoid: a tertiary cancer center experience. *Ann Surg Oncol* 2006; 13: 370-376.
19. O'Donnell ME, Carson J, Garstin WI. Surgical treatment of malignant carcinoid tumours of the appendix. *Int J Clin Pract* 2007; 61: 431-437.
20. Alsaad KO, Serra S, Schmitt A, Perren A, Chetty R. Cytokeratins 7 and 20 immunexpression profile in goblet cell and classical carcinoids of appendix. *Endocr Pathol* 2007; 18: 16-22.
21. Vilchez RT, Martin DP, Blanco CQ, Aragonés AM, Liebana RF, Donoso FJM, Conejo EA. Goblet cell carcinoid of the appendix. A 52 years old male with acute appendicitis. *Oncologia* 2007; 30: 72-75.
22. Hemminki K, Li X. Incidence trends and risk factors of carcinoid tumors: a nationwide epidemiologic study from Sweden. *Cancer* 2001; 92: 2204-2210.
23. Debnath D, Rees J, Myint F. Are we missing diagnostic opportunities in cases of carcinoid tumours of the appendix? *Surgeon* 2008; 6: 266-272.
24. Moertel CG, Weiland LH, Nagorney DM, Dockerty MB. Carcinoid tumor of the appendix: treatment and prognosis. *N Engl J Med* 1987; 317: 1699-1701.
25. Moertel CG. Treatment of the carcinoid tumor and the malignant carcinoid syndrome. *J Clin Oncol* 1983; 1: 727-740.
26. Tang LH, Shia J, Soslow RA, Dhall D, Wong WD, O'Reilly E, Qin J, Paty P, Weiser MR, Guillem J et al. Pathologic classification and clinical behavior of the spectrum of goblet cell carcinoid tumors of the appendix. *Am J Surg Pathol* 2008; 32: 1429-1443.
27. Shenoy S. Goblet cell carcinoids of the appendix: tumor biology, mutations and management strategies. *World J Gastrointest Surg* 2016; 8: 660-669.
28. Pape UF, Perren A, Niederle B, Gross D, Gress T, Costa F, Arnold R, Denecke T, Plöckinger U, Salazar R et al. ENETS Consensus Guidelines for the management of patients with neuroendocrine neoplasms from the jejunum-ileum and the appendix including goblet cell carcinomas. *Neuroendocrinology* 2012; 95: 135-156.
29. Modlin IM, Sandor A. An analysis of 8305 cases of carcinoid tumors. *Cancer* 1997; 79: 813-829.
30. Pahlavan PS, Kanthan R. Goblet cell carcinoid of the appendix. *World J Surg Oncol* 2005; 3: 36.
31. O'Connell JT, Tomlinson JS, Roberts AA, McGonigle KF, Barsky SH. Pseudomyxoma peritonei is a disease of MUC2-expressing goblet cells. *Am J Pathol* 2002; 161: 551-564.