

The effect of low molecular weight heparin on salvaging the zone of stasis in an experimental burn model

Muhammet URALOĞLU^{1*}, Murat LİVAOĞLU¹, Özgür AGDOĞAN², Şafak ERSÖZ³, Naci KARAÇAL¹

¹Department of Plastic and Reconstructive Surgery, Faculty of Medicine, Karadeniz Technical University, Trabzon, Turkey

²Department of Plastic and Reconstructive Surgery, Faculty of Medicine, Namık Kemal University, Tekirdağ, Turkey

³Department of Pathology, Faculty of Medicine, Karadeniz Technical University, Trabzon, Turkey

Received: 12.10.2017 • Accepted/Published Online: 28.04.2018 • Final Version: 14.06.2018

Background/aim: Multiple zones of injuries are formed after burns, consisting of a zone of coagulative necrosis, a zone of hyperemia, and a zone of stasis, in which progressive microcirculatory thrombosis leads to degeneration and deepening of the wound. We used an experimental rat comb burn model to test the hypothesis that use of low molecular weight heparin (LMWH) may save the zone of stasis.

Materials and methods: Adult female rats were randomly divided two groups: the LMWH group (n = 8) rats received subcutaneous LMWH injections, while the saline group (n = 8) rats were injected with the same volume of saline solution by the same route. The zone of stasis was evaluated macroscopically and histologically, and functional capillary density was evaluated.

Results: Histological assessments revealed higher macrophage numbers and PML density, fibroblast proliferation, and angiogenesis in the LMWH group than in the saline group. Functional capillary density measurement in the stasis zones revealed no significant difference between the two groups in the first 4 days, although a significant difference in favor of the LMW group was observed in the last 3 days.

Conclusion: The results of this experimental study show that LMWH is effective in saving the zone of stasis.

Key words: Low molecular weight heparin, burn, stasis zone

1. Introduction

Burn injuries are among the most devastating of all traumas, a significant global public health problem, and a cause of major morbidity and mortality worldwide. Burn wound management therefore deserves very significant attention. Following acute burn injury, multiple concentric zones of injury form, as first described by Jackson in 1953 (1): the central zone of coagulation, the zone of stasis (the intermediate zone), and the outer zone of hyperemia.

Damage from burn trauma causes irreversible necrosis in the area known as the zone of coagulation. As a result of indirect damage resulting from thermal trauma, a zone of stasis forms around the zone of coagulation. The zone of stasis is an important component of the burn injury because it may progress to coagulation necrosis after the first 24 h following the trauma, before which it is vital and can be salvaged. Therefore, by salvaging the zone of stasis, the progression of burn wound-related degeneration can be prevented, and this has been one of the main foci of burn-related research for many years. Many agents and methods have been used to salvage the stasis zone (2–6).

Better understanding of the pathological process in this zone may provide important targets for procedures aiming at preventing progression of burn injuries.

Low molecular weight heparins (LMWHs) are an important new class of anticoagulants with several advantageous over their ancestor, unfractionated heparin, for the prophylaxis and treatment of venous thromboembolism (7).

The prominent role of microthromboembolism and associated hypoxia and necrosis in the zone of stasis following burn injury, and effective clinical use of LMWHs, makes these anticoagulants an attractive option for preventing deepening of the wound by salvaging the zone of stasis.

The purpose of this study was to investigate the potential effect of enoxaparin, a LMWH, on salvaging the zone of stasis in an experimental rat burn model.

2. Materials and methods

The study protocols were approved by the Local Ethics Committee on Animal Research. Adult female Sprague-

* Correspondence: uraloglu@hotmail.com

Dawley rats (250–300 g) were housed in standard conditions (21 ± 1 °C and a 12:12 light–dark cycle) with free access to water and standard animal chow. Sixteen rats were randomly divided into two groups (n = 8 in each): group 1 (the LMWH group) and group 2 (the saline group).

The dorsal skin was shaved under general anesthesia (50 mg/kg ketamine, Ketalar, Pfizer and 10 mg/kg xylazine Rompun, Bayer), and burn wounds were induced using the comb model (8). A rectangular brass comb consisting of four rows (10 × 20 mm) and three interspaces (5 × 20 mm) was heated in boiling water and held to the skin surface for 20 s (Figure 1). This was performed without applying any additional pressure to the comb beyond that of gravity. The rats were kept in individual cages after the burn injury. Thirty minutes after the induction of burn wounds, 1.5 mg/kg enoxaparin (Clexane, Sanofi, Aventis) was administered subcutaneously into the inguinal area distant to the burn injury site in the LMWH group rats, and the same dose was repeated daily for the next 7 days, starting 24 h from the first injection. The saline group was given the same amount of saline via the same route. The rats were kept in individual cages in the postburn period. The functional capillary density (FCD) evaluation was performed daily, and all rats were sacrificed for histological evaluation on day 8, postburn.

2.1. Outcome of necrosis

The outcome of necrosis was measured grossly. This was done by measuring each interspace with complete necrosis (turning black) and those of a viable nature. The percentage represented by the viable area was calculated by comparing these with the percentage of interspaces with complete necrosis.

2.2. Functional capillary density evaluation

FCD evaluations were performed using an orthogonal polarization spectral (OPS) imaging device equipped

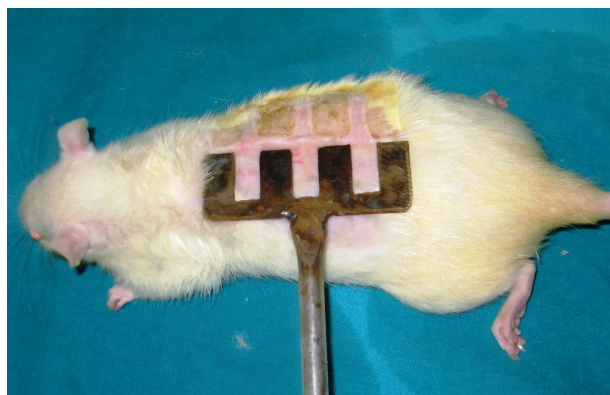

Figure 1. Application of comb to induce burn. A rectangular brass comb was heated in boiling water and held to the skin surface for 20 s.

with a video microscope (Cytoscan A/R, Cytometrics, Philadelphia, PA, USA), and all data were saved in AVI format (Sony VGN-FW 230J/H) and analyzed with this software (9–11). Burn areas were examined daily, for 7 days, by recording microcirculation over at least 20 s (Figure 2). The measurements were done in the stasis zone, between coagulation zones. Video recordings were made for each and transferred from the OPS imaging device to computer software (CapiScope; Lekam Medical Ltd., Devon, UK) for further evaluation. All FCD measurements were performed using this software (9). FCD was defined as the length of erythrocyte-perfused capillaries (cm) per observation area (cm²). The observer measuring FCD was blinded to the treatment administered.

2.3. Histological evaluation

Once the procedures were complete, the animals were sacrificed, and a full-thickness skin biopsy was taken from each. These were fixed with 10% formalin solution, dehydrated with alcohol, and embedded in paraffin blocks. The specimens were stained with hematoxylin and eosin (H&E) and Masson's trichrome stain and analyzed under light microscopy. Macrophage and polymorphonuclear leukocyte (PMN) density, fibroblast proliferation, and angiogenesis were analyzed as the percentage of 40×-magnified burn zone images using Analysis 5

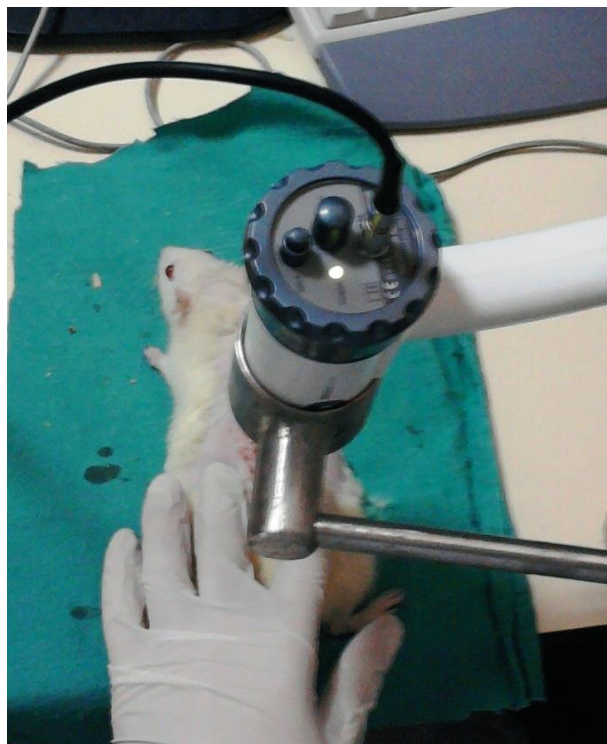

Figure 2. Vascularity was evaluated using orthogonal polarization spectral (OPS) imaging.

software (Olympus Soft Imaging Solutions, Munster, Germany). The results were expressed as the number of cells in each microscopic area. The investigator conducting the histological examinations was blinded to the groups.

2.4. Statistical analysis

Statistical analyses were performed using SPSS for Windows (SPSS Inc., Chicago, IL, USA). All quantitative data were analyzed using the Mann–Whitney U and Friedman tests, where appropriate. A P-value < 0.05 was regarded as significant.

3. Results

3.1. Macroscopic assessment

No obvious complications occurred during the research period in terms of saline and LMWH injection, and no mortality was encountered. Ratios of surviving areas in the zone of stasis were calculated with translucent graph paper on day 7. In the saline group most of the interspace areas were necrotic in appearance on day 7 (Figure 3a), while in the LMWH group most of the interspace areas appeared to be viable (Figure 3b). The mean surviving

area was $70.40 \pm 11\%$ in the LMWH group and $55.10 \pm 4.01\%$ in the saline group. The difference was statistically significant ($P = 0.001$).

3.1. Functional capillary density

FCD values worsened progressively throughout the experiment in the saline group, but remained relatively constant in the LMWH group. When the FCD values were compared between the groups, LMWH was observed to provide a time-dependent favorable effect. The difference between the groups was statistically significant from day 4 and remained so throughout the remainder of the experimental period (Figure 4; Table 1).

3.2. Histological assessment

The mean macrophage infiltration values in the LMWH and saline groups were 16.5 ± 3.7 ($n = 8$) and 13.1 ± 3.1 ($n = 8$), respectively ($P = 0.082$, Table 2). PMN density was lower in the saline group (mean 7.4 ± 2.6) than in the LMWH group (mean 8.6 ± 3.7), but the difference was not statistically significant ($P = 0.597$).

Fibroblast proliferation was significantly higher in the LMWH group (mean 77.0 ± 23.6) than in the saline

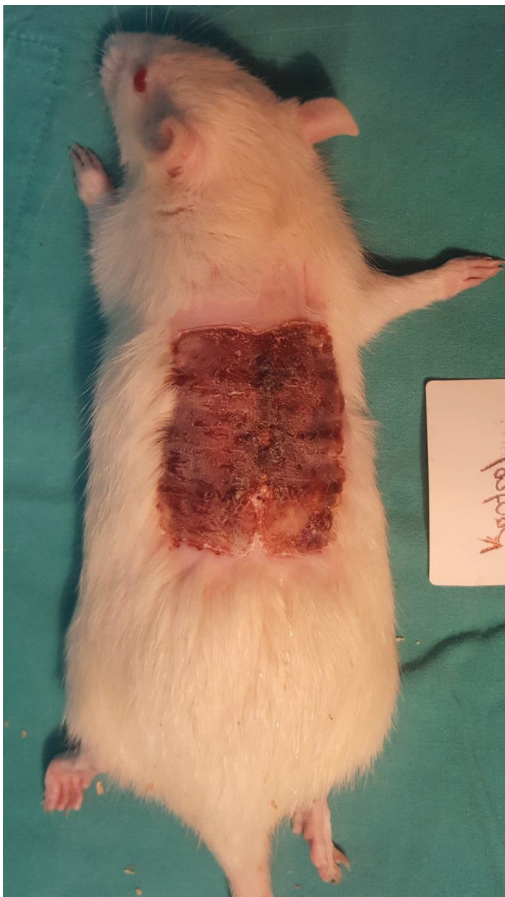


Figure 3a. Saline group, day 7.

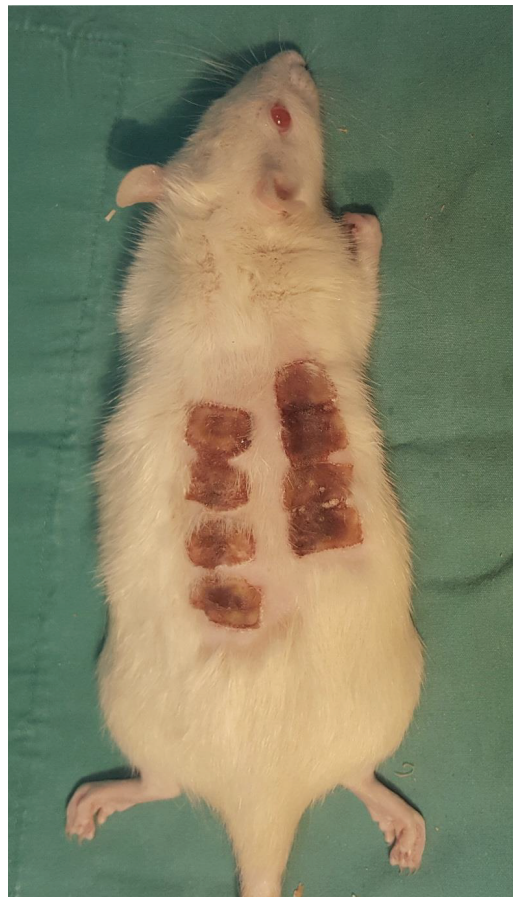

Figure 3b. LMWH group, day 7.

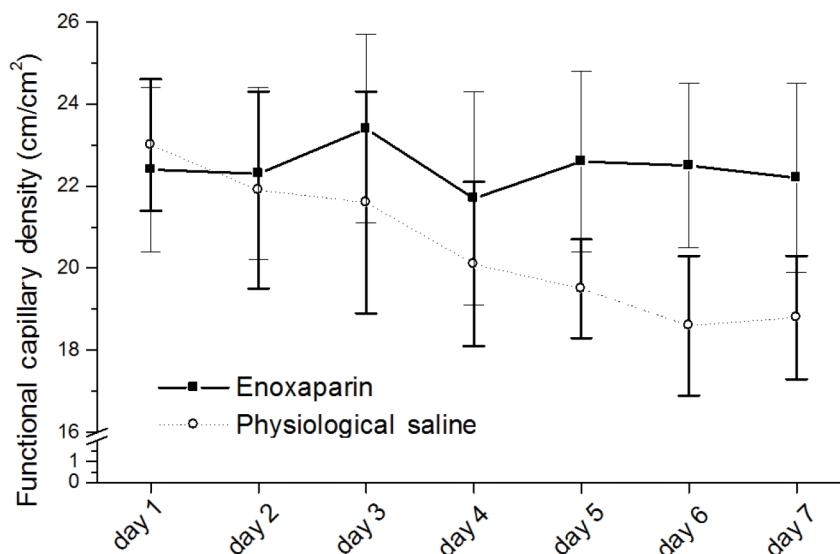


Figure 4. Time course of functional capillary density values in the low molecular weight heparin and saline groups.

Table 1. The effect of low molecular weight heparin on functional capillary density. Different superscript letters indicate significant differences ($P < 0.001$) in mean values. Mean values with the same superscript letters (a or b) are not statistically significant different.

	Functional capillary density						
	Day 1	Day 2	Day 3	Day 4	Day 5	Day 6	Day 7
LMWH	22.4 ± 2.0 ^a	22.3 ± 2.1 ^a	23.4 ± 2.3 ^a	21.7 ± 2.6 ^a	22.6 ± 2.2 ^a	22.5 ± 2.0 ^a	22.2 ± 2.3 ^a
Saline	23.0 ± 1.6 ^a	21.9 ± 2.4 ^a	21.6 ± 2.7 ^a	20.1 ± 2.0 ^a	19.5 ± 1.2 ^b	18.6 ± 1.7 ^b	18.8 ± 1.5 ^b
P-value	0.400	0.529	0.059	0.431	0.003	0.003	0.009

group (mean 54.5 ± 14.9 , $p = 0.035$). Angiogenesis was significantly higher in the LMWH group (mean 15.0 ± 3.4) compared to the saline group (mean 10.5 ± 3.3) ($P = 0.023$) (Figure 5; Table 2).

4. Discussion

Inflammatory mediators generated from the inflammatory cells through thermal action can impact adversely on burn wounds (12–15). Hemodynamic alterations and additional infection may also lead to further progression of burn wound necrosis (14,16). Following burn trauma, the zone of stasis can be supported and progressive tissue necrosis thereby prevented by salvaging this zone using agents with potential beneficial effects on perfusion in the affected area (17–20).

Progressive burn-mediated damage resulting from impaired circulation may occur in the zone of stasis or the zone of ischemia. It has been postulated that individual and/or combined effects of hypercoagulability, neutrophil occlusion, erythrocyte plugging, vasoconstriction, and

edema mediate the reduced blood flow in the zone of stasis, and that the process thus leads to hypoxia and free radical-mediated injury (21). Insufficiency of the blood supply is a key element in the process among those factors causing progression of burn wound and delays in healing (15,22).

Thrombus formation is one of the main mechanisms involved in compromised local circulation in the zone of stasis, since thrombus-mediated vessel occlusion has been histologically documented in burn injuries (23,24).

LMWHs are derived from unfractionated heparin through deaminative hydrolysis of heparin. They exhibit inhibitory action on active factor X with weak antithrombin activity and are effective in the prevention of vascular thrombosis, as well as possessing the advantage of a lower risk of hemorrhage, a side-effect that is relatively unpredictable with heparin use (25). LMWHs have been successfully used for many years for the prevention and treatment of a variety of clinical conditions, including venous thromboembolism (7),

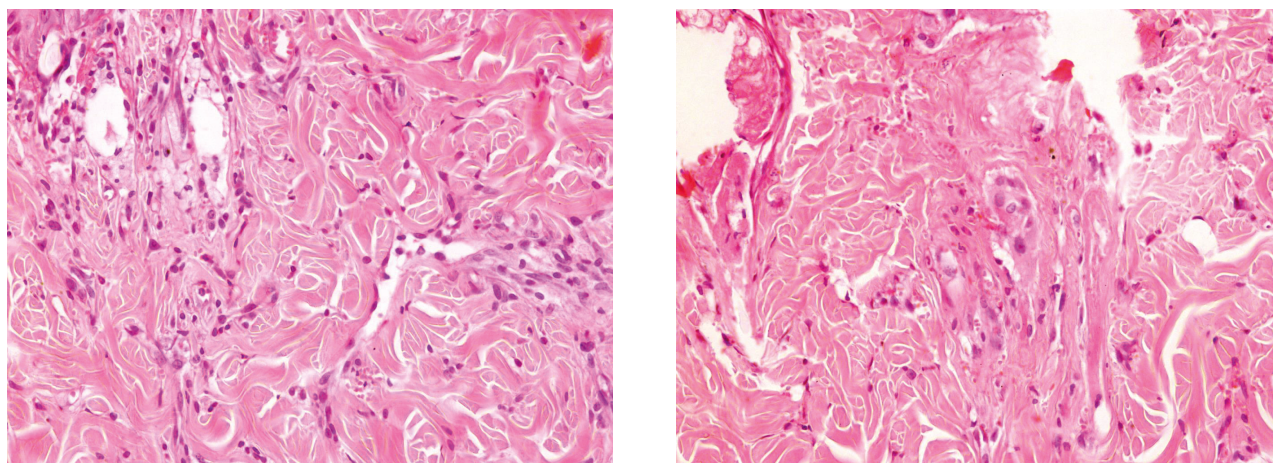


Figure 5. Histological appearances of the zone of stasis in the low molecular weight heparin (LMWH) and saline groups. 5a. LMWH group. 5b. Saline group.

Table 2. The effect of low molecular weight heparin on local responses to burn injury.

	Angiogenesis	Fibroblast	Macrophage density	PMN
LMWH group	15.0 ± 3.4	77.0 ± 23.6	16.5 ± 3.7	8.6 ± 3.7
Saline group	10.5 ± 3.3	54.5 ± 14.9	13.1 ± 3.1	7.4 ± 2.6
P-value	0.023	0.035	0.082	0.597

acute coronary syndrome, and coronary and peripheral percutaneous revascularization. Controlled clinical trials have also confirmed that LMWH is superior to heparin in the prevention of arterial thrombosis (26).

Heparin-induced thrombocytopenia (HIT) is a potentially destroying immune mediated adverse drug reaction during the emergence of antibodies that activate platelets in the presence of heparin. Despite thrombocytopenia, bleeding is rare; HIT is associated with thromboembolic complications. Arterial thrombosis occurs more frequently than venous thrombosis in HIT patients. The incidence is approximately 5% with unfractionated heparin and 0.5% with LMWH (27).

To date, some anticoagulants, steroid and nonsteroid antiinflammatory drugs, antiaggregants, thrombolytic agents, hormones, and antioxidants were investigated in experimental and clinic studies for salvaging the zone of stasis (2–5,17,28–36). Very few of them have been used in clinical practice, but LMWH may be used routinely.

Some of the evidence from clinical and animal studies supports the antiinflammatory role heparin and heparin-related derivatives (37,40). It is now well established that LMWH has many superior advantages, such as a lower risk of hemorrhage and a positive effect on the serum lipid profile. In the first hours after a traumatic injury such as burns, the inflammatory response includes increased

nitric oxide (NO) production. NO has a protagonist role in inflammatory diseases. Increased NO after burning combines with peroxy-nitrite-forming superoxide anion (39). Free radicals and lipid peroxidation mediated injury causes significant cell damage in burn trauma. Burn patients were treated with and without LMWH to provide evidence that LMWH has nitric oxygen synthase (NOS) reducing activity and LMWH was observed to be more effective than heparin in the treatment of burn patients. This was proved by colorimetric and immunohistological studies (39,40).

In the light of these properties, antithrombotic agents exhibit a high potential indication for salvaging the zone of stasis in burn injuries. However, to the best of our knowledge, this has never been tested in salvaging zones of stasis, and this deficiency inspired the current research.

OPS imaging is a technique based on the optical filtration of polarized light absorbed by hemoglobin (41). This method permits direct in vivo real-time imaging of the capillary network and visualization of the microcirculation in tissues including burned skin (42) and provides qualitative and quantitative information about perfusion because the capillaries are easily visible and red blood cells can be tracked in real time (43,44). This imaging technique has been validated for the measurement of different microcirculatory parameters, in particular FCD,

as a parameter of dermal perfusion. Burn injury causes acute thrombosis and occlusion of the dermal vasculature. A vascular response also occurs in the area bordering the injury site (8). OPS has been demonstrated to be sensitive in detecting damaged and nondamaged tissues (42). We used OPS imaging to measure the microcirculation in the stasis zone in this study. LMWH effectively prevented a decrease in FCD values compared to the saline group, in which FCD values declined after burn injury. The prevention of a decrease in FCD values is a positive parameter of burn wound healing.

Based on histological findings, the increased macrophage infiltration, angiogenesis, and fibroblast proliferation observed in the LMWH group indicate that LMWH had a positive impact on the burn wound healing process in the zone of stasis. Many mediators, such as cytokines and interleukins, are released from the macrophages resulting from fibroblast activation. Proliferation of fibroblast is associated with increased collagen accumulation. We also determined improved angiogenesis in the LMWH group, a process that facilitates burn wound healing. Oremus et al. (37) performed a large series systematic review to assess the evidence for or against using heparin in the treatment of burn injury. Although they determined a general decrease in mortality, improvements in burn wound healing and relief of burn pain, they concluded that most of the studies they reviewed were poorly designed and that there was insufficient evidence to support the use of heparin in the treatment of burn injuries. They also indicated that the increased risk of bleeding should be considered in patients receiving heparin. In agreement with previous clinical and experimental studies (37,45), we think that the use of unfractionated heparin may have beneficial effects on burn wound healing, but may also heighten the risk of bleeding.

Many agents and drug have previously been used to salvage the zone of stasis. Our experimental study is the first to investigate the potential effect of the LMWH enoxaparin on salvaging the zone of stasis after burn trauma. Salvaging this zone following burn trauma has been the subject of many experimental studies testing various different agents, although most of the experimentally promising agents remain to be clinically validated (3–5). From that perspective, enoxaparin is a clinically proven agent for anticoagulation and is of greater potential use in burn injury cases. LMWH may also provide an additional advantage since moderately and severely burned patients are relatively immobile and hemodynamically unstable, and are prone to hypercoagulation and associated risks, including thromboembolism.

In parallel to the great diversity in terms of skin anatomy and histology, there are also significant differences in stages of burn injury development and wound healing among different mammals, including mice, rats, rabbits, pigs, and humans (46). While thrombosis occurs early in rats (8,47), this phenomenon occurs later in humans and pigs (48,49). In the early period in humans and pigs, the vessels in the zone of stasis are plugged with red blood cells, but no thrombosis occurs. This may explain why heparin has proved to be ineffective in human studies (37). Once the framework of burn injury has been established in the inflammatory phase, the subsequent phases are initiated. These differences need to be taken into consideration when evaluating the translational potential of research from animal models, including ours.

In conclusion, our study demonstrates that LMWH helps salvage the zone of stasis in a rat comb burn model. However, whether these results will translate into larger animals and humans remains unclear and will require further testing.

References

1. Jackson DM. The diagnosis of the depth of burning. *Br J Surg* 1953; 40: 588-596.
2. Nisanci M, Eski M, Sahin I, Ilgan S, Isik S. Saving the zone of stasis in burns with activated protein C: an experimental study in rats. *Burns* 2010; 36: 397-402.
3. Firat C, Samdanci E, Erbatır S, Aytėkin AH, Ak M, Turtay MG, Coban YK. β -Glucan treatment prevents progressive burn ischaemia in the zone of stasis and improves burn healing: an experimental study in rats. *Burns* 2013; 39: 105-112.
4. Işık S, Sahin U, Ilgan S, Güler M, Günalp B, Selmanpakoğlu N. Saving the zone of stasis in burns with recombinant tissue-type plasminogen activator (r-tPA): an experimental study in rats. *Burns* 1998; 24: 217-223.
5. Deniz M, Borman H, Seyhan T, Haberal M. An effective antioxidant drug on prevention of the necrosis of zone of stasis: N-acetylcysteine. *Burns* 2013; 39: 320-325.
6. Zakine G, Barbier V, Garcia-Filipe S, Luboinski J, Papy-Garcia D, Chachques JC, Carpentier A, Barritault D. Matrix therapy with RGTA OTR4120 improves healing time and quality in hairless rats with deep second-degree burns. *Plast Reconstr Surg* 2011; 127: 541-550.
7. Yousef MA, Dionigi P. Experimental thromboprophylaxis with low molecular weight heparin after microsurgical revascularization. *J Hand Microsurg* 2015; 7: 256-260.
8. Regas FC, Ehrlich HP. Elucidating the vascular response to burns with a new rat model. *J Trauma* 1992; 32: 557-563.

9. von Dobschuetz E, Biberthaler P, Mussack T, Langer S, Messmer K, Hoffmann T. Noninvasive in vivo assessment of the pancreatic microcirculation: orthogonal polarization spectral imaging. *Pancreas* 2003; 26: 139-143.
10. Olivier WA, Hazen A, Levine JP, Soltanian H, Chung S, Gurtner GC. Reliable assessment of skin flap viability using orthogonal polarization imaging. *Plast Reconstr Surg* 2003; 112: 547-555.
11. Groner W, Winkelman JW, Harris AG, Ince C, Bouma GJ, Messmer K, Nadeau RG. Orthogonal polarization spectral imaging: a new method for study of the microcirculation. *Nat Med* 1999; 5: 1209-1212.
12. King TC, Zimmerman JM. Optimum temperatures for postburn cooling. *Arch Surg* 1965; 91: 656-657.
13. DeCamara DL, Raine T, Robson MC. Ultrastructural aspects of cooled thermal injury. *J Trauma* 1981; 21: 911-919.
14. Robb HJ. Dynamics of the microcirculation during a burn. *Arch Surg* 1967; 94: 776-780.
15. Shupp JW, Nasabzadeh TJ, Rosenthal DS, Jordan MH, Fidler P, Jeng JC. A review of the local pathophysiologic bases of burn wound progression. *J Burn Care Res* 2010; 31: 849-873.
16. Williams WG, Phillips LG. Pathophysiology of the burn wound. In: Herndon DR, editor. *Total Burn Care*, 1st ed. London, UK: W.B. Saunders, 1995.
17. Uygur F, Evinç R, Urhan M, Celikoz B, Haholu A. Salvaging the zone of stasis by simvastatin: an experimental study in rats. *J Burn Care Res* 2009; 30: 872-879.
18. Vetvicka V, Yvin JC. Effects of marine b-1,3-glucan on immune reactions. *Int Immunopharmacol* 2004; 4: 721-730.
19. Toklu HZ, Sener G, Jahovic N, Uslu B, Arbak S, Yegen BC. Beta-glucan protects against burn-induced oxidative organ damage in rats. *Int Immunopharmacol* 2006; 6: 156-169.
20. Knabl JS, Bauer W, Andel H, Schwendenwein I, Dado PF, Mittlböck M, Römer W, Choi MS, Horvat R, Meissl G et al. Progression of burn wound depth by systemical application of a vasoconstrictor: an experimental study with a new rabbit model. *Burns* 1999; 25: 715-721.
21. Baskaran H, Toner M, Yarmush ML, Berthiaume F. Poloxamer-188 improves capillary blood flow and tissue viability in a cutaneous burn wound. *J Surg Res* 2001; 101: 56-61.
22. Papp A, Romppanen E, Lahtinen T, Uusaro A, Harma M, Alhava E. Red blood cell and tissue water content in experimental thermal injury. *Burns* 2005; 31: 1003-1006.
23. Bucky LP, Vedder NB, Hong HZ, Ehrlich HP, Winn RK, Harlan JM, May JW Jr. Reduction of burn injury by inhibiting CD18-mediated leukocyte adherence in rabbits. *Plast Reconstr Surg* 1994; 93: 1473-1480.
24. Cotran RS. The delayed and prolonged vascular leakage in inflammation. An electron microscopic study of the vascular response after thermal injury. *Am J Pathol* 1965; 46: 589-620.
25. Bijsterveld NR, Hettiarachchi R, Peters R, Prins MH, Levi M, Büller HR. Low-molecular weight heparins in venous and arterial thrombotic disease. *Thromb Haemost* 1999; 82: 139-147.
26. Nenci GG, Minciotti A. Low molecular weight heparins for arterial thrombosis. *Vasc Med* 2000; 5: 251-258.
27. Ahmed I, Majeed A, Powell R. Heparin induced thrombocytopenia: diagnosis and management update. *Postgrad Med J* 2007; 83: 575-582.
28. Zor F, Ozturk S, Deveci M, Karacalioglu O, Sengezer M. Saving the zone of stasis: is glutathione effective? *Burns* 2005; 31: 972-976.
29. Vorauer-Uhl K, Fürnschliel E, Wagner A, Ferko B, Katinger H. Reepithelialization of experimental scalds effected by topically applied superoxide dismutase: controlled animal studies. *Wound Repair Regen* 2002; 10: 366-371.
30. Mahajan AL, Tenorio X, Pepper MS, Baetens D, Mondanton D, Schlaudraff KU, Pittet B. Progressive tissue injury in burns is reduced by rNAPc2. *Burns* 2006; 32: 957-963.
31. Robson MC, Kucan JO, Paik KI, Eriksson E. Prevention of dermal ischemia after thermal injury. *Arch Surg* 1978; 113: 621-625.
32. Barrow RE, Ramirez RJ, Zhang XJ. Ibuprofen modulates tissue perfusion in partial-thickness burns. *Burns* 2000; 26: 341-346.
33. Jeffries MK, Vance ML. Growth hormone and cortisol secretion in patients with burn injury. *J Burn Care Rehabil* 1992; 13: 391-395.
34. Kamel AH, Ahmed YAA, Thabet NM, EI-Haish MK. Modulation by aspirin of platelet function in burn patients: clinical and laboratory assessment. *Ann Burns Fire Disasters* 1999; 3: 99-102.
35. Öksüz S, Ülkür E, Öncül O, Köse GT, Küçükodaci Z, Urhan M. The effect of subcutaneous mesenchymal stem cell injection on stasis zone and apoptosis in an experimental burn model. *Plast Reconstr Surg* 2013; 131: 463-471.
36. Rosique MJ, Rosique RG, Faria FM, Oliveira CC, Farina JA Jr, Évora PRB. Methylene blue reduces progression of burn and increases skin survival in an experimental rat model. *Burns* 2017; 43: 1702-1708.
37. Oremus M, Hanson MD, Whitlock R, Young E, Archer C, Dal Cin A, Gupta A, Raina P. A systematic review of heparin to treat burn injury. *J Burn Care Res* 2007; 28: 794-804.
38. Young E. The anti-inflammatory effects of heparin and related compounds. *Thromb Res* 2008; 122: 743-752.
39. Horton JW. Free radicals and lipid peroxidation mediated injury in burn trauma: the role of antioxidant therapy. *Toxicology* 2003; 189: 75-88.
40. Lakshmi RT, Priyanka T, Meenakshi J, Mathangi KR, Jeyaraman V, Babu M. Low molecular weight heparin mediated regulation of nitric oxide synthase during burn wound healing. *Ann Burns Fire Disasters* 2011; 24: 24-29.
41. Langer S, Hatz R, Harris AG, Hernandez-Richter T, Maiwald G, Messmer K. Assessing the microcirculation in a burn wound by use of OPS imaging. *Eur J Med Res* 2001; 28: 231-234.

42. Milner SM, Bhat S, Gulati S, Gherardini G, Smith CE, Bick RJ. Observations on the microcirculation of the human burn wound using orthogonal polarization spectral imaging. *Burns* 2005; 31: 316-319.
43. Goertz O, Ring A, Köhlinger A, Daigeler A, Andree C, Steinau HU, Langer S. Orthogonal polarization spectral imaging: a tool for assessing burn depths? *Ann Plast Surg* 2010; 64: 217-221.
44. Uraloğlu M, Livaoğlu M, Agdoğan Ö, Mungan S, Alhan E, Karaçal N. An evaluation of five different dressing materials on split-thickness skin graft donor site and full-thickness cutaneous wounds: an experimental study. *Int Wound J* 2014; 11: 85-92.
45. Saliba MJ Jr. Heparin in the treatment of burns: a review. *Burns* 2001; 27: 349-358.
46. Abdullahi A, Amini-Nik S, Jeschke MG. Animal models in burn research. *Cell Mol Life Sci* 2014; 71: 3241-3255.
47. Ehrlich HP. Promotion of vascular patency in dermal burns with ibuprofen. *Am J Med* 1984; 13: 107-113.
48. Moritz AR. Studies of thermal injury: the pathology and pathogenesis of cutaneous burns. An experimental study. *Am J Pathol* 1947; 23: 915-941.
49. Sevitt S. Local blood flow changes in experimental burns. *J Pathol Bacteriol* 1949; 61: 427.