

Sadık AKŞİT¹
Meral TÜRKER¹
Işın YAPRAK¹
Suat ÇAĞLAYAN²
Coşkun DORAK¹
Savaş KANSOY¹

A Case of Trisomy 8 Mosaicism

¹Department of Pediatrics,
SSK Tepecik Teaching Hospital, Yenışehir,
²Ege University Faculty of Medicine, Izmir-Turkey

Received: July 1, 1996

Introduction

Complete trisomy 8 is usually lethal (1). Trisomy 8 mosaicism may vary from a phenotypically normal individual to a severe malformation syndrome. The phenotype includes an abnormally shaped skull, reduced joint mobility, various vertebral and costal anomalies, strabismus, camptodactyly of second through fifth fingers and toes, and deep palmar and plantar creases (1-4). Plantar creases are highly characteristic of the syndrome. Agenesis of the corpus callosum may be found in some cases. Cardiac and renal anomalies may occur. Mental retardation is frequent and varies from mild to severe, although some have normal intelligence. Trisomy 8 is a rare syndrome and, to our knowledge, 35 cases have been reported in the literature and no trisomy 8 case has been reported from our country, up to now. We, therefore, present here a case of trisomy 8 mosaicism and review the literature.

Case Presentation

The patient was the product of first pregnancy of mother. The patient's mother and father were healthy and they were 20 and 28 years old, respectively. The mothers of the parents were sisters. The mother did not use any medication or was not exposed to radiation during the pregnancy.

Ventriculomegaly in the baby had been detected on routine ultrasound examination of the mother at the 28th weeks of gestation. Thereafter, cordocentesis was performed, and karyotype showed trisomy 8 mosaicism. He was born at 34 weeks of gestation with Apgar scores of 7/8/8. The birth weight was 2000 g (25th percentile), the length was 44 cm (25th percentile) and the head circumference was 33 cm (75th percentile). Heart rate was 142 per minute and res-

piratory rate was 70 per minute. On examination, he had plethoric appearance and there were grunting, subcostal and intercostal retractions. He had a low posterior hairline, coarse nose with prominent nares, low-set and cupped ears with thick helices, micrognathia, high palate, everted lower lips, pectus excavatum, deep palmar and plantar skin furrows, and camptodactyly of second through fifth fingers (Figure 1,2). On auscultation, a grade II systolic murmur was detected at the mesocardium and crepitations were heard at the both hemithorax. Because of the respiratory distress, the patient was transferred to the newborn unit. The hematocrit was 55 percent; the white cell count was 7900/mm³ with a normal differential; platelet count was 162.000/mm³. Blood biochemistry values were in the normal limits. On chest x-ray, the aeration of the lungs was decreased. Oxygen therapy was given to the patient. At the second day, the icterus was observed and, at the fourth day indirect bilirubin rose to 15 mg/dL. Blood incompatibility was not present between the mother and the patient. Direct Coomb's test was negative. No hemolysis was observed on blood smear. Hyperebilirubinemia was successfully managed with phototherapy. Respiratory distress disappeared after the sixth day. Membranous VSD with diameter of 2 cm was detected on echocardiogram. Abdominal ultrasonography was normal. Direct x-ray studies of the vertebrae showed a fusion defect at T6. Cranial CT and MRI demonstrated agenesis of the corpus callosum and the enlargement of the occipital horns of the lateral ventricles (colpocephaly) (Figure 3). The fundus examination of the eye was normal. TORCH titers and bacterial cultures were negative. Routine G-banding chromosomal studies from the patient were performed and the diagnosis of trisomy 8 mosaicism

	Literature	Our Patient	Table	Comparison of Trisomy 8 Manifestations With Those of Our Patient.
Short stature	+	-		
Prominent forehead	+	+		
Low posterior hairline	+	+		
Plump nose with broad base	+	+		
Prominent nares	+	+		
Low-set and dysplastic ears	+	+		
Deep-set eyes	+	+		
Strabismus	+	-		
Everted lower lip	+	+		
High palate	+	+		
Cleft soft palate	+	-		
Micrognathia	+	+		
Camptodactyly of the fingers	+	+		
Deep palmar and plantar skin furrows	+	+		
Pectus excavatum	-	+		
Widely spaced nipples	+	+		
Vertebral anomalies	+	+		
Costal anomalies	+	-		
Congenital heart disease	+	+		
Urinary tract anomalies	+	-		
Agenesis of the corpus callosum	+	+		

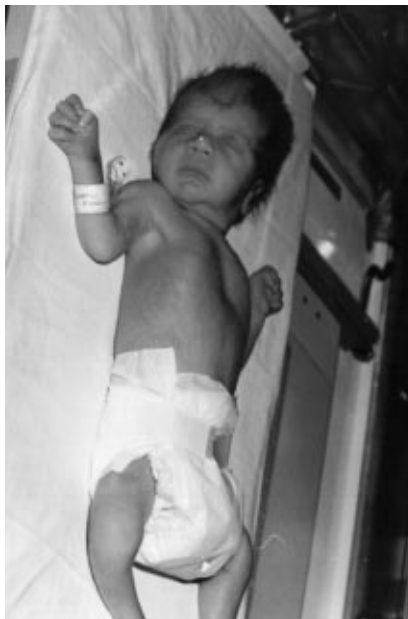

Figure 1. The phenotype of the patient. Note micrognathia, coarse and upturned nose with broad base, low-set ears, pectus excavatum, widely spaced nipples and camptodactyly of the fingers.

were confirmed; Of the 100 metaphases analyzed, 56 metaphases showed 46,XY and 44 metaphases 47,XY,+8. The mother had a normal 46,XX chromosome constitution.

Comment

Our case illustrated a number of characteristic clinical features associated with trisomy 8 syndrome patients which have been previously reported in the literature (Table). In addition, there were pectus excavatum and colpocephaly in our case as the difference from the literature. Deep plantar creases are the hallmark of this syndrome. The natural history in trisomy 8 mosaicism is largely dependent on the severity of mental deficiency, which is probably related to the proportion of trisomic versus normal cells. The majority of patients die during the early neonatal period.

Trisomy 8 cell lines have also been found in the bone marrow of the patients with various hematological disorders, notably in acute myeloid leukemia and myelodysplasia (5-8). These cell lines were restricted

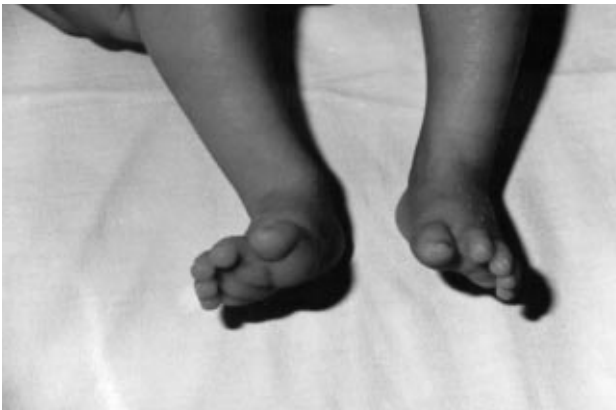

Figure 2. Deep plantar furrows in our patient as the hallmark of trisomy 8 syndrome.

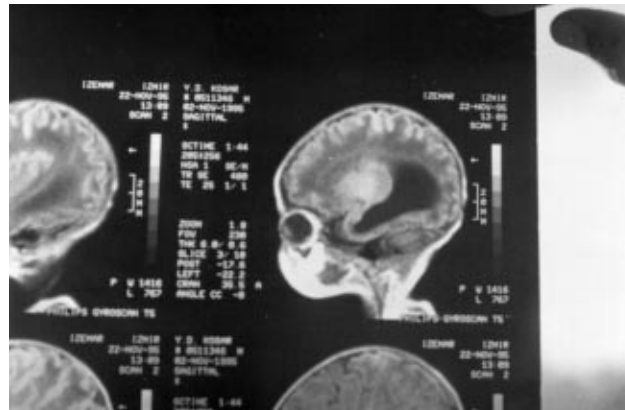


Figure 3. Cranial MRI findings of our patient. Note the enlargement of the occipital horns of lateral ventricles (colpocephaly) and the agenesis of corpus callosum.

to the malignant cells, and disappeared from bone marrow during remission of these hematological disorders.

In conclusion, in the children with deep plantar

and palmar skin furrows, camptodactyly of the fingers, mental retardation and characteristic cranio-facial anomalies cited above, trisomy 8 syndrome must be considered and chromosomal studies should be performed.

References

1. Gilbert-Barnes GF, Opitz JM. Chromosomal abnormalities. In: Wigglesworth JS, Singer DB (eds). *Textbook of Fetal and Perinatal Pathology*. Boston: Blackwell Scientific Publ., 1991, pp: 339-79.
2. Jones KL. *Smith's Recognizable Patterns of Human Malformation*. Philadelphia: WB Saunders Comp., 1988, pp:26-9.
3. Hirschorn K. Clinical abnormalities of the autosomes. In: Behrman RE, Kliegman RM, Waldo EN, Vaughan VC, (eds). *Nelson Textbook of Pediatrics*. Philadelphia: WB Saunders Comp., 1992, pp: 286-7.
4. Engelen JJ, de Die-Smulders CE, Sijstermans JM, Meers LE, Albrechts JS, Hamers AJ. Familial partial trisomy 8p without dysmorphic features and only mild mental retardation. *J Med Genet* 32: 792-5, 1995.
5. Niss R, Passarge E. Trisomy 8 restricted to cultured skin fibroblasts. *J Med Genet* 13: 229, 1976.
6. Jonasson J, Gahrton G, Lindsten J.